

Pathogenicity of viral nervous necrosis virus for Guppy fish, *Poecilia reticulata*

Nazari, A.^{1*}; Hassan, M. D.²; Bovo, G.³; Zorriehzahra, M. J.⁴; Azmi, T. I.²
and Arshad, S.S.²

Received: August 2012

Accepted: September 2012

Abstract

The pathogenicity of a Nervous Necrosis Virus isolate obtained from naturally infected Golden grey mullet (*Liza auratus*) suffering serious mortalities in Iranian coastline water of the Caspian Sea was investigated for first time. An experimental infection has been performed using three groups, two experimental groups and one control group of Guppy (*Poecilia reticulata*) with mean weight 0.47 ± 0.09 g, at temperature 25°C. The infectious dosage (50 ml) with $TCID_{50}/ml = 10^{4.25}$ for 2 hours in group 1 and 4 hours in group 2 developed the disease with immersion method. Clear clinical signs associated with significant mortality were observed since 15 dpi. Cumulative mortalities rose to 100% at 30 dpi. While in the control group no mortality was recorded.

Virus was re-isolated on SSN-1 cell line that showing typical CPE developed after inoculation with tissues filtrate from dead fish. Histopathological examination of exposed fish, showed clear vacuolization in the granular layer of the retina and cerebellum. TEM micrographs revealed intracytoplasmic vacuoles in the retina of infected Guppy. IHC revealed the presence of viral antigens in the brain and retina.

These results confirmed the pathogenicity of the NNV isolate obtained from Golden grey mullet suffering high mortality with regard to suggest that the same agent isolated from golden grey mullet is very likely the cause of the mortality observed in the same species.

Keywords: VNN, Golden grey mullet, Caspian Sea

1-Department of Biology, Falavarjan Branch, Isalmic Azad University, Esfahan, Iran.

2-Faculty of Veterinary Medicine, University of Putra. No. 43400 Serdang, Selangor, Malaysia.

3-Fish Pathology Department ,OIE Reference Lab for Encephalopathy and Retinopathy, Institute Zooprofilattico Sperimentale delle Venezie, Viale dell'Università, 10- 35020 Legnaro, Padova- Italy.

4-Iranian Fisheries Research Organization, P.O.Box: 13185-116, Tehran, Iran

*Corresponded author's email: alireza_15869@yahoo.com

Introduction

Betanodaviruses are the etiological agents of the disease known as viral nervous necrosis or viral encephalopathy and retinopathy. Piscine nodaviruses belong to the genus Betanodavirus, within the family Nodaviridae (Schneemann et al., 2005). Betanodaviruses are small (25-30 nm in diameter) RNA viruses with an icosahedral morphology consisting of a single coat protein and a bisegmented protein RNA1 and RNA2 (Iwamoto et al., 1999). The disease may affect more than forty fish species worldwide particular during the larval and juvenile stage. Adult fish may also be affected in some species (Nakai, 2007). Affected fish exhibit neurological disorders such as abnormal swimming behavior, loss of appetite, lethargy, enlargement of swim bladder and darkness in some species of fish (Bovo and Florio, 2008). Histopathologically, the disease is characterized by vacuolation of the grey matter of the brain, spinal cord and the granular layers of the retina (Munday et al., 2002).

Grey mullet is an important commercial fish species in northern Iran. Its capture rate declined from 6446 MT in 2002 to 2780 MT in 2009. Epizootic affecting Golden Grey mullet in Iranian coastline water of Caspian Sea were recognized since 2004 (Zorriehzahra et al., 2005). Moribund fish revealed abnormal swimming behavior, belly up at rest, bilateral exophthalmia, hemorrhage in the skin. Histopathological lesions consisted of vacuolation in the CNS and retina. By RT-PCR, VNN was detected in wild fish living in the Caspian Sea (Zorriehzahra et al., 2005).

The Guppy was selected as a VNN susceptible species because of the difficulties to adapt grey mullet to the aquarium environment. In the present study, susceptibility of Guppy to piscine nodavirus for confirmation of isolated VNN viral particles from Grey mullet by experimentally infection was explained.

Materials and methods

Ninety adult male and female guppies with mean weight 0.47 ± 0.09 g were obtained from Inland Water Aquaculture Research Center in Bandar Anzali affiliated to IFRO. The fishes were acclimatized in clean aquaria for two weeks before the challenge trials and fed with commercial ornamental fish pellet twice daily. The temperature was maintained at 25°C and the aquaria were aerated. During the two weeks, mortality wasn't observed.

The challenge virus used in this study was obtained from SSN-1 cell culture inoculated with brain and eye homogenized tissues originating from naturally infected Grey mullet. The cell monolayer with marked CPE was scraped from the flasks, and fresh EMEM media (SIGMA) was added. Then, the scraped cells and media were dispensed into centrifuge tube and centrifuged at 1500 rpm, for 10 min at 4°C. The cell pellet was collected and resuspended in EMEM medium. This new supernatant was freeze-thawed twice at -70°C to break the cells and permit the virus release. The supernatant was centrifuged again at 4000 rpm for 20 min at 4°C to separate the cell associated viral particles from the cell debris. Titration of the virus was performed in SSN-1

cells in 96 well-plates and the $TCID_{50}/mL^{-1}$ calculated according to Reed and Muench (1938).

Three experimental groups each consisting of 30 specimens was established, i.e. test group 1, test group 2 and control group. Fish were immersed in 6L of water added with 50ml of infected supernatant ($TCID_{50}/ml = 10^{4.25}$) respectively for 2 hours in test group 1 and 4 hours in test group 2. The control group was immersed for 4 hours in 6 L of water containing 50ml cell culture media (EMEM). All the aquaria were aerated accordingly.

After the challenge, fish were transferred into 60 L aquaria and fed twice daily. The temperature was maintained at 25°C. Clinical signs and mortalities were recorded for a period of 30 days. After 15 dpi when clinical signs and mortality appeared, moribund fish were sampled and submitted to laboratory investigations. The whole head were fixed in Bouin fixative for histopathological examination and parallel samples were prepared for virus isolation and fixed in 4% glutaraldehyde for TEM.

Samples were fixed in aqueous Bouin's fluid processed by an automatic tissue processor in Pathology Lab, Diagnostic Center of Iranian Veterinary Organization, Pajouhesh Blvd, Karaj, Iran and embedded in paraffin wax. Five μm sections were deparaffinized, rehydrated and then stained with H&E for histopathological examination. Some tissue sections were retained for Immunohistochemical examination.

Brain and eyes tissues were pooled and homogenized in EMEM supplemented with 200 IU mL^{-1} penicillin (Gibco), 200 $\mu g mL^{-1}$ streptomycin (Gibco), 20 $\mu g mL^{-1}$ gentamycin (Gibco) and 2 $\mu g mL^{-1}$ fungizone (Gibco) in a proportion of 1:10 sample weight, volume. Homogenized samples were incubated overnight at 4°C, centrifuged and the resultant supernatants kept at 4°C until used. The virus-containing supernatants were diluted 1:100 and inoculated in SSN-1 cells in flask. After 7 days of incubation at 25°C, CPE was observed.

Five μm paraffin-embedded tissue sections were de-waxed and rehydrated in two xylene baths and an ethanol series (100, 70), and rinsed in distilled water. The sections were then treated with H₂O₂ in methanol. Non-specific antibody binding sites were blocked with normal goat serum. Then, the primary antibody (Anti RGNNV Noda monoclonal Ab, AQUATIC DIAGNOSTIC LTD, UK) was added and incubated at room temperature for 60 min. After rinsing in TBS (5 min), the secondary antibody (goat anti- mouse IgG biotin conjugate, SIGMA ALDRICH CO, USA) was added and incubated at 22 °C for 30 min. After washing, 3, 3'-diaminobenzidine (DAB) was added, and the reaction was allowed to develop for 5 min. The sections were washed in distilled water, counter stained with Hematoxylin and mounted for light microscopy examination.

Brain and eye were fixed in 4% glutaraldehyde and then post-fixed in 1% osmium tetroxide. Ultra thin sections were stained with uranyl acetate/lead citrate and

examined with a PHILIPS-400 electron microscope.

Results

In the test group 2, first moribund fish were appeared from 15 to 16 dpi, while in the test group 1 moribund fish were appeared from 17dpi. Infected fish exhibited abnormal swimming behavior, suggesting that central nervous system was affected. Moribund fish rotated on long axis, swimming up and down, and they came to the surface with a curved body and belly up at rest. Fish showed abnormal body posture, enlarged abdomen and bilateral exophthalmia. Hemorrhagic petechiae on the skin were also observed. No clinical signs were observed in the control group.

The cumulative mortality curves of different experimental groups are shown in Fig 1. The cumulative mortality in the groups 1 and 2 rose to 100% during 30 days post

infection. In the group 1, the cumulative mortality was significantly higher from day 17 onward ($p < .05$). The time from infection to 50% cumulative mortality (LT_{50}) for first group was 24d reaching 100% mortality 6 day later. While, in the group 2, the cumulative mortality was significantly higher from day 15 onward ($p < .05$) and the time from infection to 50% cumulative mortality (LT_{50}) for this group was 20d reaching 100% mortality 10 day later. No mortality was in control group after 30days post challenged.

The cumulative mortality differences between group 1 and 2 were significant ($p < .05$).

Marked CPE was visualized in SSN-1 cell culture after three times of 10-day blind passages. Vacuolated cells reached a complete CPE with final cell detachment from the monolayer (Fig. 2).

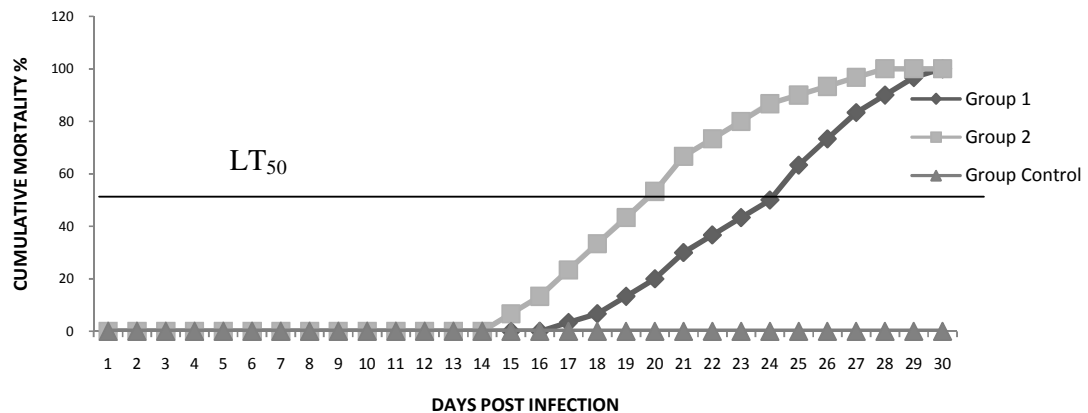


Figure 1: Cumulative mortality curves of experimental groups of challenged trial on Guppy. The group 1 was challenged with 50ml of SSN-1 cell supernatant infected by brain and eye homogenate of diseased grey mullet for 2hours while group 2 was challenged with 50ml of SSN-1 cell supernatant infected by brain and eye homogenate of diseased grey mullet for 4hours. The control group was challenged with culture media (EMEM) for 4 hours.

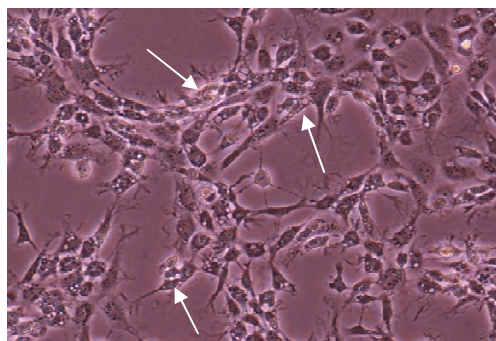


Figure 2: Cell culture isolation of NNV from infected brain tissue of Guppy. Marked CPE (arrows) appeared in SSN-1 cell culture after 5 days of 3rd passage. Unstained. X 200.

The eyes and brains of infected Guppy showed vacuolated cells. In the brain, vacuoles were seen in the stratum griseum ventricular layer and stratum album central layer of mesencephalon region, as well as in the septal area, ventral and dorsal olfactory area in olfactory bulb of telencephalon region (Fig. 3).

In the eye, the ganglion cell layer of the retina was vacuolated (Fig. 4). The results exhibited a very light reaction between MAb and viral antigens in the brain tissue (Fig. 5). The eye samples revealed intracytoplasmic vacuoles in the retina cells (Fig. 6).

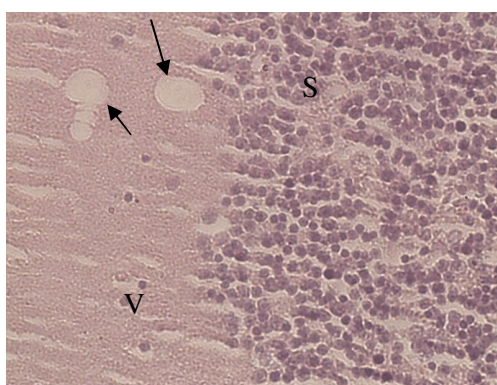


Figure 3: Vacuolation in the olfactory bulb of telencephalon region in brain tissue of infected Guppy at 15 dpi (arrows). S: Septal area. V: Ventral olfactory area. H&E. X 400.

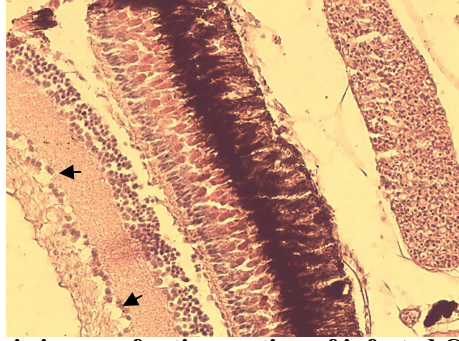


Figure 4: Light microscopic image of retina section of infected Guppy at 15 dpi. Vacuolation was seen in ganglion cell layer (arrows). H&E. X 400.

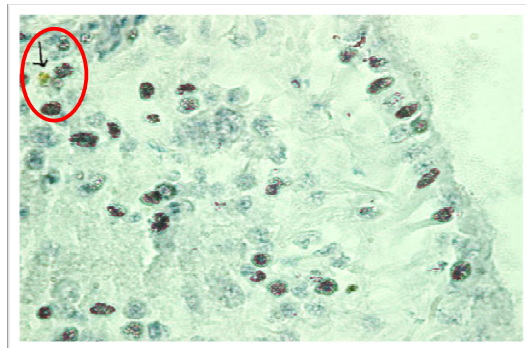


Figure 5: Brain tissue section from test group1 Guppy at 15 dpi stained with IHC dye. Golden brown color (arrow) indicated light reaction between MAb and inter-cellular viral antigens. X 1000.

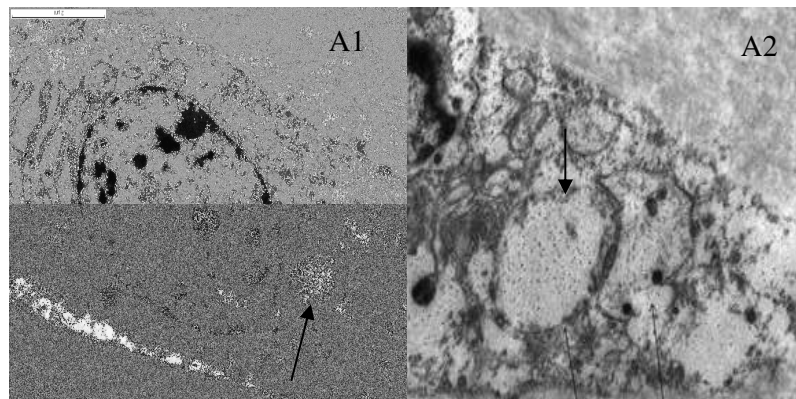


Figure 6: VNN bathed challenge Guppy, *Poecilia reticulata* 15 dpi. A1 & A2. Electron micrograph showing the vacuoles in the cytoplasm of the retina cell, (arrows). Scale bar = 0.2 μm .

Discussion

The experimental infection in Guppy was performed to evaluate the VNN strain isolated from naturally infected Grey mullet. In the current study, clinical signs, typical CPE and changes in the retina and brine were observed in infected Guppy. In the present study, significant differences in viral pathogenicity were observed between 2 groups when the times of challenge were varied.

In the current study, the sequence of mortalities indicated the similarity of mortalities in other fish species affected with NNV (Aranguren et al., 2002). In naturally infected Guppy listlessness, emaciation and mortality were observed (Hegde et al., 2003). In other species, although the highest mortalities were observed in larvae and juveniles (Yoshikoshi and Inoue, 1990; Glazebrook et al., 1990; Breuil et al., 1991; Mori et al., 1991; Renault et al., 1991), larger fish showed also developed clinical signs and suffered from mortalities (Fukuda et al., 1996; Skliris and Richards, 1999).

The clinical signs observed in this study were slightly different from the experimental infection reported in a previous investigation (Hegde et al., 2003). In that previous study, 0.1g Guppy was challenged with NNV isolated from Guppy and *Epinephelus tauvina* and mortality lasted for 15 days, while, in our trial, the weight of the challenged Guppy were 0.47 ± 0 and they have been exposed to a NNV isolated from Golden grey mullet and mortality

lasted for 30 days. In both studies up to 100% mortality were observed, but in Hegde's report, absence of clinical signs was detected while in our study typical signs were associated to mortality.

In experimental infections, clinical signs may vary according to differences on the time of transmission, age of fish and route of infection (Aranguren et al., 2002). Other observations indicated that pattern of pathogenicity may differ when different fish species and virus strains or isolate are compared (Mladineo, 2003).

Furthermore, immature immune system could also lead to higher mortality in short period in the fish larvae and juvenile as compared to lower mortality but longer time of death in adult fish (Aranguren et al., 2002). On the other hand, the viral exposure dose plays an important role in the pathogenicity of the infection. The researchers indicated that the incubation period before appearance of clinical signs following artificial infection may vary according to species and depends on dose of virus inoculums (Grotmol et al., 1999).

Histopathology investigations revealed vacuolation changes in the eye and brain. Similar signs were reported in naturally infected Grey mullet, which was the source of the virus in this study (Zorriehzahra et al., 2005) as well as in other marine and freshwater fish species (Nguyen et al., 1996; Peducasse et al., 1999). Likewise, this

observation was similar to first report of natural infection of Guppy larvae to VNN (Hagde et al., 2003).

The observed signs, in particular the erratic swimming behavior, could be referred to cell vacuolation and necrotic changes caused by the virus in the brain. As other studies noted, the brain and eye were main target tissues for NNV in most of infected fish species. In Figure 3, small vacuoles were seen in the stratum griseum periventriculare of optic tectum in mesencephalon. Vacuolated cells in this area have been reported in sevenband grouper, *Epinephelus septemfasciatus* previously (Tanaka et al., 2004). The vacuolated cells shown in Fig. 3 were located in the ventral olfactory area and septal area of cerebral hemisphere or olfactory bulb of telencephalon. Both areas contained the mass of nerve cells which transmitted olfactory impulses to other centers (Hibiya, 1982). The many small nerve cells in olfactory bulb form a granule cell layer (Tanaka et al., 2004). The telencephalon on the other hand was responsible for olfaction, memory, reproductive and feeding behavior (Roberts, 2000). The abnormal swimming observed in experimentally infected Guppy could be associated with vacuolar changes and necrosis of brain cells in the above mentioned area. The retina showed vacuolation in inner ganglion cell layer. Similar necrotized area in NNV infection was described by Tanaka et al. (2004).

TEM micrographs from retina layer in the eye of infected Guppy revealed the presence of intracytoplasmic vacuolation. Intracytoplasmic

vacuolation in the retina was also reported by Tanaka et al. (2004) with EM micrographs previously.

The IHC performed both in brain and eyes sections showed very few positive foci and light reaction between specific MAb and viral antigens scattered in the target tissues. This result could be due to a low sensitivity of Mabs employed in our test against the GMNNV strain or low density of NNV invasive particles in brain. This hypothesis earlier mentioned by Zorriehzahra et al. (2005) could be supported by the existence pathogenicity of viral strains obtained from Golden grey mullet characterized by different pathogenicity. Low vacuolation in the retina presumably indicated that optic nerves and retina were infected after brain infection as described by Mladineo (2003) using Immunolabeling. In the current study, horizontal transmission was employed for pathogenicity of NNV isolated from Golden grey mullet to Guppy fish. Thus, it could concluded that isolated virus from Golden grey mullet in the current study is similar to isolate virus by Zorriehzahra et al. (2005).

References

- Aranguren, R., Tafalla, C., Novoa, B. and Figueras, A., 2002. Experimental transmission of encephalopathy and retinopathy induced by nodavirus to sea bream *Sparus aurata* L., using different infection models. *Journal of Fish Diseases*, 25, 317-324.
- Bovo, G. and Florio, D., 2008. Viral diseases of cultured marine fish. In *Fish Diseases*, vol. 1, Eiras, J.C., H. Segner, T. Wahli, and B. G.

- Kapoor, (Eds.), Science Publishers, Enfield, NH: 186-230.
- Breuil, G., Bonami, J. R., Pepin, J. F. and Pichot, Y., 1991.** Viral infection (piconalike virus) associated with mass mortalities in hatchery-reared sea-bass (*dicentrarchus labrax*) larvae and juveniles. *Aquaculture*, 97, 109-116.
- Chi, S. C., Shieh, J. R. and Lin, S. J., 2003.** Genetic and antigenic analysis of betanodaviruses isolated from aquatic organisms in Taiwan. *Disease of Aquatic Organisms*, 55, 221-228.
- Fukuda, Y., Neuyen, H. D., Furuhashi, M., and Nakai, T. 1996.** Mass mortality of cultured sevenband grouper, *epinephelus septemfasciatus*, associated with viral nervous necrosis. *Fish Pathology*, 31, 165-170.
- Glazebrook, J. S., Heaman, M. P., and de Beer, S. W. 1990.** Piconalike viral particles associated with mass mortalities in larval barramundi, *latipes calcarifer* bloch. *Journal of Fish Diseases*, 13, 245-249.
- Grotmol, S., Bergh, O., and Totland, G. K. 1999.** Transmission of viral encephalopathy and retinopathy (VER) to yolk-sac larvae of the Atlantic halibut *Hippoglossus hippoglossus*: occurrence of nodavirus in various organs and a possible route of infection. *Diseases of Aquatic Organisms*, 39, 95-106.
- Hegde, A., Teh, H. C. Lam, T. J. and Sin, Y. M., 2003.** Nodavirus infection in freshwater ornamental fish, Guppy, *Poecilia reticulata*-comparative characterization and pathogenicity studies. *Archives of Virology*, 148, 575-586.
- Hibiya, T., 1982.** An atlas of fish histology. Normal and pathological features. Tokyo, Kosonsha Ltd, 147P.
- Húsgarð, S., Grotmol, S., Hjeltnes, B. K., Rodseth, O. M. and Biering, E., 2001.** Immune response to a recombinant capsid protein of striped jack nervous necrosis virus (SJNNV) in turbot *scophthalmus maximus* and Atlantic halibut *hippoglossus hippoglossus*, and evolution of a vaccine against SJNNV. *Diseases of Aquatic Organisms*, 45, 33-44.
- Iwamoto, T., Mori, K., Arimoto, M. and Nakai, T., 1999.** High permissivity of the fish cell line SSN-1 for piscine nodaviruses. *Diseases of Aquatic Organisms*, 39, 37-47.
- Mladineo, I., 2003.** The immunohistochemical study of nodavirus changes in larval, juvenile and adult sea bass tissue. *Journal of Applied Ichthyology*, 19, 366-370.
- Mori, K., Nakai, T., Negahara, M., Muroga, K., Mckuchi, T., and Kanno, T. 1991.** A viral disease in hatchery-reared larvae and juveniles of redspotted grouper. *Fish Pathology*, 26, 209-210.
- Munday, B. L., Kwang, J. and Moody, N., 2002.** Betanodavirus infection of teleost fish: A review. *Journal of Fish Diseases*, 25, 127-142.
- Nakai, T., 2007.** Viral Nervous Necrosis (VNN): Global status of outbreaks, diagnosis, research and surveillance. SEAFDEC International Workshop on Emerging Fish Diseases in Asia. Bangkok, Thailand, SEAFDEC.
- Nguyen, H. D., Nakai, T. and Muroga, K., 1996.** Progression of striped jack nervous necrosis virus (SJNNV) in adult striped jack *pseudocaranx dentex* larvae. *Diseases of Aquatic Organisms*, 24, 99-105.

- Peducasse, S., Castric, R., Thiery, R., Jeffroy, J., Le ven, A. and Baudin-Laurencin, F., 1999.** Comparative studies of viral encephalopathy and retinopathy in juvenile sea bass *American Journal of Hygiene*, 27, 493-497.
- Renault, T., Haffner, P. H., Baudin, L.F., Breuil, G. and Bonami, J.R., 1991.** Mass mortalities in hatchery-reared sea bass *Lates calcarifer* larvae associated with the presence in the brain and retina of virus-like particles. *Bull Eur Ass Fish Pathol*, 11, 68-73.
- Roberts, R., 2000.** Fish pathology (3 Ed). London, W.B.Saunders, 472P.
- Schneemann A., Ball L. A., Delsert C., Johnson J.E. Nishizawa T.,** Family Nodaviridae. In Virus Taxonomy. 8th Report ICTV. Edited by: Fauquet CM, Mayo MA, Maniloff J, Desselberger U, Ball LA. *Elsevier Academic Press, San Diego, CA*, 2005, 865-872.1
- Skliris, G.P. and Richards, R. H., 1999.** Induction of nodavirus disease in seabass *Dicentrarchus labrax*, using different infection models. *Virus Research*, 63, 85-93.
- Tanaka, A., Aori, H. and Nakai, T., 1998.** Pathogenicity of the nodavirus detected from *Dicentrarchus labrex* infected in different ways. *Disease of Aquatic Organisms*, 36, 11-20.
- Reed, L.L. and Munch, H., 1938.** A simple method of estimating fifty percent endpoints. diseased sevenband grouper *Epinephelus septemfasciatus*. *Fish Pathology*, 33, 31-36.
- Tanaka, S., Takagi, M. and Miyazaki, T., 2004.** Histopathological studies on viral nervous necrosis of sevenband grouper, *Eepinephelus septemfasciatus thunberg*, at the grow-out stage. *Journal of Fish Diseases*, 27, 385-399.
- Yoshikoshi, K. and Inoue, K., 1990.** Viral nervous necrosis in hatchery- reared larvae and juveniles of Japanese parrotfish *Oplegnathus fasciatus* (Temminck & Schlegel). *Journal of Fish Diseases*, 13, 69-77.
- Zorriehzahra, M. J., Nakai, T., Sharifpour, I., Kaw gomez, D., Chi, S.C. and Soltani, M., 2005.** Mortality of wild Golden grey mullet *Liza auratus* in Iranian waters of the Caspian Sea associated with viral nervous necrosis-like agent. *Iranian Journal of Fisheries Science*, 4(2), 43-58.