

**Detection and identification of white spot syndrome virus (WSSV) and infectious hypodermal and hematopoietic necrosis virus (IHHNV) of *Litopenaus vannamei* from Bushehr and Sistan and Baloochestan provinces, Iran, during 2009-2010**

**Pazir M. K.<sup>1,3\*</sup>; Afsharnasab M.<sup>2</sup>; Jalali Jafari B.<sup>1</sup>; Sharifpour I.<sup>2</sup>; Motalebi A. A.<sup>2</sup>; Dashtiannasab A.<sup>3</sup>**

Received: September 2010

Accepted: August 2011

**Abstract**

The first time the white spot disease (WSD) and IHHNV were reported in Iran was in 2004 and 2008, respectively in Bushehr Province. In Sistan and Baloochestan province only the WSD was reported in 2008. The aim of this study was detecting these two viral diseases in these provinces, during December 2009 to April 2010. A total of 364 samples were collected according to suspected gross signs from hatcheries and shrimp farms in Bushehr and Sistan and Blochestan provinces (I.R. Iran) respectively, including larvae (72, 43 samples), post larvae (48, 37 samples), juveniles (57, 32 samples), sub adults (39, 22 samples) and broodstock (29, 13 samples) of *Litopenaus vannamei*. WSD was detected from juveniles (23 samples), sub adults (14 samples), and broodstock (14 samples), and IHHNV was also detected from juveniles (16 samples), sub adults (9 samples) and broodstock (5 samples) based on gross signs, PCR and histopathological changes from Bushehr province but from Sistan and Blochestan province only WSD was detected from juveniles (26 samples), sub adults (18 samples) and broodstock (7 samples). Histopathological observations of WSSV showed basophilic Cowdry type A inclusion bodies in all tissues such as gills, haematopoietic tissue, cuticle epithelium, lymphoid organ and connective tissue. However histologically, the hepatopancreas tissue showed vacuolization of B cells, without inclusion bodies, but histopathological changes caused by IHHNV including eosinophilic Cowdry type A inclusion bodies which were ectodermal, mesodermal and rarely endodermal.

**Keyword:** WSSV, IHHNV, *L. vannamei*, Bushehr province, Sistan and Blochestan province, Iran

1- Faculty of Veterinary, Science and Research Branch, Islamic Azad University, P.O. Box: 14515/775 and 14155/4933, Tehran, Iran

2- Iranian Fisheries Research Organization, P.O.Box:14155-6116, Tehran, Iran

3- Iran Shrimp Research Center, P.O. Box 1374, Bushehr, Iran

\*Corresponding Author s email: dr\_pazir@yahoo.com

## Introduction

Shrimp farms have developed during the past twenty years. In 2008, the production of shrimp in the world was reported 3, 281, 253 metric tons (Shatz, 2008; Kakoolaki et al., 2010) and the portion of the Pacific white shrimp (*Litopenaeus vannamei*) was 90 percent (Shatz, 2008). *L. vannamei* is one of the most important species in the shrimp industry. Shrimp pathogens (especially virus) have been spread through shrimp aquaculture industries as well (Lightner, 1999a).

*Baculovirus penaei* was the first virus in *Penaeus duorarum* which has been reported from the Gulf of Mexico (Couch, 1974). More than 20 viruses have been identified in Penaeidae shrimps (Lightner, 1999b). Four viruses which have major impacts on shrimp aquaculture include WSD, YHV (Yellow head virus), TSV (Taura syndrome virus) and IHHND (Lightner, 1996; Flegel, 1997).

Among the four viruses, WSD is the largest pathogenic infectious virus in Penaeidae (Lightner, 1996). This virus is capable of infecting at least 78 species, mainly decapods crustaceans, including marine and fresh water shrimps, crabs, crayfish and lobster (Lightner, 1996; Flegel, 2006). On the other hand, some arthropods can be the source of virus (Huang et al., 1995; Lo et al., 1999). It is rarely observed in non-Penaeidae species, except *Macrobrachium rosenbergii*, *Orconectes punctimanus* and *Procambarus sp.* (two species of crayfish) (Peng et al., 1998).

The first reports of WSD were in *P. japonicus* in Taiwan (city I-Lan), 1992

(Chen, 1995). It quickly spread in other species, especially *P. monodon* in most parts of Asian countries and the United States in 1993 (Momoyama et al., 1994; Flegel et al., 1995 ; Galaviz, 1999; Lo et al., 1999) and in Iran it was observed in *P. indicus* from Choebdeh area in 2004 (Tokhmafshan et al., 2004). Within 3-10 days, mortality in the farms reached up to 90% (Afsharnasab et al., 2007). In 2004, this virus was bringing large economical losses to the shrimp farming industry of Iran (Tokhmafshan et al., 2004). Hence WSD was caused because of the lack of shrimp culture, especially in Choebdeh area of Abadan from Iran (Afsharnasab et al., 2007).

The first record of IHHND was reported in *P. stylirostris* from Hawaii farms in 1981 (Lightner et al., 1983a, b; Bell and Lightner, 1987; Lightner, 1996). IHHND was routinely found in wild and captured *L. vannamei* without clinical signs (Mari, 1993). IHHND spread in many areas through asymptomatic carriers (Motte et al., 2003). *L. vannamei* is partially resistant to the virus. Lesions on the body and deformities such as RDS (rostrum deformity syndrome) were observed (Lightner, 1996). When RDS prevalence reached more than 30%, a great loss of 10 to 50 percent in marketing value occurred (Wyban et al., 1992). Both WSD and IHHND are important because of their wide range and significant impact on shrimp production. WSD is observed in many shrimp species and crabs, from various geographical areas accompanying with 100% mortality (Chou et al., 1998)

leading to a devastating economic impact (Lo et al., 1999; APHIS, 1999). IHHND is also one of the most serious viral diseases of farmed Penaeid shrimps (Lightner and Redman, 1991). It is widely distributed in many countries and has a wide range of hosts in many species of cultured Penaeid shrimps.

*L.vannamei* has suitable characteristics as an alien species in Iran. Already it was cultured in some areas of Iran, so its viral diseases must be detected in order to prevent spreading of the viral diseases. Nowadays different methods are used for identifying viral diseases including clinical signs, molecular methods, histopathology and transmission electron microscopy (TEM). In this study WSD and IHHND were identified using clinical signs and then confirmed by PCR assay and histopathology method in *L.vannamei* farms of Bushehr and Sistan

Balochestan provinces in Iran.

### Materials and methods

This study was performed in the grow-out shrimp farms (sites 1 and 6) and hatcheries (centers 3 and 5) of *L.vannamei* which are located in Bushehr and Sistan Balochestan provinces respectively, accompanying the previous history of WSD mortality in contrary to IHHND. Sampling was performed from December 2009 to April 2010. One hundred and fifty suspected samples of shrimp (juvenile: 8-10 g and sub adult: 22-24 g) with signs of slow growth, empty intestinal, lethargy and difference in size were collected from grow-out shrimp farms along the Persian Gulf coast (Bandar Rig, Heleh, Shif, Mond and Delvar (I and II) sites) of Bushehr province and Govatr grow-out shrimp farms along the Oman sea coast of Sistan Balochestan, Iran (Fig. 1).

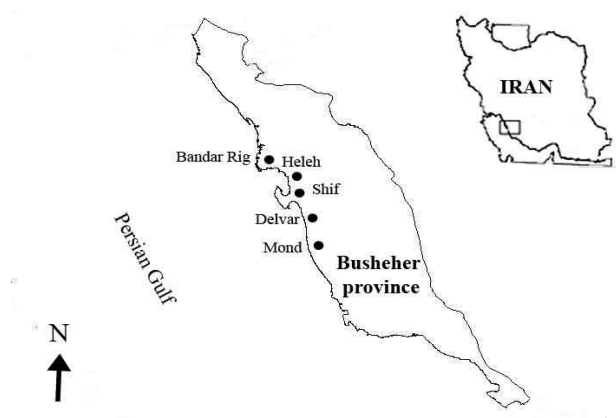


Figure 1: Location of shrimp farms in Bushehr province

In addition to 200 shrimps, larvae (Zoa and Mysis) and post larvae 6 – 15 days (PL<sub>6</sub> – PL<sub>15</sub>) produced from captured brood stocks were selected based on gross signs such as difference in size, mortality and slow growth from hatcheries. The

gross signs moribund domesticated broodstock samples of *L.vannamei* (average weight 40 - 45g) suspected to WSD include white, milky spots on the inner surface of the carapace, loss of cuticle layer and reddish discoloration of

appendages (26 samples) and IHHND accompanied with opaque, whitish abdominal dorsal muscles, opaque or milky streaks on the cuticles of the body, rostrum deformity syndrome (RDS) and

abdominal segmental abnormalities (16 samples) were obtained from hatcheries of Bushehr (5 hatcheries) and Sistan Balochestan (3 hatcheries) provinces (table 1).

**Table 1: Shrimp sampling of different stages from hatcheries and shrimp farms in Bushehr and Sistan and Balochestan provinces of Iran (H: hatchery; F: farm).**

Province	Larvae		Post larvae			Juvenile			Sub adult			Broodstock			
	N	Age	N of H	No.	Age (days)	N of H	N	Age (days)	N of F.	N	Age (days)	N of F.	N	Age (years)	N of H
	(Zoa and Mysis)														
Bushehr	72	Z <sub>1,2,3</sub> ; M <sub>1,2,3</sub>	5	48	PL <sub>10-</sub> ; PL <sub>15</sub>	5	5	50-60	6	39	110-120	6	29	1	5
Sistan Balochestan	43	Z <sub>1,2,3</sub> ; M <sub>1,2,3</sub>	3	37	PL <sub>6-</sub> ; PL <sub>12</sub>	3	3	40-50	1	22	100-115	1	13	1	3

Individual shrimps were kept on ice and examined grossly for observed signs of WSD, IHHND and other viral diseases. The sub adults and broodstock shrimps were injected into the hepatopancreas, gills and 2, 4 and 6 abdominal segmental tissues with cold Davidson's fixative solution (4°C). Samples of histopathological studies were prepared based on Bell and Lightner, (1988) and the samples were preserved in 50% ethyl alcohol for subsequent histopathological preparation and analysis (modified by Afsharnasab et al., 2007). Tissues (hepatopancreas, gills, lymphoid organ, connective tissue, hematopoietic, cuticular epidermis, stomach cuticular epidermis and striated muscles) were sectioned at 4 – 5 µm in thickness and stained with


hematoxylin and eosin phloxine (H&E/ph). Subsequently, histopathological studies of WSD and IHHND were evaluated using the light microscope (CETI; Triton II). The nested PCR had been used for the detection of WSD and IHHND (two and one step nested PCR respectively) according to a guideline of IQ2000 kite (Afsharnasab et al., 2007). After collection, samples (total body of larvae to post larvae and pleopods of juvenile to broodstocks shrimp) were wrapped in polythene bags and stored in the ice box than transported to the refrigerator (-20°C) (Lo et al., 1996). WSSV and IHHNV DNA extraction was carried out as described by Hossain et al. (2004). Next, PCR products were electrophoresed in 0.8 % agarose gel

stained with ethidium bromide, and visualized under ultraviolet transillumination.

### Results

The gross signs of WSD infections of shrimps showed reduced feeding, lethargy, increased difference in size, gathering around the ponds, swimming near the pond

surface, reddish discoloration of body and appendages (i.e. the antenna, maxillipeds, pereopods, pleopods, telson and uropods) together with a presence of white plaque on inner surface of the carapace (cephalothorax) or diffuse over the body cuticle as a characteristic feature of WSD (Figs. 2A, B, G and H).



**Figure 2:** clinical signs in infected shrimps to WSD and IHND; (A) white spots on carapace shrimps ; (B) reddish coloration of appendages (Telson area); (C) rostrum deformity syndrome (RDS); (D) milky moles on abdominal segmental; (E) abdominal abnormalities; (F) abdominal dorsal muscles opaque; (G) accumulation of dead shrimps in the pool margin; (H) difference in size

These spots were abnormal deposits of calcium salts in the cuticle. Some samples of WSD infection was confirmed by PCR

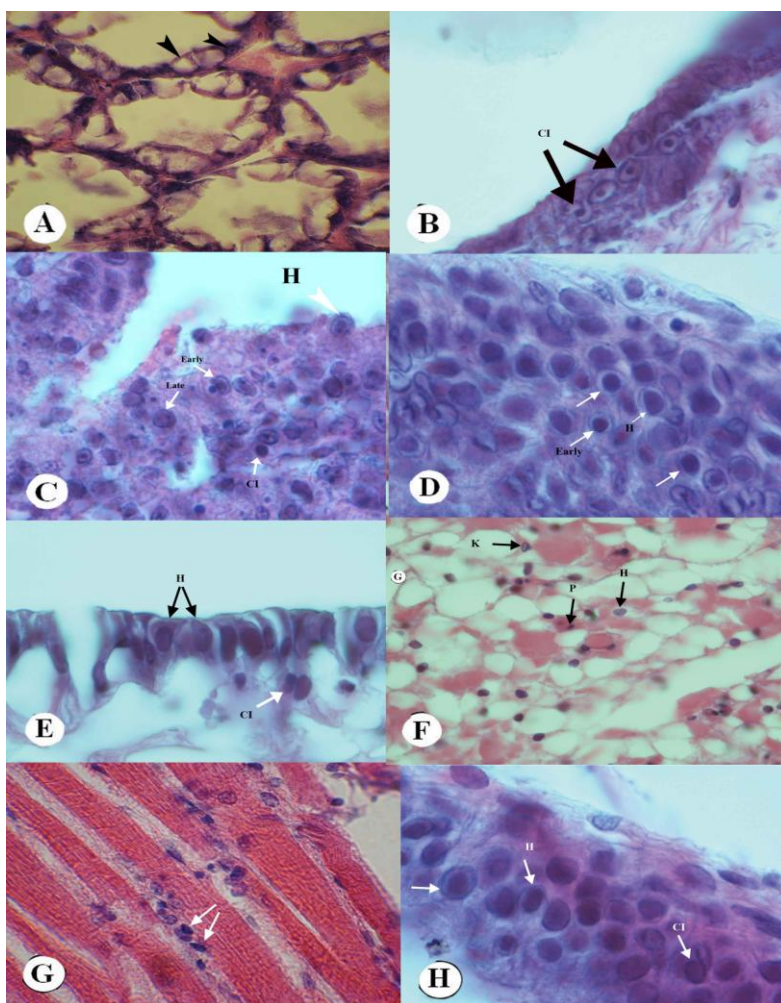
and histopathological examination. In table 2 positive numbers of samples in each stage from each province are illustrated.

**Table 2: Number of samples positive PCR infections with WSD and IHHND.**

province	No. of larvae PCR (+)		No. of post larvae PCR (+)		No. of Juvenile PCR (+)		No. of Sub adult PCR (+)		No. of Brood stock PCR (+)	
	WSD	IHHND	WSD	IHHND	WSD	IHHND	WSD	IHHND	WSD	IHHND
Bushehr	0	0	0	0	23	16	14	9	14	5
Sistan Balochestan	0	0	0	0	26	0	18	0	7	0

Histopathological lesions of hepatopancreas tissues of positive samples including vacuolization of B cells without intranuclear inclusion bodies Cowdry type A and increase in the number of F and R cells accompanied with intranuclear inclusion bodies basophilic were observed among space lobules (Fig. 3A). The epithelial pillar cells of secondary lamella of gill tissues showed basophilic intranuclear inclusion bodies Cowdry type A. Furthermore, fusion formation is made between secondary lamella of infected tissues and the cells which exhibited nucleus hypertrophy and watery and thin cytoplasm (Fig. 3B). The Lymphoid organ showed three stages of WSD infection. At the first stage, the nucleus of cells was hypertrophy and cytoplasm was thin. In the mediate stage, marginated chromatin and the space between nucleus and cell

membrane was very thin. In the late stage, the final shape of intranuclear inclusion bodies was observed as similar spheroid cells (Fig. 3C). On the other hand, the number of hyaline cells of hematopoietic tissues in infectious broodstocks obtained from hatcheries accompanied with nucleus pyknosis and karyorrhexis was recorded higher compared to hematopoietic tissues of normal shrimps (Fig. 3D). In the sections prepared with external layers, the epithelial cells of Cuticle in infected shrimps, which showed hypertrophy and basophilic intranuclear inclusion bodies, were detached from epidermis. (Fig. 3E). In these shrimps, characteristics of the WSD infection basophilic intranuclear inclusion bodies and nucleus pyknosis of the cells were abundant in connective tissues of the general body cuticle, appendages and hepatopancreas (Fig. 3F).



**Figure 3: Histopathological observations of WSD infection in shrimps tissue include nucleus hypertrophy (H), Cellular degeneration (CD), intranuclear inclusion bodies Cowdry type A (CI) and nucleus pyknosis (P) and karyorrhexis (K) in *L. vannamei* (H&E\Ph 1000X); (A) vacuolization of B cells in the hepatopancreas tissue and increase of F cells (arrowheads); (B) intranuclear inclusion bodies (arrowheads) in the gill tissue; (C) nucleus hypertrophy, early, late and Cowdry type A inclusion bodies in the lymphoid organ (arrowheads); (D) intranuclear inclusion bodies in hyaline cells of the hematopoietic tissue (arrowheads), (E) nucleus hypertrophy and large basophilic intranuclear inclusion bodies (arrowheads) in the cuticle epithelium; (F) nucleus hypertrophy, large basophilic intranuclear inclusion bodies and nucleus pyknosis and karyorrhexis (arrowheads) in the connective tissue; (G) nucleus hypertrophy and dens nucleus (arrowheads) in the striated muscles; (H) large basophilic intranuclear inclusion bodies (arrowheads) in the digestive epithelium**

Histopathological signs of striated muscles indicated hypertrophy and dense nucleus which were higher in infected broodstocks compared to post larvae (Fig. 3G). The hypertrophied columnar cells and intranuclear inclusion bodies were observed in mid gut, where some same cells were ruptured and inclusion bodies were released to the lumen of gut (Fig. 3 H) so that all these samples significantly showed WSD infectious as histopathological sign.

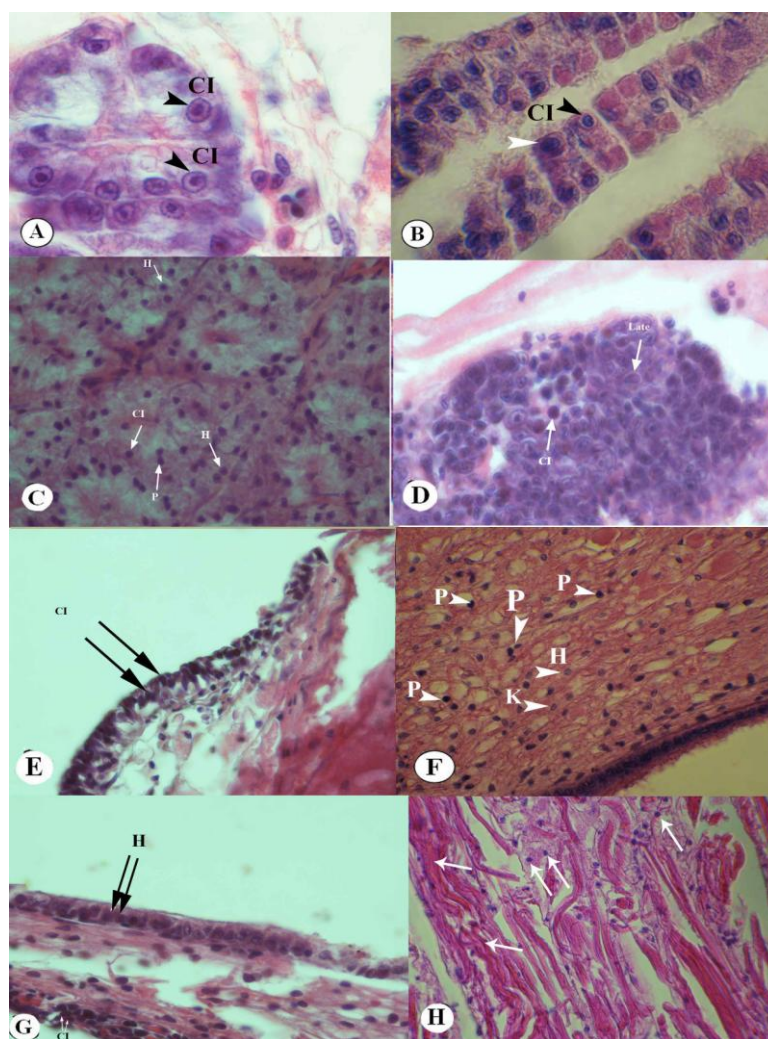
Clinical signs of IHHND infected shrimps such as opaque, whitish abdominal muscles and white, milky moles on body cuticle (abdominal segmental junction), shrimp with difference in size, slow growth and rostrum deformity syndrome (RDS) were observed in samples.

In addition to cuticular deformities found in the third to sixth abdominal segments, tail fan of sub adults and broodstocks were obtained in grow-out shrimp farms and hatcheries respectively (Figs. 2C, D, E, F and H). consequently, IHHND infected samples were confirmed using the one-step nested PCR method (table 2); results showed that positive PCR samples collected from shrimp farms (sub adult) and hatcheries (broodstock) only belonged to Bushehr province but the non positive nested PCR were in samples of Sistan Balochestan province.

Histopathological changes of the post larvae, sub adults and broodstocks infected tissues collected from hatcheries and shrimp farms were characterized by widespread cellular degeneration, severe nuclear hypertrophy and margination of chromatin in tissues, especially in the hepatopancreas, cuticular epithelium, gills, connective tissues, hematopoietic tissues and digestive epithelium (Figs. 4A,B,C,D, E, F and G).

Cell hypertrophy observed in the necrotic tissues was different from stage to stage of the viral infection. Eosinophilic intranuclear inclusion bodies Cowdry type A exhibited in numerous epithelial cells of the hepatopancreas (Fig. 4A). The tissues section showed eosinophilic enlarged nuclei, often accompanied with cloudy inclusion surrounded by marginated chromatine. Muscular atrophy, associated with reddish discoloration of the cuticles was prominent.

Histologically, the striated muscles of the affected abdominal segmental abnormality showed severe Zenker's necrosis (Fig. 4H). All tissue exhibited nucleus pyknotic and karyorrhectic in advanced infectious stage. The presence of IHHND was confirmed by histopathological observation.



**Figure 4:** Histopathological observations of IHHND infection in shrimp tissue include nucleus hypertrophy (H), Cellular degeneration (CD), Cowdry type A intranuclear inclusion bodies (CI) and nucleus pyknosis (P) and karyorrhexis (K) in *L. vannamei* (H&E\Ph 1000X); (A) Large eosinophilic intranuclear inclusion bodies Cowdry type A in the hepatopancreas tissue (arrowheads); (B) intranuclear inclusion bodies (arrowheads) in the gill tissue; (C) nucleus hypertrophy in the lymphoid organ (arrowhead); (D) intranuclear inclusion bodies and nucleus pyknosis and karyorrhexis (arrowheads) in the haematopoietic tissue; (E) nucleus hypertrophy and intranuclear inclusion bodies (arrowheads) in the cuticle epithelium; (F) nucleus hypertrophy, intranuclear inclusion bodies and nucleus pyknosis and karyorrhexis (arrowheads) in the connective tissue; (G) intranuclear inclusion bodies (arrowheads) in the digestive epithelium; (H) nucleus hypertrophy and Zenker's necrosis (arrowhead) of the striated muscles

## Discussion

Annually viral diseases cause million dollar losses for shrimp industries in the world (Wyban et al., 1992; Lightner, 1999a). To detect viral diseases of Penaeidae shrimps, different methods are being used such as clinical signs, histopathology, molecular methods (PCR) and transmission electron microscopic (TEM). Viral acute infections associated with mass death (100%) and without clinical symptoms previously proposed by Lightner (1996, 1999a), following indicated clinical signs, positive PCR of samples and histopathological lesions did not show high mortality in this study. On the other hand, Bell and Lightner (1988); Lightner (1996) stated that because of genetic mutations due to geographic isolation there may not be a suitable molecular method but IQ 2000 kite could detect two viral diseases (WSD and IHHND) accompanied with histopathological changes created by pathogenic viruses. So in this study, clinical signs of WSD and IHHND, PCR detection and their histopathologic lesions due to pathogenic viruses are discussed.

The broodstocks *L. vannamei* collected from hatcheries of Bushehr and Sistan Balochestan provinces in Iran showed typical symptoms of white spots on the inner surface of the carapace and shell similar to symptoms described by several researchers (Takahashi et al., 1994; Chou et al., 1998), but the shrimps were eating normally and no death had occurred, which may be caused by acclimation of the host with the virus (Afshinasab et al., 2009). Post larvae, juvenile and sub adult shrimps had low mortality due to medium

virulence virus but there were no signs of white spots on their carapace. The other signs were eating reduction and emptiness of their intestines, increased lethargy, swimming slowly near the pond surface and reddish body discoloration on the moribund shrimp which was similar to the report by Momoyama et al. (1994). However, positive two-step nested PCR samples indicated histopathological lesions due to the white spot virus. Results obtained from hatcheries and shrimp farms from Bushehr province were similar to the results of previous studies. Virulence studies showed that *L. vannamei* has little resistance to WSD, so when the virus has a high virulence, it could be associated with mass death (100%) (Lightner et al., 1998; Wang et al., 2000) but in this study were observed a few deaths both in Bushehr and Sistan Balochestan provinces which may be caused by medium virulence. Tokhmafshan et al. (2004) first reported WSD in *P.indicus* with high mortality in Heleh sites from Bushehr province but there were no published records of WSD in Sistan Balochestan yet, in spite of the incidence of WSD from August to September 2008. On the other hand, there were no observed gross signs and histopathological lesions in larvae stages and post larvae; therefore there were negative PCR both in Bushehr province and Sistan Balochestan province.

Hossain et al. (2004) reported the primers described by Lo et al. (1996) yielding amplicons of 1447 and 775 bp are good for confirmatory diagnosis of WSD, but not for screening purposes while OIE (2003) recommended the use of primers

yielding amplicon sizes of 1447 and 941 bp for both confirmatory diagnosis and screening of infection status. In this study primers were used that are amplified in 296 and 550 bp. Kono et al. (2004) showed that a two-step PCR amplification could detect 10 fg of WSD-DNA, which is  $10^4$  times lower than the detection limit of one-step PCR.

Nuclear hypertrophy and cellular degeneration of the cells from ectoderm and mesoderm origin were commonly observed in moribund shrimp. Although, there are many differences in virus virulence in different geographical regions, such as *L. duorarum* as a resistant host (Wang et al., 1999). After 3 days, initial studies showed that clinical signs observed in *P. japonicus* and *P. monodon* infected to WSD caused high mortality percentage (70 – 100 %), there were also differences in the intensity of virulent WSD in *P. indicus* with other species (especially *L. vannamei*) which may be due to different sensitivity species, their defensive mechanism and environmental factors in Iran environmental conditions (Afsharnasab et al., 2009). Granja et al. (2003) showed that apoptotic cells reduce virus replication and control disease in *L. vannamei*. Apoptosis plays a critical role in development and maintenance of multicellular organisms. It has also been described as an anti-viral mechanism in both insects and vertebrates. In fact, to escape the immune system and to increase their spread, some viruses such as *baculovirus* produce anti-apoptotic molecules (Granja et al., 2003). Histopathological studies implied an existence of intranuclear inclusion bodies

Cowdry type A in cells tissue target such as gills, lymphoid organ, hematopoietic tissue, cuticular epithelium, digestive epithelium, striated muscles and connective tissues which in advanced stages basophilic (H&E\Ph) was observed and similar results were reported by Perez et al., (2005); Rajendran (2006); Afsharnasab et al., (2009). Lack of polyhydrogenic materials in WSD structure caused basophilic color inclusion bodies but some of the viruses (i.e. *Parvovirus*) had polyhydrogenic material in their structure caused by eosinophilic color inclusion bodies (Afsharnasab et al., 2009). Cowdry type A, basophilic, intranuclear inclusion bodies are surrounded by marginated chromatin in hypertrophied nuclei of cells in tissues of ectodermal (gills, cuticular epithelium and digestive epithelium) and mesodermal origin (hematopoietic organs, lymphoid organ, connective tissue and striated muscle) (Kasornchandra et al., 1998; Perez et al., 2005; Rajendran, 2006). However, in white-spot disease the Cowdry type A inclusions represent an early stage of viral infection. Once infected, these nuclei undergo further degeneration and finally develop into prominent eosinophilic and pale basophilic type inclusions, and this produces confusion with IHHND infected shrimp.

Cells of the hepatopancreas have never shown to be infected with WSD but enlargement and fragility of hepatopancreas tissue of contaminated shrimps shows the infection, microscopic observations indicated vacuolated tissues which are due to increased hemolymph

from this organ to promote system of immunity cell (Lightner, 1996; Afsharnasab et al., 2009; Kakoolaki et al., 2011). Similar histopathological changes were observed among naturally infected cultured Penaeid shrimps such as *P. chinensis*, *P. japonicus*, *P. indicus*, *P. merguensis* and *P. monodon* collected from each country. These observations coincided with the reports described by Inouye et al. (1994), Momoyama et al. (1994), Chou et al. (1998), Kasornchandra et al. (1995) and Wongteerasupaya et al. (1995). Nevertheless, increased number of F and R cells, intranuclear inclusion bodies among lobules of infected hepatopancreas tissues were showed which was in contrary to the report of Lightner (1996) and Afsharnasab et al. (2009). The lymphoid organ of diseased shrimp may be extended in addition, LOS (lymphoid organ spheroids) was clearly observed in lymphoid organ, which was infected by WSD. LOS usually appears when shrimp could control or respond to the infection to the pathogenic agent in survival or chronic states (Hasson et al., 1999; Anggraeni & Owens, 2000). Nuclear pyknosis and karyorrhexis were observed in advance stages of WSD and other viral severe infections, such as YHV, TSV, LOVV (lymphoid organ vacuolization virus) (Lightner, 1996). Existence of nuclear pyknosis and karyorrhexis in the hematopoietic tissue and lymphoid organs were accompanied with losses in tissue structure that implied the attack of viral infection (Rodriguez et al., 2003) however, in samples investigated; these lesions were associated with severe WSD infection. Pantoja and Lightner (2003) indicated

nuclear pyknosis and karyorrhexis were created in shrimps that were infected to WSD experimentally. In addition, pyknosis and karyorrhexis were observed in the hematopoietic tissue of *Farfantepenaeus duorarum* with exposure to WSD experimentally (Wang et al., 1999). So in this study nuclear pyknosis and karyorrhexis were observed in these tissues which implicated it's infection. Martinez et al. (2007) reported other tissues and cells may be showing signs of WSD including the antennal gland epithelium, and the fixed phagocytes of the heart.

IHHND is one of the smallest viruses of Penaeidae shrimps that were discovered in early 1980s (Yang et al., 2007). On the other hand, there are milky moles or streaks on the surface of external cuticles (abdominal segmental) and opaque dorsal muscles in some sub adult shrimps and broodstocks selected in grow-out shrimp farms and hatcheries from Bushehr province along with the rostrum and abdominal segmental deformity which implicated IHHND infection. Results of positive one-step nested PCR studies confirmed infectious IHHND of samples collected from hatcheries and shrimp farms of Bushehr province but death was not observed because *L. vannamei* is resistant and only play a role as a carrier virus (Lightner, 2003) so this species led to the spreading of IHHNV to other parts along with economical losses (Lightner, 1999a). There were no positive nested PCR samples in Sistan Blochestan province.

The one-step nested PCR analysis of pleopods suspected samples collected

from hatcheries and farms of Bushehr and Sistan Blochestan province which indicated IHHND positive PCR in samples of Bushehr province but didn't show positive PCR samples from Sistan Blochestan. According to Tang et al. (2007), a single 309 bp amplicon with this assay indicated the presence of the infectious type of IHHND while Saksmerprome et al. (2010) used primers yielding amplicon sizes of 265 bp for detecting the Australian type, therefore primers with amplicon sizes 438 and 644bp were used in this study.

Motte et al. (2003) proposed virus can affect shrimps during larval stages to adult and through vertical transmission or consume contaminated shrimps by healthy shrimps and potentially contact contaminated water, so in this study infectious juveniles and sub adults may have been created via consuming infected shrimp. Moreover, infected juveniles (8-10 g) and sub adults (18-22 g) showed symptoms such as rostrum deformity, curly antennae, carapace blistered, cuticle deformity and stunting which are similar to the ones reported by Kalagayan et al. (1991). Also in some infected shrimp RDS was observed, Singhapan et al. (2004) reported RDS was created in *L. vannamei* by the IHHNV experiment after 30 days. Usually RDS can create nursery period and growth stages in *L. vannamei* associated with great economic damage, including irregular growth and increased difference in size (Lightner, 2003).

IHHND usually causes the involvement of ectodermal, mesodermal and rarely endodermal (Bell and Lightner,

1984). Furthermore, previous reports indicate that IHHNV has an affinity for various tissues of ectodermal and mesodermal origin, and is rarely detected in endoderm derived tissues, such as the hepatopancreas (Lightner, 1996; Gabriel and Felipe, 2000; Tang and Lightner, 2006). In spite of previously reported cases, this study indicated that IHHNV had an affinity for hepatopancreas of *L. vannamei* (juveniles, sub adults and broodstock), because the affected shrimps had typical eosinophilic intranuclear inclusion bodies for IHHND which is only found in this organ (endodermal origin). Lightner (1996) had reported HPV infections in *L. vannamei* created by parvo, or parvo-like viruses. He indicated that gross signs of HPV may not be specific, but in severe infections may include an atrophied hepatopancreas, reduced growth rate and anorexia. The characteristic lesion of HPV infection is the presence of prominent basophilic or eosinophilic intranuclear inclusion bodies of hepatopancreas tissues associated with cap formation in the hypertrophied nuclei of hepatopancreatic tubular epithelial cells (Lightner, 1996) but the result of this study is quite different, where neither basophilic intranuclear inclusion bodies nor cap formation was found.

Histopathological changes are formation of eosinophilic intranuclear inclusion bodies in the hypertrophied nuclei with marginated chromatin and cellular degeneration but affected sub adults showed growth retraction and deformities of the third to sixth abdominal segments and RDS, without eosinophilic

intranuclear inclusion bodies formation. Eosinophilic intranuclear inclusion bodies Cowdry type A is due to the existence of polyhydrogenic material in IHHNV structure (Rodriguez et al., 2003; Afsharnasab et al., 2009). These lesions were similar to those of RDS described in *P. monodon*, *M. rosenbergii* and *P. stylirostris* with IHHND infection by Primavera and Qunitio (2000) and Hsieh et al. (2006). So the presence of IHHNV from both hatcheries and grow-out shrimp farms (*L. vannamei*) indicated this virus could slowly affect growth and cause severe differences in size, which may be due to decreased feeding. Histopathological studies of gills, hematopoietic tissue, cuticular epidermis, stomach cuticular epidermis, lymphoid organ and connective tissue of infected shrimps were an evidence of hypertrophy, cellular degeneration and formation of intranuclear inclusion bodies that in advanced stages were together with nuclear pyknosis and karyorrhexis. Also, histopathological changes in the striated muscles of shrimp infection exhibited severe Zenker's necrosis and nuclear pyknosis. Muscular lysis was found in affected fiber along with inclusion bodies while Hsieh et al. (2006) had no observation of inclusion bodies in striated muscles of *M. rosenbergii*.

White spots were observed on the cuticle surface of shrimps infected to both WSD and IHHND. In WSD infection, white spots were only on the inner surfaces of carapace while in IHHND infection, white plaque was seen on the third to sixth abdominal segments. Cowdry type A inclusions were observed in infected

shrimp with WSD similar to the appearance of intranuclear inclusions caused by IHHND so inclusion bodies of WSD could be easily mistaken with inclusion bodies of IHHND but histopathological findings (H&E/Ph) showed that intranuclear inclusion bodies Cowdry type A were basophilic in infected WSD while in infected IHHND they were observed as eosinophilic. Also in hepatopancreas tissue of WSD infected shrimps showed severe vacuolization due to high activity, but no Cowdry type A inclusion intranuclear while it is usually observable in IHHND infections.

## References

- Afsharnasab, M., Dashtyannasab, A., Yeganeh, V. and Soltani, M., 2007.** Incidence of white spot disease (WSD) in *P. indicus* farms in Bushehr Province, Iran. *Iranian Journal of Fisheries Sciences*, 7, 15-26.
- Afsharnasab, M., Mortezaei, R., Yeganeh, V. and Kazemi, B., 2009.** Gross sign, histopathology and polymerase chain reaction observation of white spot syndrome virus in shrimp specific pathogen free *Litopenaeus vannamei* in Iran. *Asian Journal of Animal and Veterinary Advances*, 4, 297-305.
- Anggraeni, M. S. and Owens, L., 2000.** The haemocytic origin of lymphoid organ spheroid cells in the Penaeid prawn *Penaeus monodon*. *Diseases of Aquatic Organisms*, 40, 85-92.
- APHIS Services of the Aquaculture Industry.** Outbreak of shrimp viral disease in Central America: situation report. June 1999.
- Bell, T. A. and Lightner, D. V., 1984.** IHHND virus: Infectivity and pathogenicity studies *Penaeus*

- stylirostris* and *Penaeus vannamei*. *Aquaculture*, 38, 185-194.
- Bell, T.A. and Lightner, D.V., 1987.** IHHND disease of *Penaeus stylirostris*: Effects of shrimp size on disease expression. *Journal of Fish Diseases*, 10, 165-170.
- Bell, T. A. and Lightner, D. V., 1988.** A Handbook of Normal Penaeid Shrimp Histology. Baton Rouge, LA: *World Aquaculture Society*.
- Chen, S. N., 1995.** Current status of shrimp aquaculture in Taiwan. *In*: Browdy CL, Hopkins JS (eds.) Swimming through troubled water. Proceedings of the special session on shrimp farming. Aquaculture '95. *World Aquaculture Society*, Baton Rouge LA USA, pp. 29–34.
- Chou, H. Y., Huang, C. Y., Wang, CH., Chiang, H. C. and Lo, C. F., 1998.** Studies on transmission of white spot syndrome associated baculovirus (WSBV) in *Penaeus monodon* and *Penaeus japonicus* via water-borne contact and oral ingestion. *Aquaculture*, 164, 263–276.
- Couch, J. A., 1974.** Free and occluded virus similar to Baculovirus in hepatopancreas of pink shrimp. *Nature*, 247, 229-231.
- Flegel, T. W., Fegan, D. F. and Sriurairatana S., 1995.** Environmental control of infectious disease in Thailand. *In*: Browdy CL, Hopkins JS (eds) Swimming through troubled water, Proceedings of the special session on shrimp farming, Aquaculture '95. *World Aquaculture Society*, Baton Rouge LA USA, pp. 65–79
- Flegel, T.W., 1997.** Special topic review: major viral diseases of the black tiger prawn (*Penaeus monodon*) in Thailand. *World Journal Microbiol. Biotechnology*, 13, 433–442.
- Flegel, T. W., 2006.** Detection of major Penaeid shrimp viruses in Asia, a historical perspective with emphasis on Thailand. *Aquaculture*, 258, 1-133.
- Galaviz, S. L., 1999.** Metodos diagnostico WSBV-PCR. *In*: Zendejas, J. (Ed.), Memorias del Seminario sobre Patologia y Bioseguridad en Camaronicultura., 26 June 1999, at Mazatlan Sinaloa, Mexico. Purina Argribbrands, pp. 8 – 33.
- Gabriel, A. G. and Felipe, A. V., 2000.** Infectious disease in shrimp species with aquaculture potential. Recent Research. *Microbiology*, 4, 333–348.
- Granja, C. B., Aranguren, L. F., Vidal, O. M., Arangon, L. and Salazar, M., 2003.** Dose hyperthermia increase apoptosis in white spot syndrome virus (WSSV) infected *Litopenaeus vannamei*? *Diseases of Aquatic Organisms*, 54, 73-78.
- Hasson, K. W., Lightner, D. V., Mohny, L. L., Redman, R. M. and White, B. M., 1999.** Role of lymphoid organ spheroids in chronic Taura syndrome virus (TSV) infections in *Penaeus vannamei*. *Diseases of Aquatic Organisms*, 38, 93–105.
- Hossain, Md. Sh., Otta, S.K., Chakraborty, A., Kumar, H. S., Karunasagar, I. and Karunasagar, I., 2004.** Detection of WSSV in cultured shrimps, captured brooders, shrimp postlarvae and water samples in Bangladesh by PCR using different primers. *Aquaculture*, 237, 59–71.
- Hsieh, C. Y., Chuang, P. C., Chen, L. C., Tu, C., Chien, M. S., Huang, K. C., Kao, H. F., Tung, M. C. and Tsai, S. S., 2006.** Infectious hypodermal and hematopoietic necrosis virus (IHHND) infections in giant freshwater prawn,

- Macrobrachium rosenbergii*. *Aquaculture*, 258, 73–79.
- Huang, J., Song, X. L., Yu, J. and Yang, CH., 1995.** Baculoviral hypodermal and hematopoietic necrosis, study on the pathogen and pathology of the shrimp explosive epidemic disease of shrimp. *Marine Fish Research*, 16, 1–10.
- Inouye, K., Miwa, S., Oseko, N., Nakano, H., Kimura, T., Momoyama, K. and Hiraoka, M., 1994.** Mass mortalities of cultured kuruma shrimp *Penaeus japonicus* in Japan in 1993: electron microscopic evidence of the causative virus. *Fish Pathology*, 29, 149–158.
- Kakoolaki S., Sharifpour I., Soltani M., Ebrahimzadeh Mousavi H. A., Mirzargar S. and Rostami M., 2010.** Selected morpho-chemical features of hemocytes in farmed shrimp, *Fenneropenaeus indicus* in Iran. *Iranian Journal of Fisheries Science*, 9(2), 219–232.
- Kakoolaki S., Soltani M., Ebrahimzadeh Mousavi H. A., Sharifpour I., Mirzargar S., Afsharnasab M. et al., 2011.** The effect of different salinities on mortality and histopathological changes of SPF imported *Litopenaeus vannamei*, experimentally exposed to White Spot Virus and a new differential hemocyte staining method. *Iranian Journal of Fisheries Sciences*, 10(3), 447–460
- Kalagayan, G., Godin, D., Kanna, R., Hagino, G., Sweeney, J., Wyban, J. and Brock, J., 1991.** IHHND virus as an etiological factor in runt deformity syndrome of juvenile *Penaeus vannamei* cultured in Hawaii. *Journal World Aquaculture Society*, 22, 235–243.
- Kasornchandra, J., Boonyaratpalin, B., Khongpradit, R. and Akpanithanpong, U., 1995.** Mass mortality caused by systemic bacilliform virus incultured Penaeid shrimp, *Penaeus monodon*, in Thailand. *Asian Shrimp News*, 5, 2–3.
- Kasornchandra, J., Boonyaratpalin, S. and Itami, T., 1998.** Detection of white-spot syndrome in cultured Penaeid shrimp in Asia: Microscopic observation and polymerase chain reaction. *Aquaculture*, 164, 243–251.
- Kondo, T., Savan, R., Sakai, M. and Itami, T., 2004.** Detection of white spot syndrome virus in shrimp by loop-mediated isothermal amplification. *Journal of Virological Methods* 115, 59–65.
- Lightner, D. V., Redman, R. M., Bell, T. A. and Brock, J. A., 1983a.** Detection of IHHND virus in *Penaeus stylirostris* and *P. vannamei* imported into Hawaii. *Journal of the World Mariculture Society*, 14, 212–225.
- Lightner, D. V., Redman, R. M. and Bell, T. A., 1983b.** Infectious hypodermal and hematopoietic necrosis: a newly recognized virus disease of Penaeid shrimp. *Journal Invertebrate Pathology*, 42, 62–80.
- Lightner, D. V. and Redman, R. M., 1991.** Hosts, geographic range and diagnostic procedures for the Penaeid virus diseases of concern to shrimp culturists in the Americas. In: DeLoach, P., Dougherty, W.J., Davidson, M.A. (Eds.), *Frontiers in Shrimp Research*. Elsevier, Amsterdam, the nether land, pp. 173–195.
- Lightner, D. V., 1996.** A Handbook of Pathology and Diagnostic Procedures for Diseases of Penaeid Shrimp. *World*

- Aquaculture Society*, Press, Baton Rouge. Section 3.11.
- Lightner, D. V., Hasson, K. W., White, B. L. and Redman, R. M., 1998.** Experimental infection of Western Hemisphere Penaeid shrimp with Asian white spot syndrome virus and Asian yellow head virus. *Journal Aquatic Animal Health*, 10, 271–281.
- Lightner, D. V., 1999a.** The Penaeid Shrimp Viruses TSV, IHHND, WSSV, and YHV. *Journal of Applied Aquaculture*, 9, 27- 52.
- Lightner, D. V., 1999b.** The Penaeid Shrimp Viruses TSV, IHHND, WSSV, and YHV: Current Status in the Americas, Available Diagnostic Methods, and Management Strategies. Department of Veterinary Science and Microbiology, University of Arizona, Tucson, AZ 85721. *Journal of Applied Aquaculture*, Volum 9(2).
- Lightner, D. V., 2003.** The Penaeid shrimp viral pandemics due to IHHND, WSSV, TSV and YHV: history in the Americas and Current Status. *Aquaculture and pathobiology of crustacean and other species. proceedings of 32nd UJNR aquaculture pane symposium*, November 17–18 and 20th 2003, Davis and Santa Barbara, California, USA, pp. 1–20.
- Lo, C.F., Leu, J.H., Ho, CH., Chen, CH. and 8 others, 1996.** Detection of baculovirus associated with white spot syndrome (WSBV) in penaeid shrimp using polymerase chain reaction. *Diseases of Aquatic Organisms*, 25, 133–141.
- Lo, CF., Hsu, H. C., Tsai, M. F., Ho, CH., Peng, S. E., Kou, GH. and Lightner, D. V., 1999.** Specific genomic DNA fragment analysis of different geographical clinical samples of shrimp white spot syndrome virus. *Diseases of Aquatic Organisms*, 35, 175–185.
- Mari, J., Bonami, J. R. and Lightner D. V., 1993.** Partial cloning of the genome of infectious hypodermal and hematopoietic necrosis virus, an unusual parvovirus pathogenic for Penaeid shrimps; diagnosis of the disease using a specific probe. *Journal of General Virology*, 74, 2637-2643.
- Martinez, J. G. S., Guzman, G. A. and Ruiz, H. M., 2007.** White Spot Syndrome Virus in cultured shrimp, Review Article. *Aquaculture Research*, 38, 1339 – 1354.
- Momoyama, K., Hiraokam, M., Nakano, H, Koube, H., Inouye, K. and Oseka, N., 1994.** Mass mortalities of cultured kuruma shrimp, *Penaeus japonicus*, in Japan in 1993: histopathological study. *Fish Pathology*, 29, 141–148.
- Motte, E., Yugcha, E., Luzardo, J., Castro, F., Leclercq, G., Rodríguez, J., Miranda, P., Borja, O., Serrano, J., Terreros, M., Montalvo, K., Narváez, A., Tenorio, N., Cedeño, V., Mialhe, E. and Boulo, V., 2003.** Prevention of IHHND vertical transmission in the white shrimp *Litopenaeus vannamei*. *Aquaculture*, 219, 57-70.
- OIE (World Organisation for Animal Health) Diagnostic Manual for Aquatic Animal Diseases, 2003.** Office International Des Epizooties, Paris, France.
- Pantoja, C. R. and Lightner, D. V., 2003.** Similarity between the histopathology of white spot syndrome virus and yellow head syndrome virus and its relevance to diagnosis of YHV disease in the Americas. *Aquaculture*, 218, 47–54.
- Peng, SE., Lo, C. F., Ho, CH., Chang, C. F. and Kou, GH., 1998.** Detection of

- white spot *baculovirus* (WSBV) in giant freshwater prawn, *Macrobrachium rosenbergii*, using polymerase chain reaction. *Aquaculture*, 164, 253–262.
- Perez, F., Volckaert-Filip, A. M. and Calderon, J., 2005.** Pathogenicity of white spot syndrome virus on postlarvae and juveniles of *Penaeus (Litopenaeus) vannamei*. *Aquaculture*, 250, 586–591.
- Primavera, J. H. and Quintio, E. T., 2000.** Runt deformity syndrome in cultured giant tiger prawn *Penaeus monodon*. *Journal Crustacean Biology*, 20, 796–820.
- Rajendran, K. V., Vijayan, K. K., Santiago, T.C. and Rajan, J. J. S., 2006.** White spot syndrome virus (WSSV) infection in tiger shrimp *Penaeus monodon*: A non-lethal histopathological rapid diagnostic method using paraffin and frozen sections. *Journal of Fish Disease*, 22, 183–191.
- Rodriguez, J., Bayot, B., Amano, Y., Panchana, F., de Blas, I., Alday, V. and Calderon, J., 2003.** White spot syndrome virus infection in cultured *Penaeus vannamei* (Boone) in Ecuador with emphasis on histopathology and ultrastructure. *Journal of Fish Diseases*, 26, 439–450.
- Saksmerprome, V., Puiproma, O., Noonin, Ch. and Flegel, T. W., 2010.** Detection of infectious hypodermal and haematopoietic necrosis virus (IHHNDV) in farmed Australian *Penaeus monodon* by PCR analysis and DNA sequencing. *Aquaculture*, 298, 190–193.
- Singhapan, J., Limsuwan, C. and Chuchird, N., 2004.** Effect of infectious hypodermal and hematopoietic necrosis virus (IHHND) on growth, survival rate and histopathological changes of Pacific white Shrimp (*Litopenaeus vannamei*). Department of Fishery Biology, Faculty of Fisheries, Kasetsart University, Bangkok 10900, Thailand.
- Shatz, Y., 2008.** Fishstat plus version 2.32. Food and Agriculture organization United Nations. Copyright 1997-2007.
- Takahashi, Y., Itami, T., Kondom, M., Maeda, M., Fujii, R., Tomonaga, S., Supamattaya, K. and Boonyaratpalin, S., 1994.** Electron microscopic evidence of bacilliform virus infection in Kuruma shrimp *Penaeus japonicus*. *Fish Pathology*, 29, 121–125.
- Tang, K. F. J. and Lightner, D. V., 2006.** Infectious hypodermal and hematopoietic necrosis virus (IHHND) related sequences in the genome of the black tiger prawn *Penaeus monodon* from Africa and Australia. *Virus Research*, 118, 185–191.
- Tang, K. F. J., Navarro, S. A. and Lightner, D. V., 2007.** PCR assay for discriminating between infectious hypodermal and hematopoietic necrosis virus (IHHNDV) and virus-related sequences in the genome of *Penaeus monodon*. *Diseases of Aquatic Organisms*, 74, 165–170.
- Tokhmafshan, M., Akbari, S., Tamjidi, M., Laloi, F. and Soltani, M., 2004.** Occurrence of white spot syndrome disease in farmed *P. indicus* in Iran. *Applied Fisheries and Aquaculture*, 4, 42–47.
- Wang, Q., White, B. L., Redman, R. M. and Lightner, D. V., 1999.** Per os challenge of *Litopenaeus vannamei* postlarvae and *Farfantepenaeus duorarum* juveniles with six geographic isolates of White Spot Syndrome Virus (WSSV). *Aquaculture*, 170, 179–194.
- Wang, Q., Poulos, B. T. and Lightner, D. V., 2000.** Protein analysis of geographic isolates of shrimp white spot syndrome

- virus . *Archives of Virology Springer*, 145, 263–274
- Wongteerasupaya, C., Vickers, J. E., Sriurairatana, S., Nash, GL., Akarajamorn, A., Boonsaeng, V., Panyim, S., Tassanakajon, A., Withyachumnarnkul, B. and Flegel, TW., 1995.** Anonoccluded, systemic baculovirus that occurs in cells of ectodermal and mesodermal origin and causes high mortality in the black tiger prawn, *Penaeus monodon*. *Diseases of Aquatic Organisms*, 21, 69–77.
- Wyban, J. A., Swingle, J. S., Sweeney, J. N. and Pruder, G. D., 1992.** Development and commercial performance of high health shrimp using specific pathogen free (SPF) broodstock *Penaeus vannamei*. Proceedings of the Special Session on Shrimp Farming by Wyban J., editor. World Aquaculture Society. Baton Rouge, Louisiana. pp. 254-260.
- Yang, B., Song, X. L., Huang, J., Shi, C. Y. and Liu, L., 2007.** Evidence of existence of infectious hypodermal and hematopoietic necrosis virus in Penaeid shrimp cultured in China. *Veterinary Microbiology*, 120, 63–70.

# جداسازی و شناسائی ویروس لکه سفید میگو و ویروس نکروز پوستی و مراکز خون ساز میگوی سفید وانمی از استان های بوشهر و سیستان و بلوچستان در طی سال های 2009 و 2010 میلادی

محمد خلیل پذیر<sup>1\*</sup>، محمد افشارنسب<sup>2</sup>، بهیار جلالی جعفری<sup>1</sup>، عیسی شریف پور<sup>2</sup>، عباسعلی مطلبی<sup>2</sup>، عقیل دشتیان نسب<sup>3</sup>

## چکیده

ویروس لکه سفید میگو و ویروس نکروز پوستی و مراکز خون ساز به ترتیب در سال های 2004 و 2008 میلادی از استان بوشهر گزارش شد. هدف از انجام این مطالعه جداسازی ویروس های اشاره شده در طی سال های 2009 تا 2010 است. تعداد نمونه ها 364 عدد بود که از مراکز تکثیر و پرورش میگو در بوشهر و سیستان و بلوچستان جداسازی شد. ویروس لکه سفید از نمونه های جوان، نابالغ و مولدین و ویروس نکروز پوستی و مراکز خون ساز از میگوهای نابالغ و مولد جداسازی شد. مشاهدات هیستوپاتولوژیک ویروس لکه سفید با حضور انکلوژن بادی ها از همه بافت ها از جمله آبشش، بافت خون ساز، بافت پوششی، لمفوئید ارگان و بافت همبند ثبت گردیده است.

**واژگان کلیدی:** ویروس لکه سفید میگو، ویروس نکروز پوستی و مراکز خون ساز، میگوی وانمی، بوشهر، سیستان و بلوچستان

1- دانشکده دامپزشکی، واحد علوم و تحقیقات، دانشگاه آزاد اسلامی، صندوق پستی: 14515-775، تهران، ایران.

2- موسسه تحقیقات شیلات ایران، صندوق پستی: 14155-6116، تهران، ایران.

3- پژوهشکده میگوی کشور، صندوق پستی: 1374، بوشهر، ایران.

\*آدرس پست الکترونیکی نویسنده مسئول: dr\_pazir@yahoo.com