

Gingival neoplasm presenting as an ossifying epulis in a parrot cichlid fish (*Hoplarchus psittacus*)

Modarres Mousavi Behbahani, S.M.^{1,4}; Akhlaghi, M.^{1*}; Khodakaram-Tafti, A.²; Ahmadi, N.²; Tabatabaie Naeini, A.³

Received : August 2013

Accepted : December 2013

Abstract

This report describes the histopathological features of an ossifying epulis, measuring $1.5 \times 1 \times 1$ cm in length, width and height, respectively, on the lingual surface of the lower jaw of a 2.5 year-old parrot cichlid (*Hoplarchus psittacus*) from a commercial aquarium. The tumor had appeared in the oral cavity three months prior to its introduction to the laboratory for diagnosis. Grossly, the neoplastic mass was pale-tan with a shiny, smooth surface and coalescing areas of hemorrhage. Microscopically, the overlying epithelium was hyperplastic and extended deeply into the underlying stroma. The stroma consisted of well vascularized collagenous tissue and neoplastic fibroblasts associated with irregular cords and islands of mineral deposition as dentin-like materials confirmed by Masson's trichrome and Goldner's trichrome staining.

Keywords: Epulis, Oral tumor, Parrot cichlid, Histopathology, Radiography

1-Aquatic Animal Health Unit, School of Veterinary Medicine, Shiraz University, Shiraz, Iran

2-Department of Pathobiology, School of Veterinary Medicine, Shiraz University, Shiraz, Iran

3-Department of Clinical Sciences, School of Veterinary Medicine, Shiraz University, Shiraz, Iran

4-Present address: Shefa neuroscience research center, Tehran, Iran

* Corresponding author: akhlaghi@shirazu.ac.ir

Introduction

The generic clinical term "epulis" is a tumor or tumor-like lesion in the oral mucosa arising from the periodontal tissues and the gingival epithelium (Dubielzig et al., 1979; Head et al., 2002; Maxie, 2007). It is derived from the Greek meaning "on the gum" or "gum boil" (Neumann, 1871; Eppley et al., 1991). The term "epulis" previously has been used to describe developmental, inflammatory and hyperplastic lesions, as well as several neoplastic lesions of tooth germ origin (Maxie, 2007).

Several histological types of epulides have been distinguished in the veterinary literature including: 1) peripheral giant cell granuloma (giant cell epulis), 2) fibromatous epulis of periodontal ligament origin, 3) acanthomatous epulis (*Acanthomatous ameloblastoma*), 4) ossifying epulis (Dubielzig et al., 1979; Head et al., 2002; Maxie, 2007; Grizzle and Goodwin 2010). *Acanthomatous ameloblastoma* often invade extensively adjacent bone as well as marked osteolysis (Head et al., 2002). Gingival masses of all types, many of which are of tooth germ origin, are well known in domestic animals particularly dogs, but occur much less frequently in other species (Head et al., 2007; Maxie, 2007).

Tumors of the tooth germ tissue such as ameloblastoma (Grim et al., 2009), odontoma (Easa and Faisal, 1987; Roberts, 2012) and tumors of oral epithelium such as oral papilloma and squamous cell carcinoma (Hayes and Ferguson, 1989; Grizzle and Goodwin, 2010) have been described in

various fish species. To our knowledge, only two previous gingival neoplasms have been reported in cartilaginous fish including a mucoepidermoid papilloma in a captive sand tiger shark, *Carcharias taurus* (Rafinesque) and an epulis in a wild-caught blue shark, *Prionace glauca* (L.) (Borucinska et al., 2004). However, the literature review revealed that the occurrence of the tumors arising from the oral epithelium such as benign gingival proliferations is very rare in the fish populations. Thus, the aim of this case report was to describe clinical and histopathological features of a gingival neoplasm presenting as an ossifying epulis in a parrot cichlid fish (*Hoplarchus psittacus*).

Materials and methods

A 2.5 year-old parrot cichlid (*Hoplarchus psittacus*) was submitted from a commercial aquarium with a gingival mass which almost completely obstructed the mouth on the lingual surface of the lower jaw (Fig. 1). Upon submission, the fish was immediately housed in a large indoor aquarium. The fish's general condition was good except for the gingival mass and there were no obvious ulcers or erosions on the tumor surface. Also, there were no other structural deformities. On physical examination, the mass was firm and flesh colored and was noted to interfere with normal feeding. Approximately 1 week after its arrival in the fish health unit, the fish was anesthetized with tricaine methanesulfonate (65 mg / L) for radiographic examination and surgery. Intraoperative manipulation of the

mass found that it was attached to the floor of the mouth. After examination, the head of the fish was radiographed in lateral recumbency. The mass was removed during a ten minutes surgery and the area of the attachment was sutured. Subsequently, the fish was allowed to recover in the aquarium with adequate oxygenation and full recovery occurred within 1 minute. The fish presented no post-surgical complications.



Figure 1: Gingival mass (epulis) on the lingual margin of the lower jaw in parrotfish, the tumor has a shiny and smooth surface.

The radiographic examination of the gingival mass showed calcification in the area attached to the adjacent normal lip (Fig. 2). Grossly, the mass was a fleshy, sessile and local exophytic growth that arose from the mediolateral aspect of the floor of the mouth bordering and slightly overlapping the lingual margin of the lower jaw. The tumor, measuring $1.5 \times 1 \times 1$ cm in length, width and height, respectively, and weighted 1.7 g, had a shiny surface and was pale-tan (in comparison with the surrounding white normal mucosa) with coalescing areas of hemorrhage. Tissue

samples from the mass were fixed in 10% neutral buffered formalin, processed, embedded in paraffin wax, sectioned at 5-6 μ m thickness, and stained with hematoxylin and eosin (H&E), Masson's trichrome and Goldner's trichrome methods (Fig. 3).

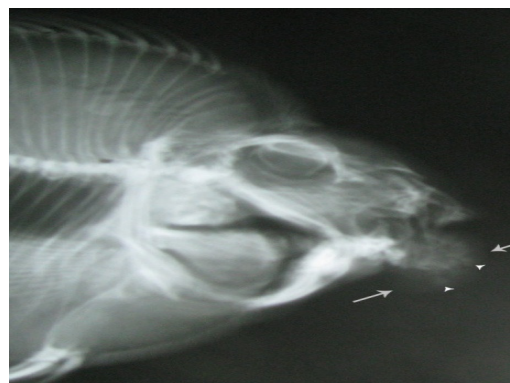

Figure 2: Lateral radiograph of gingival mass (epulis) on the lingual margin showing classification in the area attached with lip (arrows show the tumor borders, small arrow heads show calcification parts).

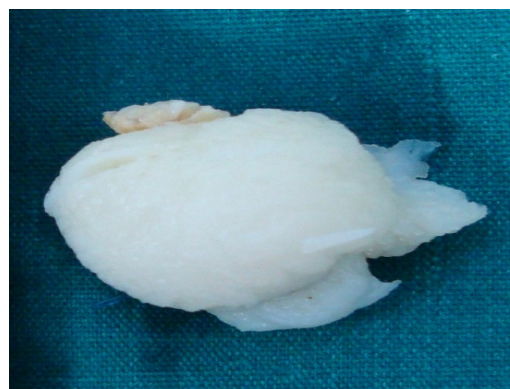

Figure 3: Gingival mass (epulis) removed by surgery and fixed in 10% neutral buffered formalin, measured $1.5 \times 1 \times 1$ cm and weighted 1.7 g. (Note to the top, the point of the attachment of the tumor to the floor of the mouth).

Results

Histopathological examination of the mass revealed an unencapsulated lesion covered with hyperplastic stratified squamous epithelium interspersed with mucous cells. The normal mucosa of the oral cavity in teleost fish is composed of a stratified squamous epithelium that has abundant mucous cells supported by a densely collagenous propria mucosa (Easa and Faisal, 1987). The normal structure of the gingival of a healthy parrot cichlid has the same epithelium with mucous cells supported by a densely collagenous, sparsely cellular lamina propria (Fig. 4), while the epithelium in this tumor consisted of a hyperplastic stratified epithelium with a distinct basement membrane and abundant collagenous stroma associated with irregular islands of mineralized tissues (Fig. 5). Rete pegs of hyperplastic gingival epithelium were extended deep into the underlying stroma. Features of the epithelium included increased intraepithelial lymphocytes and occasional hydropic degeneration without viral inclusion bodies. There were mild to moderate mononuclear cell infiltrates consisting of lymphocytes and plasma cells in the lamina propria of the gingival mucosa. Stromal elements accompanied by a variably extensive chronic or chronic-active inflammatory reaction such as neoplastic fibroblasts. In addition to well vascularized collagenous tissue, the stroma was consisted of irregular islands of mineralized trabeculae as dentin-like materials confirmed by Goldner's trichrome staining (Fig. 6). The histopathological features of gingival neoplasm presenting as an

ossifying epulis in a parrot cichlid fish are summarized in Table 1.

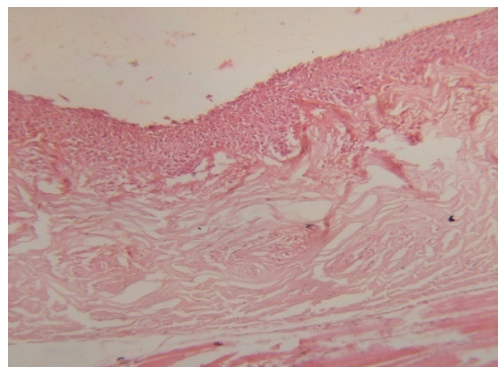


Figure 4: The normal structure of the gingival epithelium of a healthy parrot cichlid composed of a stratified squamous epithelium with mucous cells supported by a densely collagenous, sparsely cellular lamina propria (H& E, $\times 100$).

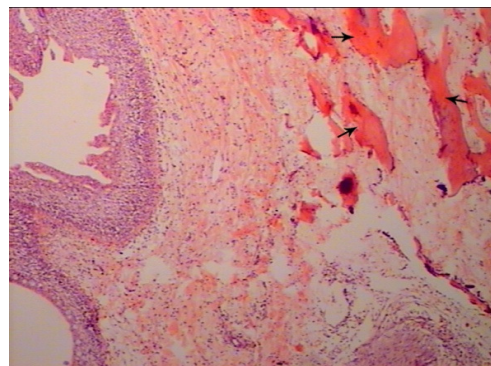


Figure 5: Ossifying epulis with a hyperplastic stratified squamous epithelium with a distinct basement membrane, well vascularized and abundant collagenous stroma associated with irregular islands of mineralized tissues as dentin-like materials (arrows) (H & E, $\times 100$).

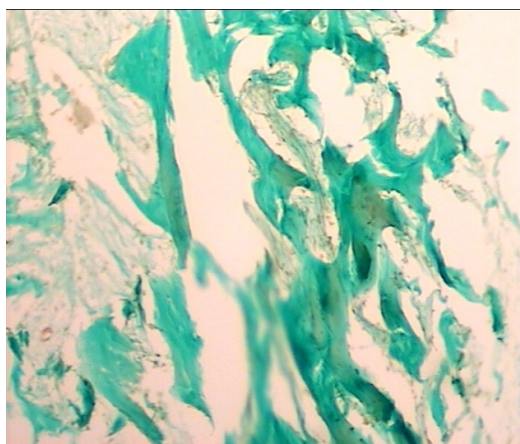


Figure 6: Ossifying epulis consisted of mineralized tissues in the tumor stroma (Goldner's trichrome, $\times 180$).

Table 1: The histological features of gingival neoplasm presenting as an ossifying epulis in a parrot cichlid fish (*Hoplarchus psittacus*) and their intensity

	Histopatological	features	Intensity
1	Solid sheets of epithelium	-	-
2	Stratified squamous epithelium	+	Thickened
3	Formation of hard tissue	+	Moderate
4	Inflammation	+	Moderate
5	Neoplastic fibroblasts	+	Moderate

Discussion

The morphologic diagnosis in this case was based on histopathological features that were modified from Head's histopathological criteria of canine epulides by de Bruijn et al. (2007). According to such criteria including a lack of solid sheets of epithelium, thickened stratified squamous epithelium, moderate formation of hard tissue, moderate inflammation and neoplastic fibroblasts as the main component of the mass (Table 1), the present tumor was diagnosed as an ossifying epulis.

Fish are subjected to the development of neoplasia in the same way as are higher animals. In fish, the prevalence of tumors in

terms of overall numbers is not high (Roberts, 2012). To the best of our knowledge which is based on a review of the veterinary literature and particularly fish medicine journals, it appears that this tumor is rare in fish populations especially considering the frequency and significance of epulides in higher animals. The etiology of the tumor in the present case was not determined. Known and suspected factors contribute to tumor formation in fish include viruses, chemical or biological toxins, physical agents, hormones, and the age, sex, genetic predisposition and immunological competence of the host (Roberts, 2012). However, it is necessary to

study the factors which contribute to the mass formation and growth.

This is the second report of an ossifying epulis in fish and the first report in the teleost fish. Because of the low prevalence of neoplasia in fishes and the rarity of this particular type of tumor, we believe that this report adds important information to the classification of tumors in these animals. The present report showed that epulides should be included in the differential diagnosis of masses in the oral cavity of fishes.

Aknowledgments

Mr Mohammad saeid Fereidoni from the aquatic animal health unit, staff of the radiology, surgery and pathology laboratories of the veterinary school, Shiraz University helped much for this work.

References

- Borucinska, J. D., Harshbarger, J. C., Reimschuessel, R. and Bogicevic, T., 2004.** Gingival neoplasms in a captive sand tiger shark, *Carcharias taurus* (Rafinesque), and a wild-caught blue shark, *Prionace glauca* (L.). *Journal of Fish Diseases*, 27, 185-191.
- de Bruijn, N. D., Kirpensteijn, J., Neyens, I.J.S., Vanden Brand, J.M.A. and Vanden Ingh, T. S. G. A. M., 2007.** A clinicopathological study of 52 feline epulides. *Veterinary Pathology*, 44, 161-169.
- Dubielzig, R. R., Goldschmidt, M. H. and Brodey, R. S., 1979.** The nomenclature of periodontal epulides in dogs. *Veterinary Pathology*, 16, 209-214.
- Easa, M. E. and Faisal, M., 1987.** Odontogenic fibroma in gilthead sea bream, *Sparus aurata* L. *Journal of the Egyptian Veterinary Medical Association*, 47, 47-53.
- Eppley, B. L., Sadove, A. M. and Campbell, A., 1991.** Obstructive congenital epulis in a newborn. *Annals of Plastic Surgery*, 27, 152-155.
- Grim, K. C., Wolfe, M. J., Edwards, M., Kaufman, J., Onjukka, S., Moran, P. and Wolf, J. C., 2009.** Epizootic Ameloblastomas in Chinook Salmon (*Oncorhynchus tshawytscha*) of the Northwestern United States. *Veterinary Pathology*, 46, 622-635.
- Grizzle, J. M. and Goodwin, A. E., 2010.** Neoplasms and related disorders. In: Leatherland, J.F. and Woo, P.T.K. (Eds.), *Fish Diseases and Disorders*, Vol. 2, Non-Infectious Disorders, 2nd edn. CAB International, Oxfordshire, pp.19-84.
- Hayes, M. A. and Ferguson, H. W., 1989.** Neoplasia in fish. In: Ferguson, H.W. (Ed.), *Systemic pathology of fishes*. Iowa State University Press, Ames, IA, USA, pp.230-247.
- Head, K. W., Else, R. W. and Dubielzig, R. R., 2002.** Tumors of the alimentary tract. In: Meuten, D.J. (Ed.), *Tumors in Domestic Animals*, 4th edn. Iowa State University Press, Ames, IA, USA. pp.401-481.

Maxie, M. G., 2007. Jubb, Kenedy, and Palmar's Pathology of Domestic Animals, Vol 2, 5th edn. Saunders Elsevier\, Philadelphia, USA.

Neumann, E., 1871. Ein fall von congenitale epulis. *Arch Heilkd*, 12, 189-190.

Roberts, R.J., 2012. Fish Pathology, 4th edn, Wiley-Blackwell, Chichester, pp. 167-185.