

The *in vivo* effect of methyl tert-butyl ether on liver, gills and kidney tissues of *Rutilus caspicus*

Mohammadzadeh Baran S.¹; Mashinchian Moradi A.¹;
Sharifpour I.^{2*}; Jamili Sh.^{1,2}; Ghavam Mostafavi P.¹

Received: April 2017

Accepted: July 2017

Abstract

This study was conducted to evaluate histopathological responses in liver, gills and kidney in *Rutilus caspicus* exposed to concentrations of 50, 100, 150 mg L⁻¹ of methyl tert-butyl ether, for 7, 14, and 21 days. The experiments were conducted in water temperature of 19±1 °C, dissolved oxygen of 7.6 ± 0.2 mg L⁻¹ and zero salinity. A total of 156 fish were studied in this experiment. In the first, second and third week of the experiment, three fish were taken randomly from each aquarium. To examine the tissues, the liver, gills and kidney were isolated and prepared for evaluation using standard histological techniques. Tissue damage in the liver includes: blood congestion, congestion of sinusoid, melano macrophage aggregation, hepatocyte hypertrophy, vacuolation, degeneration and cellular necrosis. Gill tissue damage includes: hyperplasia, degeneration lifting, telangiectasis, in secondary lamellae, blood congestion in primary and secondary lamellae, S formation of lamellae, reduction in length of secondary lamella, lamellar fusion and cellular necrosis. Tissue damage in the kidney includes: tubular shrinkage, blood congestion, melano macrophage aggregation, glomerular shrinkage, cellular necrosis, tubular degeneration, reduction in interstitial cells and interstitial hematopoietic tissue degeneration. The amount of tissue damages in high concentrations of pollutants was high, while gill, liver and kidney in the control group was observed in the normal outline. The results of this study showed that methyl tert-butyl ether (MTBE) can cause damage in vital tissues of *R. caspicus* and even, eventually lead to death.

Keywords: Gill, Histopathology, Kidney, Liver, Methyl tert-butyl ether, *Rutilus caspicus*

1-Department of Marine Biology, Science and Research Branch, Islamic Azad University, Tehran, Iran.

2-Iranian Fisheries Sciences Research Institute (IFSRI), Agricultural Research Education and Extension Organization (AREEO), Tehran, Iran.

*Corresponding author's Email: isharifpour@yahoo.com

Introduction

MTBE is usually used as octane booster to increase the oxygen in gasoline formula. MTBE causes an increase in the fuel oxygen levels and reduces the amount of carbon monoxide and air pollution (USEPA, 1988).

Although using MTBE will improve public health and the environment, but its world top production (26 million tons per year) and its widespread use in Iran (900 thousand tons) causes the release of large quantities of MTBE in the environment, which can have detrimental effects on human health and the environment. The threshold of taste and smell of MTBE are 2 and 2.5 $\mu\text{g L}^{-1}$, respectively. Thus, MTBE at very low concentrations make the consumption of drinking water inappropriate. The EPA (Environmental protection agency) recommended daily allowance of 20 to 40 micrograms per liter based on the thresholds of smell and taste MTBE. It is believed that at this concentration, the undesirable smell and taste of MTBE will not be felt and appropriate immune distance of potential carcinogenic effects of MTBE will be created, (U.S. Environmental Protection Agency, 200). MTBE contamination of water resources is caused by leaking underground fuel tanks, transmission lines, filling tanks above ground and mess at the gas stations (Johnson *et al.*, 2000).

Histopathological investigations have long been recognized to be reliable biomarkers of stress in fish (Van der Oost *et al.*, 2003).

Histopathological changes can be used widely as biomarkers in assessing

the health of the fish exposed to contaminants, both in the lab and in field studies. One of the great advantages of biological and histopathological environmental monitoring is that these biomarkers allow the study of specific target organs, including the liver, gills and kidney responsible for vital functions such as respiration, excretion and accumulation and biotransformation of contaminants in fish (Gernhofer *et al.*, 2001).

Moreover, the changes in the organs are normally easier to identify than their performance (Fanta *et al.*, 2003). These changes are used as warning signs of damage to the health of animals (Hinton and Laurén, 1990).

The gills and gut of the fish are the main point of entry of contaminants into the internal organs such as the kidney and liver via blood (Takashima and Hibiya, 1995).

The liver is an organ that performs various actions in connection with metabolism and since it participates in the processes such as bio-company transfers, it is of paramount importance in fishes (Rezvani *et al.*, 2006).

Histopathological changes in liver monitoring is a very sensitive and accurate method to evaluate the combined effects of experimental studies. The teleostean kidney is one of the first organs to be affected by contaminants in the water (Thophon *et al.*, 2003).

The gill is the first organ showing defensive reactions after exposure to any externally stimulated material (Poosti and Marvasti, 2008). The gills

are important organs for respiration, osmoregulation, acid-base balance and nitrogenous waste excretion (Heath, 1987). Hence, this study was undertaken to examine the effects of different sublethal MTBE concentrations on histological aspects of liver, gills and kidney of the freshwater fish, *R. caspicus*

However, studies have been conducted on the effect of MTBE on vascular development in the zebrafish (*Danio rerio*) embryo (Bonventre *et al.*, 2011) and also, on the effect of MTBE in the short term on reproductive process of Zebra fish and fathead minnow and its effects on the endocrine glands (Mihaich *et al.*, 2015) and, the toxic effects of MTBE on fish for the determination of LC50 (Naddafi *et al.*, 2008), the impact on sex hormones of mice (Khalili *et al.*, 2015), and the impact of MTBE on shellfish named *Daphnia magna* and a bacterium called *Vibrio fischeri* on performance (Hernando *et al.*, 2003). In this study, the effects of MTBE on some tissues of *R. caspicus* will be discussed.

R. caspicus is one of the most prized fish living in the Caspian Sea, however, recently its population in the Caspian Sea has declined due to overfishing and habitat destruction and increased pollution (Hoseini *et al.*, 2012). This study aimed to investigate the effects of sub-lethal concentrations of MTBE on *R. caspicus* that has not been studied prior to this. The aim of this study is to help to characterize water quality standards for the pollutants and preserve this valuable fish species which is endangered.

Materials and methods

A total number of two hundred and twenty *R. caspicus* with an average body length of 150 ± 30 mm and a weight of 15 ± 3 g were obtained from the Syjuval hatchery located in Bandar Turkman in Golestan Province and transferred in bags containing water (1/3) and oxygen (2/3) to the laboratory in Islamic Azad University, Science and Research Branch of Tehran. In the laboratory fish were kept in an aquarium holding 150 liters of water and equipped with an oxygen pump for 10 days before the experiment for the adaptation of fishes to their environmental conditions. Biomar floating feeds (from Sera Granulat Company, China) were used to feed the fish (once every 24 hours) during the adaptation period.

After the period of adaptation, 15 fishes were placed in the 50-liter aquaria. There were 3 control aquaria and 9 experimental aquaria. All aquaria were provided with oxygen pumps for aeration. Salinity was zero ppt and water temperature was 19 ± 1 °C. Based on preliminary tests and the results of previous studies) sub-lethal concentrations of 50, 100 and 150 mg L^{-1} of MTBE were used in this experiment. In fish, the LC50 (96 h) of MTBE is about 600 to 900 ppm. Therefore, approximately 1/4 (750 mg L^{-1}) taken up during the tests will not create problems for fish (Werner *et al.*, 2001; Naddafi *et al.*, 2008). Fishes were under semi-static conditions for 21 days (70% of water was exchanged changed every 48 hours and then the desired dose of MTBE was replaced) and the

control fishes were exposed to fresh water.

Sampling

In the first, second and third week of the experiment, three fish were taken randomly from each aquarium. The fish were then anesthetized with 150 ppm clove essence (Sharifpour *et al.*, 2002).

A piece of the liver and kidney and an arch of gill was cut out and fixed in 10% buffered formalin for at least 24 hours before processing. Formalin was refreshed after 6 hours.

Histology

Histological analysis was performed according to standard histological techniques (Roberts and Rodger, 2001). Dewatering and drying the tissues was conducted with ethanol of varying purity and then cleared with xylene. They were then put into liquid paraffin at 58 °C and paraffin blocks were prepared. Tissue sections with 6 µm of thickness were taken by rotary microtome (Leica Rm2255). Tissue sections were stained using hematoxylin and eosin (H&E) (Microm HMs7). The microscopic slides were

examined using a light microscope (Olympus CX21).

Severity of damage in tissues was determined on - =no significant microscopic changes.

+ = mild changes (10 percent change in 40x objective microscope view). ++ = moderate changes (20 percent change in 40 x objective microscope view), +++ = severe changes (more than 20 percent change in 40 x objective microscope view) (Dutta *et al.*, 1996).

Results

Gill tissue changes

Histological examination of the gills showed a proper organization in filaments in control fish. In the treatment samples with MTBE, tissue changes such as cell hyperplasia in epithelial layer of primary filaments, as well as fusion and telangiectasis in secondary lamellae were observed. Other observations during the trial, including edema and detachment of gill basement membrane, congestion in primary filaments, and decreased length of secondary lamellae due to the exposure to different concentrations of MTBE were seen.

Table 1: Histopathological scores of Caspian roach gill exposed to continuous exposure of MTBE.

DAYS	7 day				14 day		21 day		
DOSE	50 mg L ⁻¹	100 mg L ⁻¹	150mg L ⁻¹	50 mg L ⁻¹	100mg L ⁻¹	150 mg L ⁻¹	50 mg L ⁻¹	100 mg L ⁻¹	150 mg L ⁻¹
Tissue changes									
Hyperplasia	+	++	+	+	+	++	++	+++	+++
Degeneration in primary and secondary lamellae	+	+	+	+	+	++	++	++	++
Detachment of basement membrane of lamellae	+	+	+	+	+	++	++	++	+++

Table 1 continued:

Telangiectasis	–	+	++	+	+	++	++	+	+
Epithelial lifting	–	+	++	+	+	++	++	++	+++
Blood congestion in primary and secondary lamellae	–	+	++	+	+	+	++	++	+++
S formation of lamellae	–	+	++	+	++	++	+	+	++
Reduction in length of secondary lamellae	–	+	+	+	+	+	++	++	+++
Lamellar fusion	–	–	–	–	–	+	++	+	++
Cellular necrosis	–	+	+	++	++	++	++	+++	++

The indices above were used to show the severity of the lesions in the tissues:

- = no significant microscopic changes, + = mild changes (10 percent change in 40x objective microscope view), ++ = moderate changes (20 percent change in 40 x objective microscope view), +++ = severe changes (more than 20 percent change in 40 x objective microscope view) (Dutta *et al.*, 1996).

Liver tissue changes

The survey showed that in the liver of control fish, there was no histological abnormalities. Studies on the liver tissue revealed that fish after exposure to MTBE showed an accumulation of blood in the central vein. The survey

also showed that increasing concentrations of MTBE causes vacuolization of hepatocytes, cellular degeneration and damage of hepatocytes core, sinusoids hyperemia and liver tissue necrosis.

Table 2: Histopathological scores of Caspian roach liver exposed to continuous exposure of MTBE.

DAYS	7 day			14 day			21 day		
DOSE	50 mg L ⁻¹	100 mg L ⁻¹	150mg L ⁻¹	50 mg L ⁻¹	100mg L ⁻¹	150 mg L ⁻¹	50 mg L ⁻¹	100 mg L ⁻¹	150 mg L ⁻¹
Tissue changes									
Blood congestion	+	+	++	+	++	++	++	++	++
Congestion of sinusoid	+	+	+	++	++	++	++	++	++
Melano macrophage aggregation	–	–	+	–	++	+	+	++	++
Hepatocyte hypertrophy	–	–	+	+	+	++	++	+++	++
Hepatocyte vacuolation	–	–	+	–	+	++	++	+++	++
Hepatocyte degeneration	–	–	++	+	+	++	++	++	++
Cellular necrosis	–	–	+	+	+	++	++	++	++

The indices above were used to show the severity of the lesions in the tissues:

- = no significant microscopic changes, + = mild changes (10 percent change in 40x objective microscope view), ++ = moderate changes (20 percent change in 40 x objective microscope view), +++ = severe changes (more than 20 percent change in 40 x objective microscope view) (Dutta *et al.*, 1996)

Changes in renal tissue

Histological review of the kidney showed that in all the fish in the control group there was no abnormality of tissue. The results showed that at different concentrations of MTBE, different tissue changes in all fish

exposed to this substance can be seen. These changes include shrinkage of glomerula, tubular cell degeneration, interstitial and glomerular, increased interstitial cells and accumulation of melanomacrophage.

Table 3: Histopathological scores of Caspian roach kidney exposed to continuous exposure of MTBE.

DAYS	7 day				14 day		21 day		
DOSE	50 mg L ⁻¹	100 mg L ⁻¹	150mg L ⁻¹	50 mg L ⁻¹	100mg L ⁻¹	150 mg L ⁻¹	50 mg L ⁻¹	100 mg L ⁻¹	150 mg L ⁻¹
Tissue changes									
Tubular shrinkage	+	+	+	+	+	+	+	++	+++
Blood congestion	+	+	+	+	++	++	+	++	++
Melano macrophage aggregation	-	-	+	+	++	++	+	++	+++
Glomerular shrinkage	+	+	+	+	+	+	+	++	++
Cellular necrosis	-	-	-	-	+	+	+	++	++
Tubular degeneration	-	-	+	+	++	++	+	++	+++
Reduction in interstitial hematopoietic tissue	-	-	-	+	++	+	+	+	++

The indices above were used to show the severity of the lesions in the tissues:

- = no significant microscopic changes. + = mild changes (10 percent change in 40x objective microscope view). ++ = moderate changes (20 percent change in 40 x objective microscope view) . +++ = severe changes (more than 20 percent change in 40 x objective microscope view)(Dutta *et al.*, 1996)

Discussion

In the present study, the evaluation of the samples of the kidney shows tissue changes such as tubules contraction, blood congestion, melanomacrophage aggregation, contraction of the glomeruli, degeneration of tubules, reduction of interstitial tissue cells and necrosis. Formation of Melanomacrophage centers is the immune response of this organ against the external irritating substances.

During this reaction pigments are spread out of the pigment cells and defend the organs against the annoying factor, then swallowed by macrophages and excreted from the body (Shahsavani and Movasaghi, 2002). Black spots seen in some cases are macrophages containing melanin and show the above defense mechanism. Due to the exposure of mouse embryos to MTBE, damages such as tubules degeneration, epithelial destruction and

glomeruli dilatation in the kidney were observed (Aghaie *et al.*, 2012). Under the effect of the rainbow trout exposed to disinfectant Aquagerm, increased melanomacrophage centers, glomeruli shrinkage and Bowman's space dilation were observed (Afzali *et al.*, 2010). The results of the impact of mercury on the liver and kidneys of *Hoplias malabaricus* indicates that, there is a lot of damage such as necrosis, atrophy and bleeding (Mela *et al.*, 2007).

The liver is an organ that performs various actions in connection with the metabolism and since it participates in the processes such as bio-company, transfers are of paramount importance in fishes (Rezvani *et al.*, 2006). The liver due to higher sensitivity to pollutants, are susceptible to damage from chemicals and is an appropriate organ in investigation of the effect of environmental stimuli in animals. Therefore, the change in the structure of the liver plays an important role in the assessment of fish health (Heidari Jamebozorgi, 2009). In the present study surveys of liver samples showed changes such as blood congestion, sinusoidal cell accumulation, generation of melanomacrophage centers, hypertrophy of hepatocytes, cell vacuolation, degeneration of hepatocytes and necrosis. Exposure of mouse embryos to MTBE can cause degeneration of liver cells (Aghaie *et al.*, 2012). The inhalation of MTBE in experiments on rabbits causes the blood accumulation in vessels, degeneration of the liver cells and fat cells (Al-Sahhaf, 2012).

Hepatocytes may thus be expected to be the primary targets of toxic substances, providing an excellent biomarker of aquatic pollution (Braunbeck and Völkl, 1993).

Some studies revealed that interstitial hepatocytes of Nile tilapia exposed to contaminated sediment showed hydropic swelling (Peebuaa *et al.*, 2006).

Damage will affect oxygen exchange and tissue respiration, culminating in organ and tissue hypoxia, degeneration and necrosis (Taiwo *et al.*, 2005).

An increase in the density of the melanomacrophage aggregates is generally related to important hepatic lesions (Pacheco and Santos, 2002), such as degenerative and necrotic processes.

The gill is the first organ showing defensive reactions after exposure to any externally stimulated material (Poosti and Marvasti, 2008). Gill lesions observed in this study include hyperplasia, degeneration of primary and secondary lamellae, Detachment of basement membrane, telangiectasis, blood congestion, S shaped secondary lamellae, reduced length of the secondary lamellae, fusion of the secondary lamellae together and necrosis of the lamellae.

In another study, the effects of heavy metals on the gills of common carp was assessed in which changes such as hemorrhage, necrosis, and accumulation of melanomacrophage centers were observed (Ghovati *et al.*, 2011). The chronic exposure of *Carassius auratus* to organic pollutants (naphthalene, phenol Base A and

butachlor), resulted in the curvature of the secondary lamellae, dilated capillaries of the lamellae, fusion of the secondary lamellae together, and degeneration of the epithelium of primary and secondary lamellae (Eghdami *et al.*, 2014). Congestion of blood vessels as a tissue damage were reported as the effect of butachlor on the gills of *Paralichthys olivaceus* (Huarong *et al.*, 2010). Hyperplasia was reported in examining the impact of pesticides and petroleum hydrocarbons on the gill of eel *Anguilla anguilla* (Ribeiro *et al.*, 2005) and also the effect of naphthalene on the gills the *Trochinosus Carolinus*, (Santos *et al.*, 2011). The results of these tests indicate harmful effects of chemical and organic compounds, and also heavy metals on the gills. Some studies revealed that interstitial edema is one of the more frequent lesions observed in gill epithelium of fish exposed to heavy metals (Mallatt, 1985).

These histopathological changes of the gills likely resulted in hypoxia, respiratory failure problems with ionic and acid-base balance (Alazemi *et al.*, 1996). The results of the present experiment also confirm the above findings.

A wide range of toxic effects of MTBE have been demonstrated in aquatic animals in nature and in experimental animals by several routes of exposure, and under different clinical conditions in humans. In conclusion the present study showed that histopathological biomarkers of toxicity in fish organs are a useful indicator of environmental pollution. The organ and

tissue damage in the experimental fish was due to the direct toxicity of the MTBE on the gills, liver and kidney. Also, the results showed that the degree of distortion of the tissues was proportional to the concentration of the MTBE. The results of this study showed that most damage was observed in the tissues at a dose of 150 mg per liter of MTBE in 21 days of exposure, indicating that if the MTBE dose and duration of exposure increases, it can be very dangerous for the fish and may eventually lead to death.

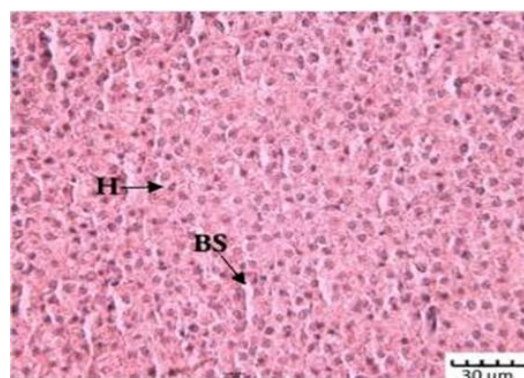


Figure 1: Normal liver tissue of *Rutilus caspicus* exposed to 0.00 mg L⁻¹ MTBE. H&E. Bar: 30μm; showing hepatocytes (H) blood sinusoid (BS).

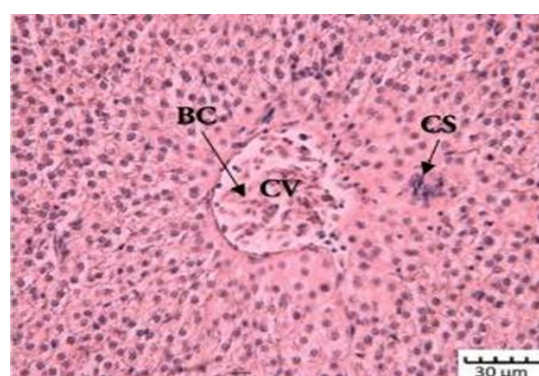


Figure 2: Liver tissue of *Rutilus caspicus* exposed to 50.00 mgL⁻¹ MTBE after 21 days. H&E. Bar: 30μm; Central Vein (CV), Central Vein blood congestion (BC), congestion of sinusoid (CS).

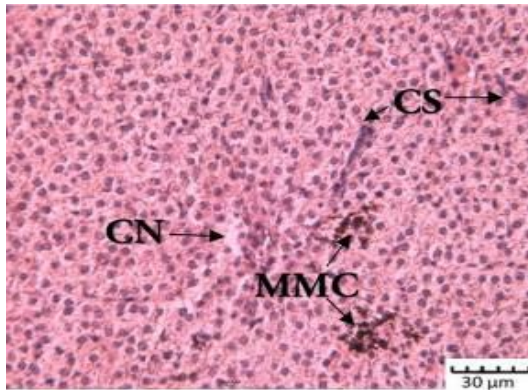


Figure 3: liver tissue of *Rutilus caspicus* exposed to 100.00 mg L⁻¹ MTBE after 14 days. H&E. Bar: 30µm; congestion of sinusoid (CS), Melano Macrophage Center (MMC), Cellular Necrosis (CN).

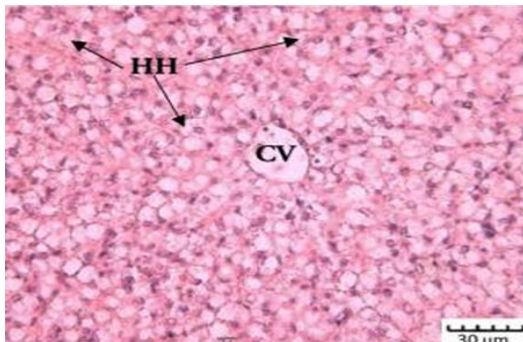


Figure 4: Liver tissue of *Rutilus caspicus* exposed to 100.00 mg L⁻¹ MTBE after 21 days. H&E. Bar: 30µm; Hepatocyte Hypertrophy (HH), Central Vein (CV).

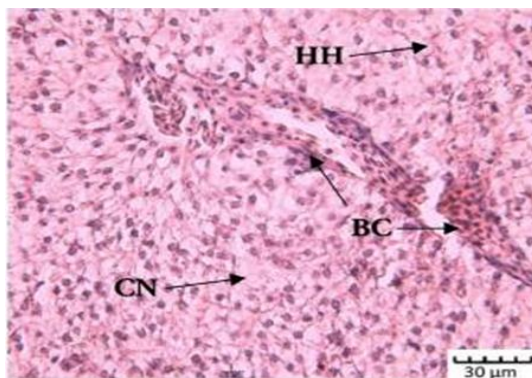


Figure 5: Liver tissue of *Rutilus caspicus* exposed to 150.00 mg L⁻¹ MTBE after 14 days. H&E. Bar: 30µm; Hepatocyte Hypertrophy (HH), Cellular Necrosis (CN), Blood Congestion (BC).

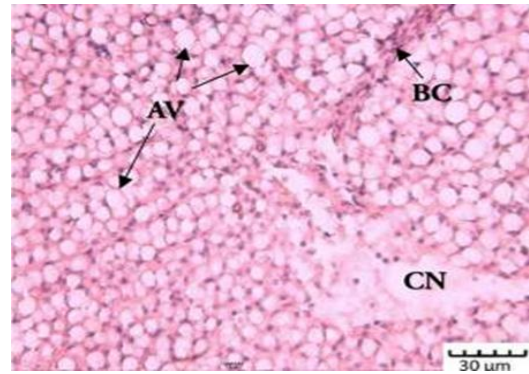


Figure 6: Liver tissue of *Rutilus caspicus* exposed to 150.00 mg L⁻¹ MTBE after 21 days. H&E. Bar: 30µm; Cellular Necrosis (CN), Blood Congestion (BC), acute vacuolation (AV).

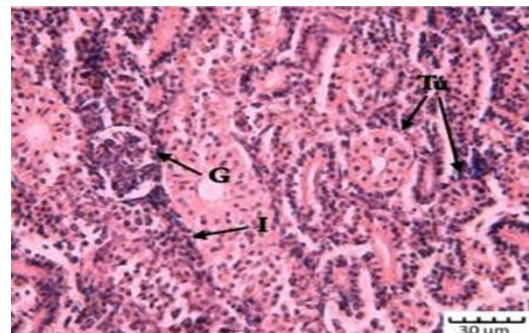


Figure 7: Normal kidney tissue of *Rutilus caspicus* exposed to 0.00 mg L⁻¹ MTBE. H&E. Bar: 30µm; showing the glomerules and the Bowman's space well defined (G) tubules (Tu), interstitial hematopoietic tissue (I).

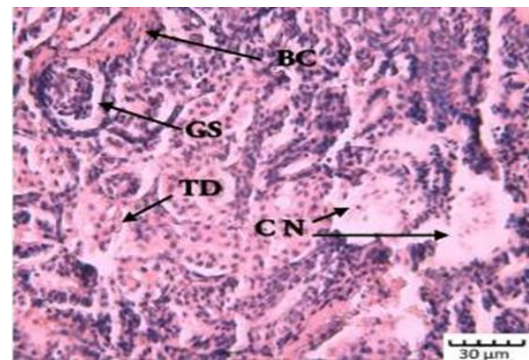


Figure 8: Kidney tissue of *Rutilus caspicus* exposed to 50.00 mg L⁻¹ MTBE after 21 days. H&E. Bar: 30µm; tubular degeneration (TD), glomerular shrinkage (GS), blood congestion (BC), cellular necrosis (CN).

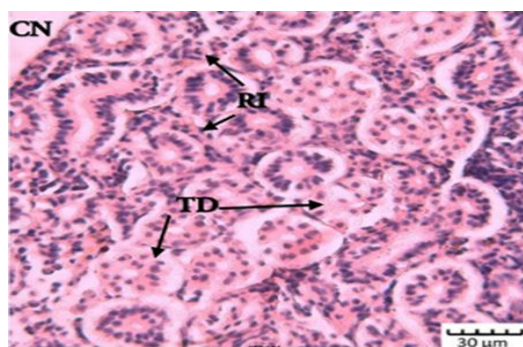


Figure 9: Kidney tissue of *Rutilus caspicus* exposed to 100.00 mg L⁻¹ MTBE after 14 days. H&E. Bar: 30µm; tubular degeneration (TD), reduction in interstitial hematopoietic tissue (RI), (cellular necrosis (CN)).

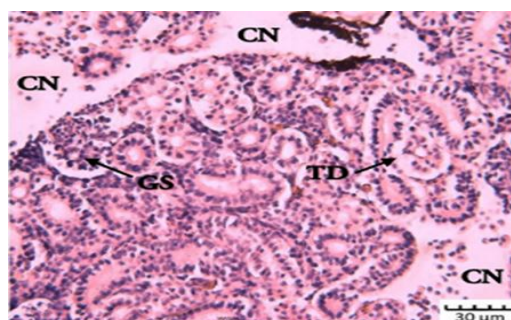


Figure 12: Kidney tissue of *Rutilus caspicus* exposed to 150.00 mg L⁻¹ MTBE after 21days. H&E. Bar: 30µm; glomerular shrinkage (GS), cellular necrosis (CN), tubular degeneration (TD).

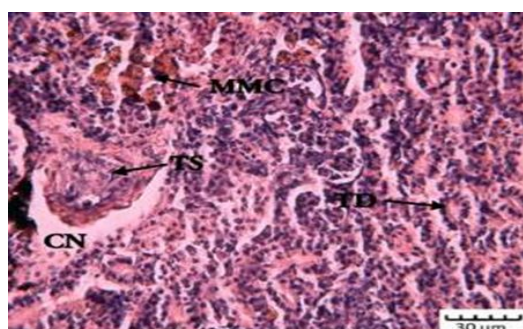


Figure 10: Kidney tissue of *Rutilus caspicus* exposed to 100.00 mg L⁻¹ MTBE after 21 days. H&E. Bar: 30µm; melano macrophage center (MMC), cellular necrosis (CN), tubular shrinkage (TS), tubular degeneration (TD).

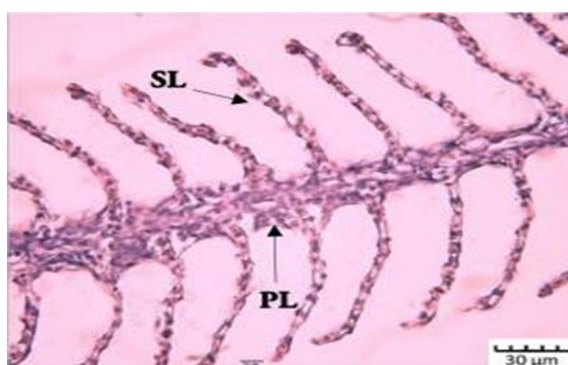

Figure 13: Normal Gill tissue of *Rutilus caspicus* exposed to 0.00 mg L⁻¹ MTBE. H&E.Bar: 30 µm; showing primary lamellae (PL), secondary lamellae (SL).

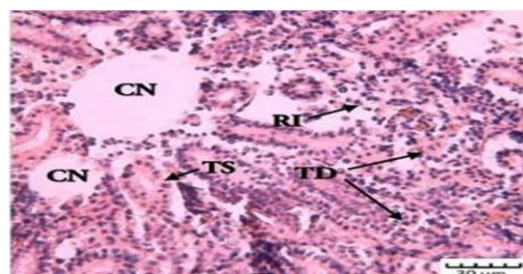


Figure 11: Kidney tissue of *Rutilus caspicus* exposed to 150.00 mg L⁻¹ MTBE after 14 days. H&E. Bar: 30µm; tubular degeneration (TD), reduction in interstitial hematopoietic tissue (RI), tubular shrinkage (TS) , cellular necrosis (CN).

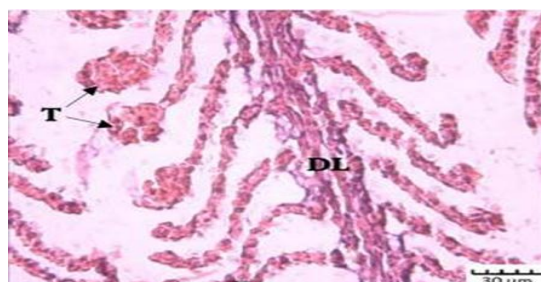


Figure 14: Gill tissue of *Rutilus caspicus* exposed to 50.00 mg L⁻¹ MTBE after 21 days. H&E. Bar: 30µm; lifting (L), hyperplasia (H).

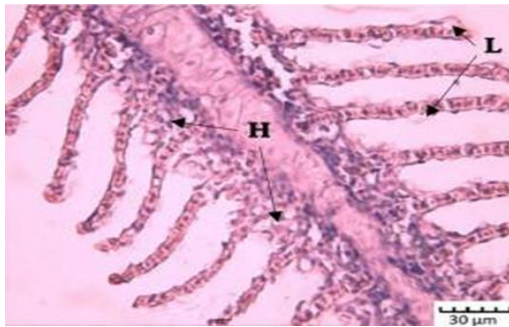


Figure 15: Gill tissue of *Rutilus caspicus* exposed to 100.00 mg L⁻¹ MTBE after 14 days. H&E. Bar: 30µm; telangiectasis at the secondary lamellae (T), degeneration in primary lamellae (DL).

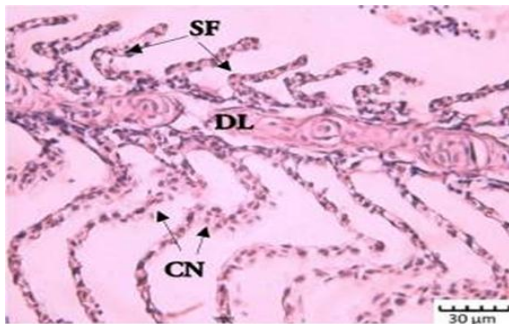


Figure 16: Gill tissue of *Rutilus caspicus* exposed to 100.00 mg L⁻¹ MTBE after 21 days. H&E. Bar: 30µm; S formation of lamellae (SF), degeneration in primary lamellae (DL), cellular necrosis (CN).

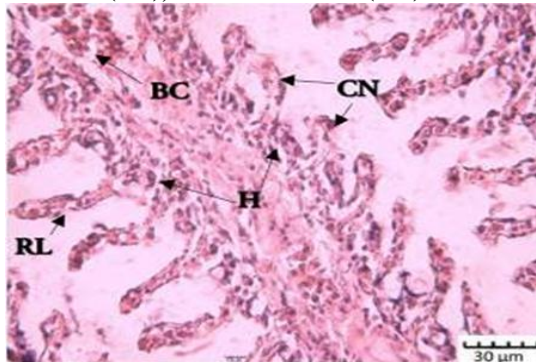


Figure 17: Gill tissue of *Rutilus caspicus* exposed to 150.00 mg L⁻¹ MTBE after 14 days. H&E. Bar: 30µm; reduction in length of secondary lamellae (RL), hyperplasia (H), blood congestion (BC), cellular necrosis (CN).

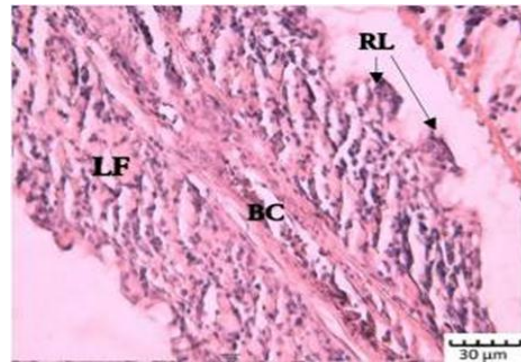


Figure 18: Gill tissue of *Rutilus caspicus* exposed to 150.00 mg L⁻¹ MTBE after 21 days. H&E. Bar: 30µm; reduction in length of secondary lamellae (RL), lamellar fusion (LF), blood congestion (BC).

Acknowledgements

The authors would like to acknowledge the personnel at the *Rutilus caspicus* Fish Reproduction and Breeding Center, Turkaman Harbor, Golestan Province and especially Mr. Shakiba and also the staff of Razi laboratory, Science and Research Branch, Islamic Azad University, Tehran, their cooperation..

References

- Alazemi, B.M., Lewis J.W. and Andrews E.B., 1996. Gill damage in the freshwater fish, *Gnathonemus ptersii* (Family: Mormyridae) exposed to selected pollutants: an ultrastructural study. *Environmental Technology*, 17, 225-238.
- Aghaie, R., Radmehr, B. and Pousti, I., 2012. A study on the role of methyl tertiary butyl ether (MTBE) in producing congenital defects, anatomical deformities of skeleton and histopathological changes in liver and kidney in rat fetal. *Annals of Biological Research*, 3(6), 2673-2681.

- Afzali, F.; Sharif pour, I.; Soltani, M.; Abtahi, B., 2010.** Study of liver, kidney and gill tissue changes of rainbow trout (*Oncorhynchus mykiss*) due to *Aquagerm* bathing. *Journal of Renewable Natural Resources Research*, 1(1), 63-70.
- Al-Sahhaf, Z. A., 2012.** Methyl tertiary butyl ether inhalation induced biochemical and Histological alterations in rabbits. *Journal of Applied Pharmaceutical Science*, 2(12), 071-075.
- Bonventre, J.A., White, L.A. and Cooper, K.R., 2015.** Methyl tert butyl ether targets developing vasculature in zebrafish (*Danio rerio*) embryos. *Aquatic Toxicology*, 105, 29-40.
- Braunbeck, T. and Volkl, A., 1993.** Toxicant induced cytological alterations in the fish liver as biomarkers of environmental pollution? A case study on hepatocellular effects of dinitro-o-cresol in golden ide *Leuciscus idus melanotus*. In: *Fish Ecotoxicology and Ecophysiology*. Proceedings of an International Symposium, Heidelberg, September 1991. (Eds.) T. Braunbeck, W. Hanke, and H. Segner. VCH Verlagsgesellschaft mbH. Weinheim.
- Dutta, H.M., Munshi, J.S.D., Roy, P.K., Singh, N.K., Adhikari, S. and Killius, J., 1996.** Ultrastructural changes in the respiratory lamellae of the catfish, *Heteropneustes fossilis*, after sublethal exposure to malathion. *Environmental Pollution*, 92(3), 329-341.
- Eghdami, M., Oryan S.H. and Nazarhaghghi F., 2014.** Changes in gill structure of the goldfish (*Carassius auratus*) during sub-chronic exposure to organic pollutants. *Aquatic Physiology and Biotechnology*, 1(2), 71-80 (In Persian).
- Fanta, E., Rios, F.S., Romao, S., Vianna, A.C.C. and Freiburger, S., 2003.** Histopathology of the fish *Corydoras paleatus* contaminated with sublethal levels of organophosphorus in water and food. *Ecotoxicology and Environmental Safety*, 54, 119-130.
- Gernhofer, M., Pawet, M., Schramm, M., Müller, E. and Triebkorn, R., 2001.** Ultrastructural biomarkers as tools to characterize the health status of fish in contaminated streams. *Journal of Aquatic Ecosystem, Stress and Recovery*, 8, 241-260.
- Ghovati, N., Mohammadi, S. and Mohammadi, V., 2011.** Compare and analyze the changes in hardness and alkalinity of the common carp with heavy metal poisoning. (*Cyprinus carpio*). *Journal of Wetlands, Islamic Azad University Ahvaz, second year*, 8, 21-28 (In Persian).
- Heath, A.G., 1987.** Water pollution and fish physiology. CRC Press, Florida. 5(12), 384.
- Heidari Jamebozorgi, F., 2009.** The effect of pollution soluble crude oil on the liver, gill and all your gold fish White Sea. End a Master of Science, Tarbiat Modarres University, 75 P.

- Hernando, M.D., Ejerhoon, M., Fernández-Alba, A.R. and Chisti, Y., 2003.** Combined toxicity effect of MTBE and pesticides measured with *Vibrio fischeri* and *Daphnia magna* bioassays. *Water Research*, 37, 4091-4098.
- Hinton, D.E. and Lauren, D.J., 1990.** Liver structural alterations accompanying chronic toxicity in fishes: potential biomarkers of exposure. In: *Biomarkers of Environmental Contamination* (Eds.), pp. 17-52. J.F. McCarthy and L.R. Shugart. Lewis Publishers.
- Hoseini, S.M. and Nodeh, A.J., 2012.** Toxicity of copper and mercury to Caspian roach *Rutilus rutilus caspicus*. *Journal of the Persian Gulf*, 3(9), 9–14.
- Huarong, G., Licheng, Y., Shicui, Z. and Wenrong, F., 2010.** The toxic mechanism of high lethality of herbicide butachlor in marine flatfish flounder (*Paralichthys olivaceus*). *Oceanic and Coastal Sea Research*, 9, 257-264.
- Johnson, R., Pankow, J., Bender, D., Price, C. and Zogorski, J., 2000.** MTBE: to what extent will past releases contaminate community water supply wells? *Environmental Science and Technology*, 34, 210.A–217.A.
- Khalili, L., Gholami, S. and Ansari-Lari, M., 2015.** Evaluation of offspring sex ratio, sex hormones and Enzymes following exposure to methyl tertiary butyl ether in adult male Sprague-Dawley rats. *EXCLI Journal*, 14, 75-82.
- Mallatt, J., 1985.** Fish gill structural changes induced by toxicants and other irritants; a statistical review. *Canadian Journal of Fisheries and Aquatic Sciences*, 42, 630-648.
- Mela, M., Ventura, D.F., Randi, M.A.F. and Carvalho, C.E.V., 2007.** Effects of dietary methylmercury on liver and kidney histology in the neotropical fish *Hoplias malabaricus*. *Ecotoxicology and Environmental Safety*, 68, 426-435.
- Mihaich, E., Steffen, E., Gerald Le, B. and Sean, G., 2015.** Short-term fish reproduction assays with methyl tertiary butyl ether with zebrafish and fathead minnow: Implications for evaluation of potential for endocrine activity. *Toxicology and Chemistry*, 34, 2013–2022.
- Naddafi, K., Nabizadeh, R. and Baiggi, A., (2008).** Bioassay of methyl tertiary-butyl ether (MTBE) toxicity on rainbow trout fish. *Journal of Hazardous Materials*, 154, 403-406.
- Pacheco, M. and Santos, M.A., 2002.** Biotransformation, genotoxic and histopathological effects of environmental contaminants in European eel, *Anguilla anguilla* L. *Ecotoxicology and Environmental Safety*, 53, 331-347.
- Peebuaa, P., Kruatrachuea, M., Pokethitiyooka, P. and Kosiyachindaa, P., 2006.** Histological Effects of Contaminated Sediments in Mae Klong River Tributaries, Thailand, on Nile tilapia, *Oreochromis niloticus*. *Science Asia*, 32, 143-150.

- Poosti, A. and Seddigh Marvasti, A., 1999.** Atlas of fish histology. *Tehran University Press*, 252, 149-165.
- Rezvani Gil-kellay, S., Sharifpour, I. and Kazemi, R., 2006.** Effects histopathological due to some biological factors Caspian Sea environment on bony fishes hunter (salmon and sea perch Caspian). Iranian Fisheries Research Institute. 50 P.
- Ribeiro, C., Vollaie, Y., Sanchez-Chardi, A. and Roche, H., 2005.** Bioaccumulation and the effects of organochlorine pesticides, PAH and heavy metals in the eel (*Anguilla anguilla*) at the Camargue Nature Reserve, France. *Aquatic Toxicology*, 74, 53-69.
- Roberts, R.J. and Rodger, H.D., 2001.** Pathophysiology and systematic pathology. In: Roberts RJ (ed) Fish pathology, 3rd edn. WB Saunders, London, pp. 55–132.
- Santos, T.C.A., Ngan, P.V., Gomes, V., Passos, M.J.A.C.R. and Campos, D.Y.F., 2011.** Histological alterations in the gills of *Trachinotus carolinus* (Carangidae). *Pan-American Journal of Aquatic Sciences*, 6(2), 109-120.
- Shahsavani, D. and Movassaghi, A., 2002.** Fish systemic pathology. Publishers Ferdowsi University of Mashhad, 400 P.
- Sharifpour, I., Soltani, M., Abdolhay, H. and Ghaiyoomi, R., 2002.** The effect of anesthetic *Eugenia caryophyllata* in the different conditions pH and temperature in the baby fish Common carp. *Journal of Fisheries Iran*, 4(11).
- Taiwo, V.O., Olukunle, O.A., Ozor, I.C. and Oyejobi, A.T., 2005.** Consumption of aqueous extract of raw, *Aloe Vera* leaves: histopathological and biochemical studies in rat and tilapia. *African Journal of Biomedical Research*, 8, 169-178.
- Takashima, F. and Hibiya, T., 1995.** An atlas of fish histology. Normal and pathological features. 2nd ed. Tokyo, Kodansha Ltd.
- Thophon, S., Kruatrachue, M., Upathan, E.S., Pokethitiyook, P., Sahaphong, S. and Jarikhuan, S., 2003.** Histopathological alterations of white seabass, *Lates calcarifer* in acute and subchronic cadmium exposure. *Environmental Pollution*, 121, 307-320.
- USEPA, 1998.** MTBE fact sheet 1: overview. EPA 510-F-97-014, US. EPA, Office of Solid Waste and Emergency Response, Washington, DC.
- Van der Oost, R., Beyer, J. and Vermeulen, N.P.E., 2003.** Fish bioaccumulation and biomarkers in environmental risk assessment: *Environmental Toxicology and Pharmacology*, 13, 57-149.
- Werner, I., Kojer, C.S., Deanovic, L.A. and Hinton, D.E., 2001.** Toxicity of methyl-tert-butyl ether to freshwater organisms. *Environmental Pollution*, 111, 83-88.