

Light and electron microscope studies of grass carp (*Ctenopharyngodon idella*) organs following exposure to various sublethal concentrations of diazinon

I. Sharifpour^{1*}; R. Pourgholam¹; M. Soltani²;
M.D. Hassan³; S. Akbari⁴ and A. Nouri⁵

issasharifpour@yahoo.com

- 1- Iranian Fisheries Research Organization, P.O.Box: 14155-6116 Tehran, Iran
- 2- Dept. of Aquatic Animal Diseases and Health, Faculty of Veterinary Medicine, University of Tehran, P.O.Box: 14155-6453 Tehran, Iran.
- 3- Aquatic Animal Health Unit, Dept. of Veterinary Clinical Studies, Faculty of Veterinary Medicine, University of UPM, Serdang, Malaysia.
- 4- Faculty of Veterinary Medicine, University of Shiraz, Shiraz, Iran.
- 5- Razi Institute of Vaccine and Serum Research, Karaj, Iran.

Received: July 2005

Accepted: November 2005

Abstract: Histopathological effects of different sublethal concentrations (1, 2 and 4 mg/l) of diazinon, an organophosphorus pesticide, on gill, liver, spleen and kidney of grass carp (*Ctenopharyngodon idella*) were studied after 1, 7, 15, 30 and 45 days post-exposing fishes weighting 850 ± 155 g to the toxicant for 12 hours at 18-22°C. In addition, tissues of nostril were examined for transmission electron microscopy and scanning electron microscopy. Results of light microscopic examinations of tissues showed that toxicant was causing severe histopathological effects such as congestion of blood vessels, haemorrhage, cellular infiltration, pyknosis of cells nuclei, vacuolar degeneration and general necrosis in the kidney, spleen and liver. There were also degenerative changes of interstitial tissue and detachment of tubular basement membrane in kidney observed. Hyperplasia and fusion of secondary

* Corresponding author

lamellae, separation and sloughing of epithelium from the underlying basement membrane were also observed in gill sections. Transmission electron microscopy (TEM) examination of nostril revealed, damages of epithelial cells (vacuolated club cells and abnormality in cells' nuclei). Scanning electron microscopy (SEM) examination of nostril showed a reduction in excretion of amorphous proteinous materials, reduction in vesicle numbers on the cell surface and also closing of cell surface canals.

Keywords: Grass carp (*Ctenopharyngodon idella*), diazinon, histopathology, TEM, SEM

Introduction

Pesticide contamination of surface waters from agricultural activities is a problem of worldwide importance (Tsuda *et al.*, 1997). Industrial discharges, runoff from farms, especially insecticides, city effluents and other contaminants of human origin are important pollutants present in the aquatic environment and thus unavoidable by fish (Cross *et al.*, 1985; Tsuda *et al.*, 1990; Sheipline, 1993; Bailey *et al.*, 1997; Talebi, 1998; Eisler, 2000). Insecticides are commonly employed in agriculture and their toxicity to different groups of vertebrates has been widely studied (e.g. Keizer *et al.*, 1991; Alam & Maughen, 1992; Sancho *et al.*, 1992; Tsuda *et al.*, 1997; Khalaf-Allah, 1999; Bailey *et al.*, 2000).

Diazinon[O-O-diethylO-(2-isopropyl-6-methyl-4-pyrimidinyl) Phosphorothioate] is a widely used organophosphorus pesticide around the world, especially in rice paddy fields. It is used extensively to control flies, lice, insect pests of ornamental plants and food crops, as well as nematodes and soil insects in lawns and croplands. Diazinon degrades rapidly in the environment, with half-life persistence usually less than 14 days. However, under some conditions such as low temperature, low moisture, high alkalinity and lack of suitable microbial degraders, it may remain biologically active in soil for up to 6 months. Toxic action of the toxicant in fish is based on its ability specifically to inhibit activity of acetylcholine in nervous synapses resulting in dystrophic changes both destruction of nervous cells and

hypoxia induction (Keizer *et al.*, 1995; Tsuda *et al.*, 1997; Hamm *et al.*, 1998; Eisler, 2000).

Results of a number of studies show that such toxic chemicals can affect fish health conditions at various levels, including fish immune system resulting in an increase in fish susceptibility to infectious diseases (e.g. Keizer *et al.*, 1991,1993; Sancho *et al.*, 1993,1997; Tsuda *et al.*, 1997; Bailey *et al.*, 2000; Svoboda *et al.*, 2001; Luskova *et al.*, 2002). It is also well known that natural waters and sediments where fish live can be significantly contaminated by pesticides and other industrial chemicals, affecting fish immune system (Anderson & Zeeman, 1995).

In the present study histopathological changes of gill, kidney, spleen, liver and nostril of grass carp (*Ctenopharyngodon idella*), were studied using light and electron microscopy, following a short term exposure to various sublethal concentrations of diazinon.

Materials and methods

1. Fish

One hundred and twenty grass carps, weighing 850 ± 155 g from one fish farm in north of Iran were used. Fishes were held in 1200 L tanks receiving a constant supply of fresh water. The experiments were initiated after 4 days of acclimation. Twelve tanks were stocked with 10 fishes in each. Fishes were fed with fresh vegetables consisting of lucerne grass, clover and lettuce. Water quality parameters, water temperature, dissolved oxygen and pH were maintained at 18-22°C, 7.7mg /L and 7.5, respectively.

2. Diazinon application

Fishes of each tank received diazinon at concentrations of 1, 2 and 4mg/L in 3 replicate for 12 hours at 20-22°C and then were transferred to clean water. Control group were kept in clean water separately.

3. Collection and processing of samples

Samples were collected after 1, 7, 15, 30 and 45 days post-exposure to the toxicant. Five fishes per treatment were collected at each sampling time. Tissues of gill, spleen, liver and kidney were sampled for histopathological study. In addition, tissues of nostril were sampled for electron microscopy studies.

4. Light microscopic examination

At each sampling time, tissues of gill, spleen, liver and kidney were immediately removed and fixed in cold 10 % buffered formalin for at least 24 hours before processing in an automatic tissue processor using standard procedure (Roberts, 2001). The 5 μ m sections obtained from the paraffin embedded blocks were stained using Haematoxylin & Eosin staining and examined under compound microscope.

5. Electron microscopic examination

a) Scanning electron microscopy (SEM)

The SEM was carried out according to air-drying procedure as described by Bozzola and Russell (1999). The processed samples were mounted on an SEM stub in vacuum and were coated with gold to get 10 nm coats in coater (E5200 Auto sputter coater) for 5 minutes. The stubs were then examined under SEM (STEROSCAN 360).

b) Transmission electron microscopy (TEM)

The TEM was carried out according to the method described by Robards and Willson (1993). The sections were prepared, transferred to the grid, stained with uranium acetate for 20 minutes, and then washed with lead citrate. The dried sections at room temperature were examined under Philips 400 transmission electron microscopy.

Results

a) Light microscopy

Histopathological findings by light microscopy are summarized in tables 1-4. Congestion of blood vessels, haemorrhage, increasing of melanomacrophage centres, separation of connective tissue, vacuolative degeneration in splenic pulp, pyknosis of nuclei of immunocompetent cells, haemosidrosis, necrosis of ellipsoids and general necrosis of tissue were seen in the spleen (Figs. 1&2).

Congestion of blood vessels, haemorrhage, inflammatory cells infiltration, increasing of melanomacrophage centres, general necrosis of tissue, vacuolar degeneration, karyolysis and pyknosis of cells' nuclei were recorded from kidney sections (Figs. 3&4).

Congestion of blood vessels, haemorrhage, degenerative changes of hepatocytes, sinuses dilation, pyknosis of hepatic cells, degeneration of bile ducts, focal and general necrosis of hepatocytes were observed in the liver (Figs. 5-8).

Congestion and dilation of blood vessels, mild inflammatory cells infiltration, increasing in lymphocytes number, swelling, separating and sloughing of the basement membrane of lamellae, hyperplasia, fusion and also necrosis of secondary lamellae were the changes seen in the gill (Figs. 9 &10).

Table 1: Histopathological findings of grass carp spleen exposed to various sublethal concentrations of diazinon at 20-22°C.

Sampling days (post exposure)	Histopathological changes parameters	Concentrations of diazinon (mg/l)		
		1	2	4
1	Congestion of blood vessels	++	++	+++
	Haemorrhage	-	-	++
	Increasing melanomacrophage centres	-	-	+
	Pyknosis of nuclei in white pulp	-	-	+
7	Congestion of blood vessels	+	++	++
	Increasing melanomacrophage centres	+	++	++
	Pyknosis of nuclei of immunocompetent cells	+	++	++
15	Congestion of blood vessels	+	+	+
	Increasing melanomacrophage centres	+	++	++
	Necrosis of spleen ellipsoids	+	+	++
	General necrosis of spleen tissue	+	+	++
30	Haemosidrosis	+	+	+
	Increasing melanomacrophage centres	+	++	++
	General necrosis of spleen tissue	+	+	++
45	Haemosidrosis	+	+++	+++
	General necrosis of spleen tissue	+	+++	+++
	Congestion of blood vessels	+	-	-
	Increasing melanomacrophage centres	+	++	++

- = no significant microscopic changes

+ = mild changes (10 percent changes in 40x objective microscope view)

++ = moderate changes (20 percent changes in 40x objective microscope view)

+++ = severe changes (more than 20 percent changes in 40x objective microscope view)

Table 2: Histopathological findings of grass carp kidney exposed to various sublethal concentrations of diazinon at 20-22°C.

Sampling days (post exposure)	Histopathological changes parameters	Concentrations of diazinon (mg/l)		
		1	2	4
1	Congestion of blood vessels	+	++	++
	Haemorrhage	-	+	++
	Cellular infiltration	-	+	++
	Increasing melanomacrophage centres	-	-	+
	General necrosis of kidney tissue	+	++	+++
7	Pyknosis of kidney cells nuclei	+	++	+++
	Vacuolar degeneration of kidney cells nuclei	+	++	+++
	General necrosis of kidney tissue	++	+++	+++
		+		
15	Karyolysis and pyknosis of cells nuclei	+	++	+++
	General necrosis of kidney tissue	+	++	+++
30	Pyknosis of different types of kidney cells nuclei	+	+++	+++
	General necrosis of kidney tissue	+	+++	+++
45	—			

- = no significant microscopic changes

+ = mild changes (10 percent changes in 40x objective microscope view)

++ = moderate changes (20 percent changes in 40x objective microscope view)

+++ = severe changes (more than 20 percent changes in 40x objective microscope view)

Table 3: Histopathological findings of grass carp liver exposed to various sublethal concentrations of diazinon at 20-22°C.

Sampling days (post exposure)	Histopathology changes parameters	Concentrations of diazinon (mg/l)		
		1	2	4
1	Congestion of blood vessels	+++	-	-
	Haemorrhage	+	-	-
	Sinuses dilation	-	++	++
	Vacuolar degeneration of hepatocytes	-	+++	+++
	General necrosis of hepatocytes	-	+	++
7	Congestion of blood vessels	+++	+	+
	Pyknosis of hepatic cells	+++	+++	+++
	Cloudy swelling	+++	++	++
	Focal necrosis	-	++	-
	General necrosis of hepatocytes	-	++	+++
15	Congestion of blood vessels	++	++	+
	Sinus dilation	+	++	+++
	Pyknosis of hepatic cells	+	++	+++
	Degeneration of bile ducts	-	-	++
	General necrosis of hepatocytes	+	++	+++
30	Congestion of blood vessels	+	+	++
	Sinus dilation	++	++	++
	Pyknosis of hepatic cells	+	+	++
	Degeneration of bile ducts	-	-	++
	General necrosis of hepatocytes	-	++	+++
45	Congestion of blood vessels	+	+	+
	Pyknosis of hepatic cells	+	++	++
	Vacuolar degeneration in hepatic cells	-	++	-
	Focal necrosis of hepatocytes	+	++	+++
	General necrosis of hepatocytes	+	++	+++

- = no significant microscopic changes

+ = mild changes (10 percent changes in 40x objective microscope view)

++ = moderate changes (20 percent changes in 40x objective microscope view)

+++ = severe changes (more than 20 percent changes in 40x objective microscope view)

Table 4: Histopathological findings of grass carp gill exposed to various sublethal concentrations of diazinon at 20-22°C.

Sampling days (post exposure)	Histopathological changes parameters	Concentrations of diazinon (mg/l)		
		1	2	4
1	Congestion	+	++	+++
	Dilation of blood vessels	-	+	++
	Mild cellular infiltration	-	+	++
	Swelling of the basement membrane	-	+	++
7	Increasing in lymphocytes number	+	++	+++
	Separating and sloughing of basement membrane	+	++	+++
	Necrosis of lamellae	+++	+++	+++
15	Congestion	++	+	+
	Swelling of the basement membrane	++	++	++
	Hyperplasia and fusion of lamellae	+	++	+++
	Necrosis of lamellae	+++	+++	+++
30	Fusion of lamellae	++	+	+++
	Sloughing of basement membranes of lamellae	++	++	+++
	Necrosis of lamellae	+++	+++	+++
45	—			

- = no significant microscopic changes

+ = mild changes (10 percent changes in 40x objective microscope view)

++ = moderate changes (20 percent changes in 40x objective microscope view)

+++ = severe changes (more than 20 percent changes in 40x objective microscope view)

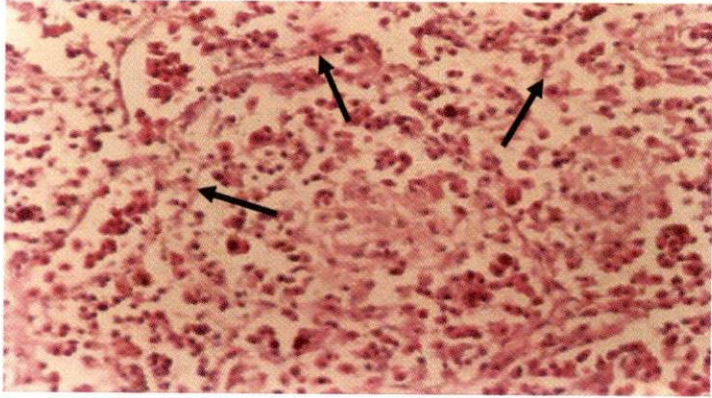


Figure 1: Separation of connective tissue (arrows) seen in the splenic parenchyma at 45 days post exposure to 2 mg/l of diazinon (H&E, x 488).

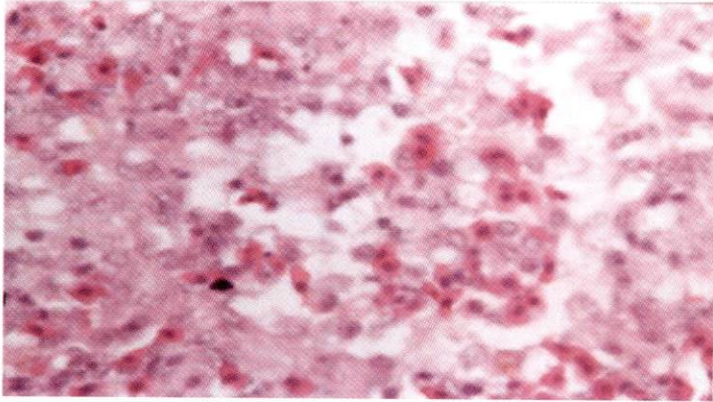


Figure 2: Vacuolar degeneration seen in splenic pulp possibly due to oedema, observed at 45 days post exposure to 2 mg/l of diazinon (H&E, x 740).

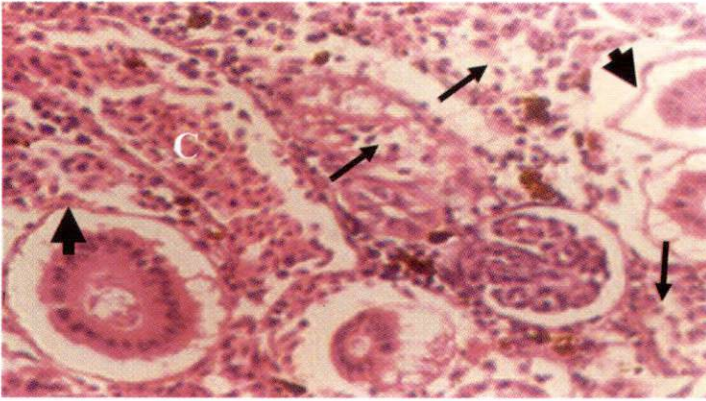


Figure 3: Congestion (C) in kidney's vein, degeneration of interstitial tissue (arrows) and detachment of tubular basement membrane (arrow heads) at 1 day post exposure to 4 mg/l diazinon. (H&E, x 488).

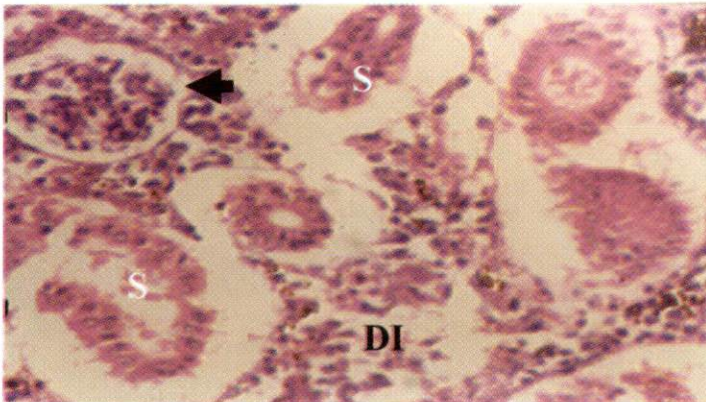


Figure 4: Degeneration of interstitial tissue of kidney (DI), detachment of basement membrane and shrinkage of tubules (S) and necrosis of glomerulus (arrow head) were also seen at 7 days post exposure to 4 mg/l diazinon (H&E, x 488).

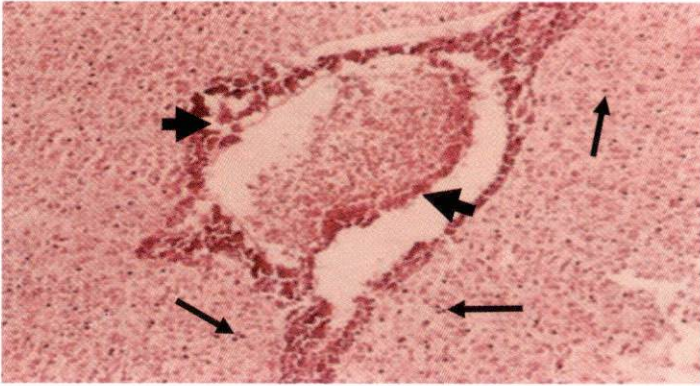


Figure 5: Generalized liver degeneration as indicated by pyknotic nuclei (arrows) in the parenchyma. Also seen hepatopancreas showing loss of structural integrity (arrow heads) in fish exposed to 2 mg/l diazinon at day 30 post exposure (H&E, x 122).

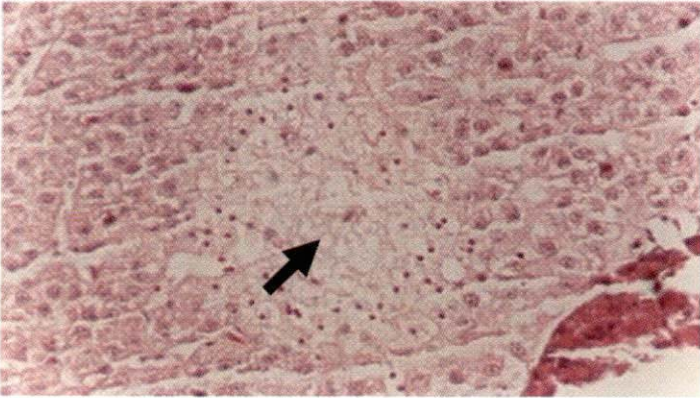


Figure 6: Focal necrosis (arrow) in the liver manifested by the presence of pyknotic cells and pale-staining area, seen at day 45 post exposure to 2 mg/l of diazinon (H&E, x 488).

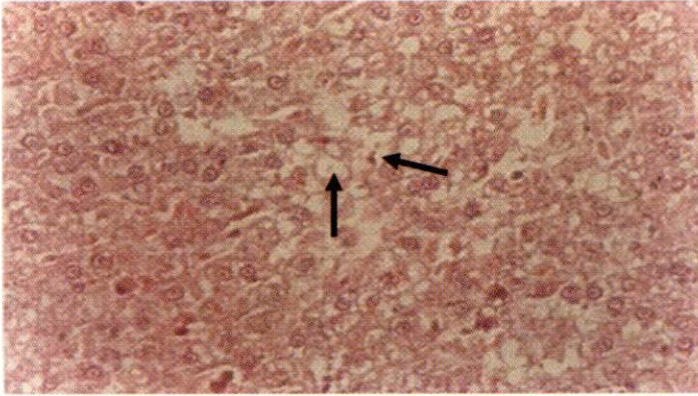


Figure 7: Vacuolar degeneration of hepatocytes (arrows), at day 7 post exposure to 2 mg/l diazinon (H&E, x 488).

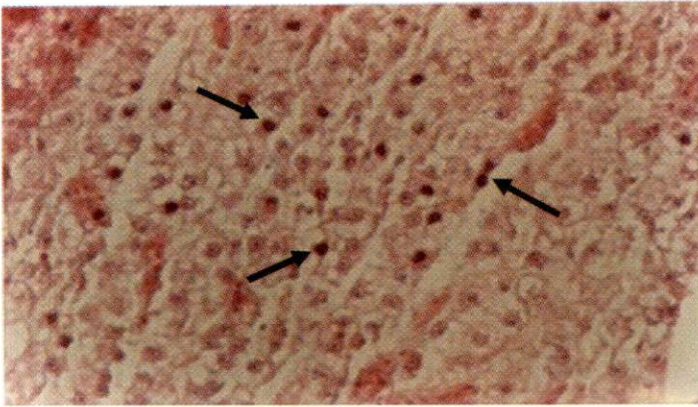


Figure 8: Generalized vacuolar degeneration and pyknosis of hepatocytes nuclei (arrows) at day 7 post exposure to 4 mg/l diazinon (H&E, x 488)

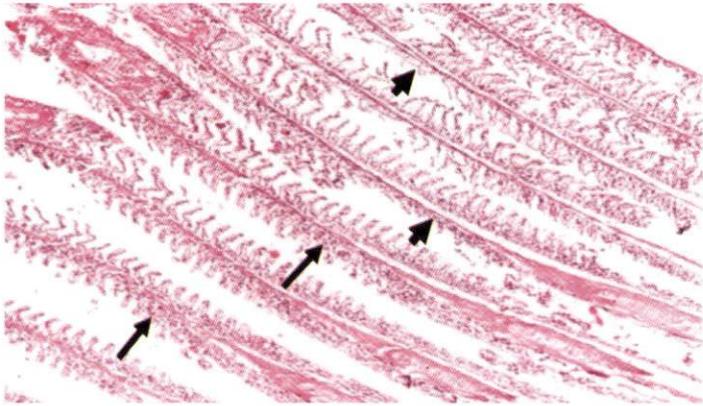


Figure 9: Gill lamellae of grass carp at day 7 after exposure to 2 mg/l diazinon showing proliferation of secondary lamellae (arrows). Separation and sloughing-off epithelium (arrow heads) from the underlying basement are also observed (H&E, x 122).

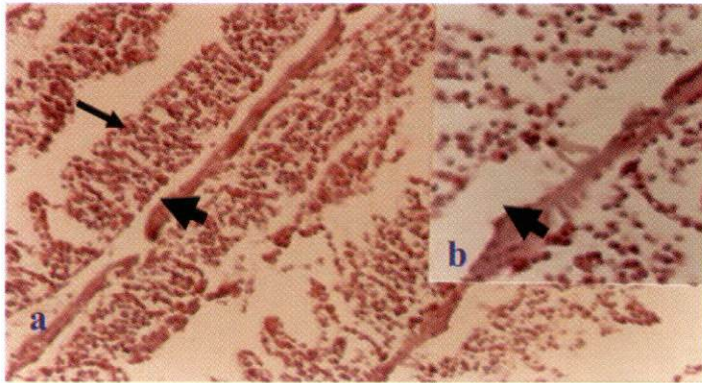


Figure 10: Gill lamellae of grass carp at day 15 after exposure to 2 mg/l diazinon showing hyperplasia and fusion of secondary lamellae (arrow). Separation and sloughing-off epithelium (arrow heads) from the underlying basement are also seen (H&E, a= x 244 and b = x 488).

b) Electron microscope examination

Findings of TEM and SEM examination of nostril tissue which has close contact to the diazinon are shown in figures 11-16. Vacuolation in the cytoplasm of club cells as a secretor cells, and abnormality in cells nuclei were seen with TEM. Increasing in droplet on the cell surface, reduction in excretion of amorphous proteinous materials and vesicles number and also blockage of cell secretion canals (openings) were also observed using SEM.

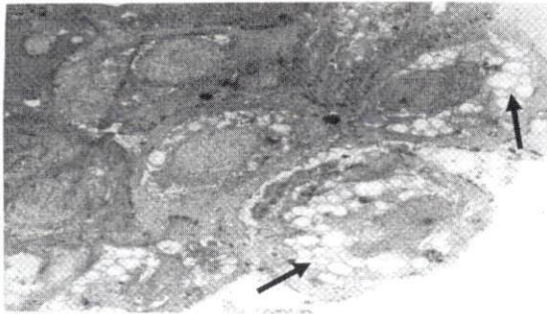


Figure 11: TEM micrograph of vacuolated epithelial cells (arrows) of grass carp's nostril exposed to 4 ppm diazinon at 20-22° C (x 3439).

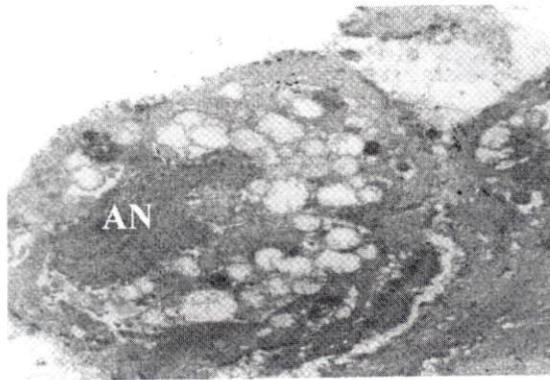


Figure 12: TEM micrograph of vacuolated epithelial cell of grass carp's nostril with abnormal nucleus (AN) (x7410).

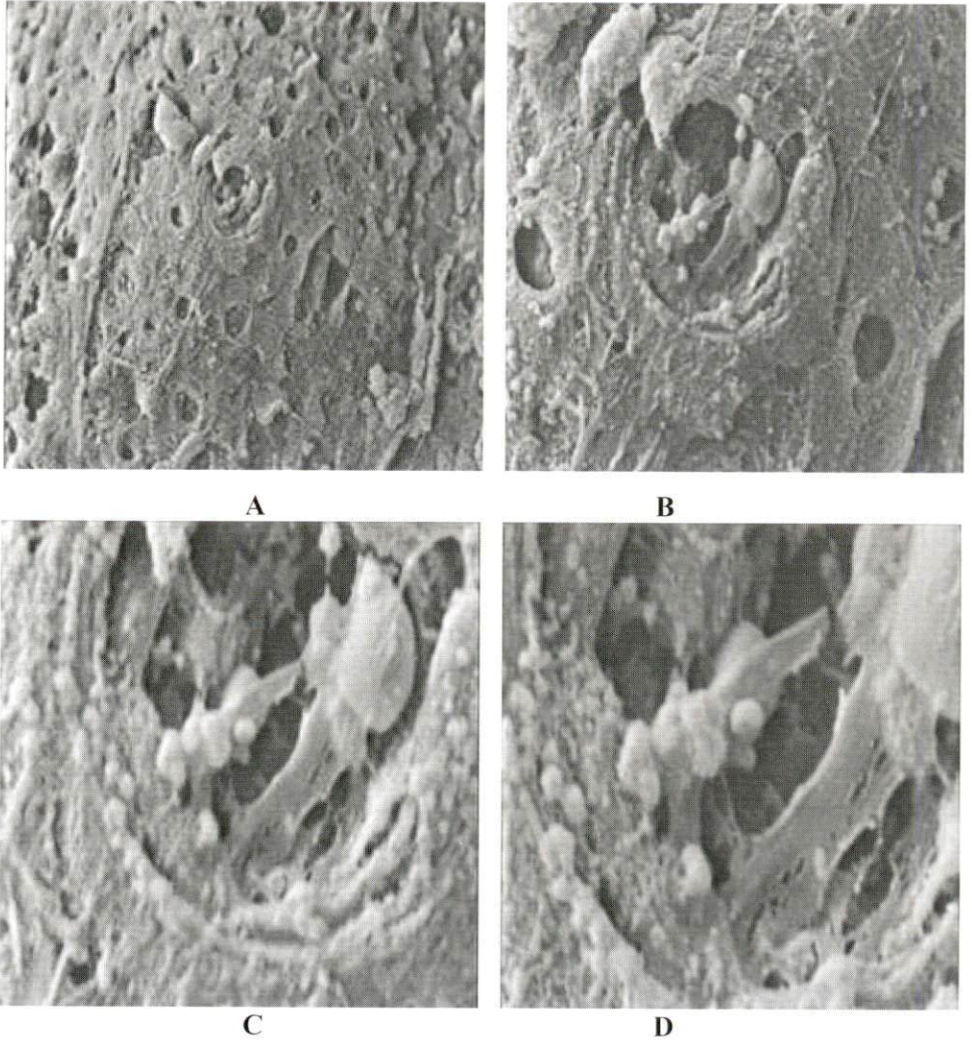


Figure 13: SEM micrographs of nasal epithelial cells of normal grass carp showing amorphous proteinous materials, vesicles and cell secretion canals. A= x 800, B= x 2500, C= 5000, D= x 8000

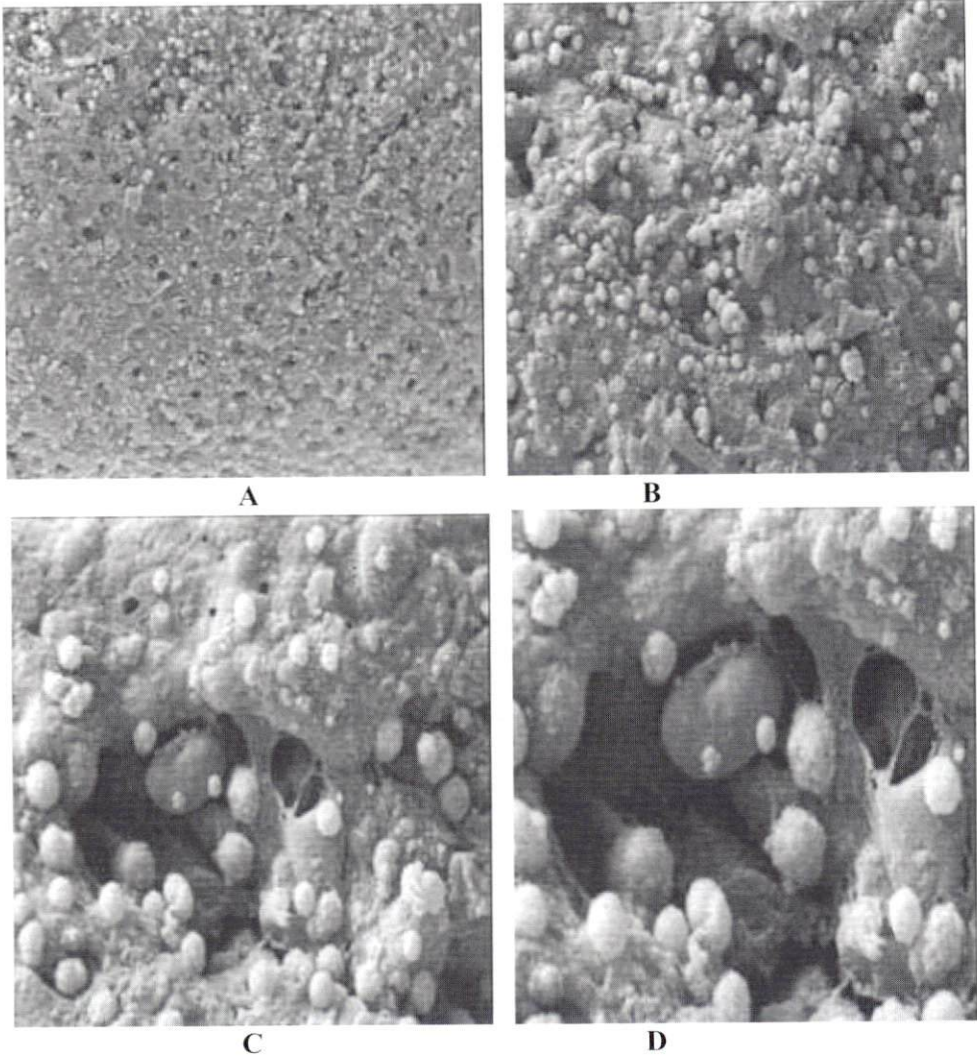


Figure 14: SEM micrograph of nasal epithelial cells of grass carp exposed to 1 ppm diazinon showing an increasing in droplet on the cell surface. A= x 500, B= x 1000, C= x 2500, D= x 5000

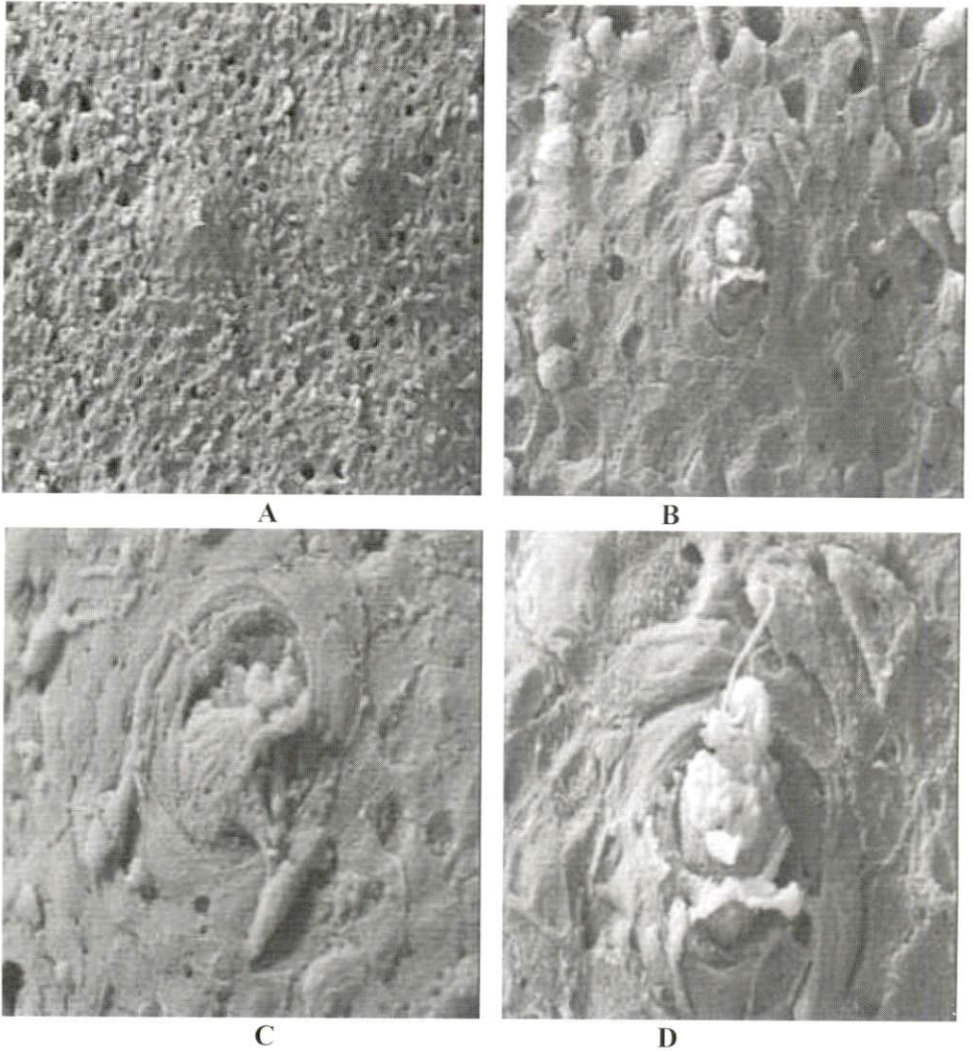


Figure 15: SEM micrograph of nasal epithelial cells of grass carp exposed to 2 ppm diazinon showing a reduction in excretion of amorphous proteinous materials and vesicles number (A, B) as well as blockage of cell secretion canals (C, D).

A= x 800, B= x1000, C= x 1500, D= x 2500

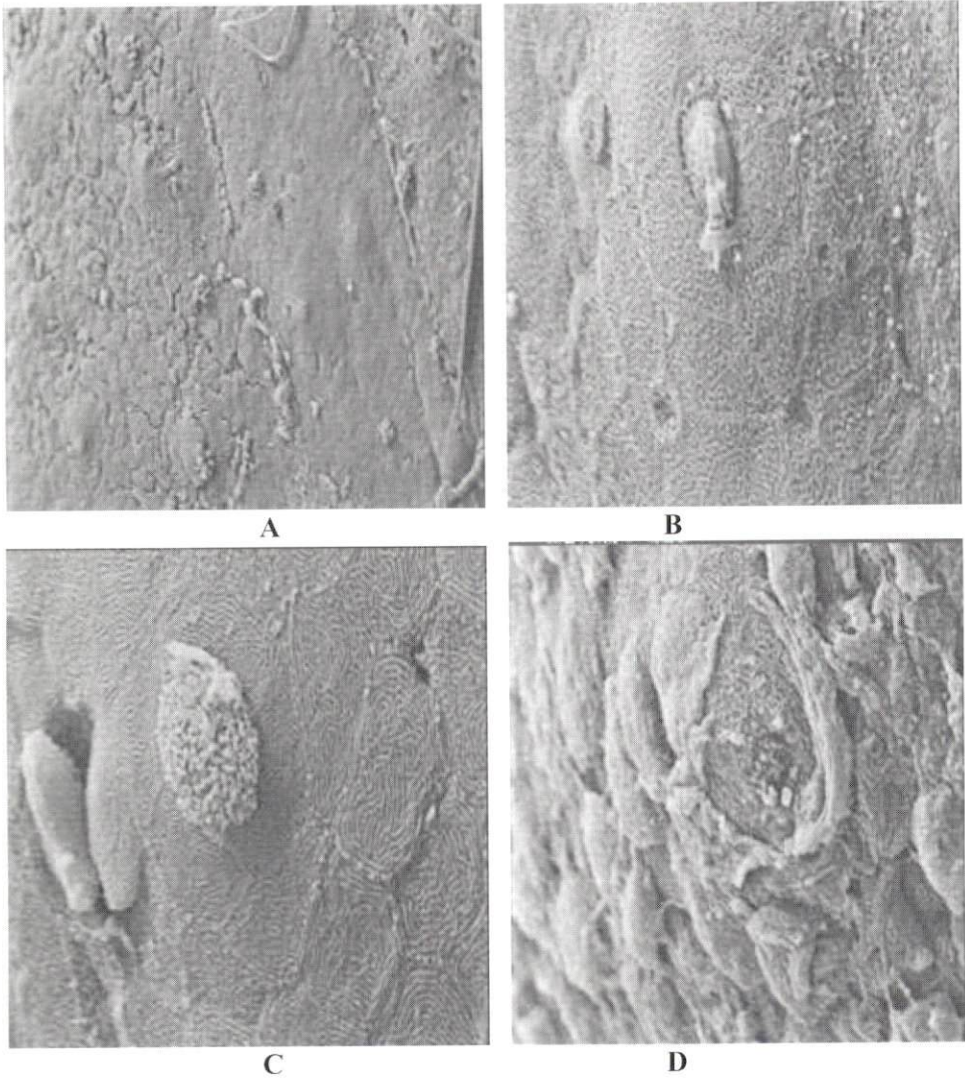


Figure 16: SEM micrograph of nasal epithelial cells of grass carp exposed to 4 ppm diazinon showing a severe reduction in excretion of amorphous proteinous materials and vesicles number (A, B). The cell secretion canals are blocked (C, D).

A= x 250, B= x 2500, C= x 2500, D= x 2600

Discussion

Exposure of grass carp (*Ctenopharyngodon idella*) to 1, 2 and 4mg/L diazinon caused some histopathological changes in fish organs. Congestion and dilation of blood vessels, swelling, separation and sloughing of basement membrane of the secondary lamella were the most common encountered pathological changes in gill sections. It was postulated that congestion of blood vessels and also swelling and lifting of the epithelia and basement membrane could have serve as a defence mechanism in protecting the fish against irritant chemical. Skidmore and Tovell (1972) believed that lifting and swelling of the epithelium serve to increase the distance through which chemical irritants must diffuse to reach blood stream. However, Jagoe and Haines (1983) reported that such phenomenon could adversely affect oxygen uptake by increasing the distances over which respiratory diffusion occurs. However, if the diffusion distance and secretion of mucus increase, it could affect the respiration of the fish, leading to its death (Dutta *et al.* 1993). At higher concentration, hyperplasia, fusion and necrosis of lamellae were particularly remarkable 7 days post exposure. Such histopathological changes have also been reported by other workers using the same chemical on other species of fishes. Gill alterations such as necrosis and rupture of lamellae are believed to be poisoning dose-dependent. The severity of histopathological changes found in this study was toxicant dose-dependent. Necrosis or cell death may be either occurring by autolysis or rapid lyses (Mallatt, 1985). Autolysis is caused by enzymes in the cell itself in response to the disruption of cell activities. Rapid lyses occur by direct lyses of cell components by chemical irritants (Abel, 1976). However, gill disorders observed in the present study may result in physiological disorder, which could ultimately lead to the death of fish.

Histopathological study of liver sections showed a congestion of blood vessels and sinuses dilation almost in all experiments. This could be considered as a defence mechanism of fish to dilute the poison in blood and to boost the immune

system. The hepatocytes have undergone different stages of degeneration before the complete necrosis. This result shows that hepatocytes are quite sensitive to diazinon. Klaassen and Warkins (1984) believe that toxin which enter the liver via the hepatic portal vein are removed by a process known as presystemic hepatic elimination, which eliminates toxins during a single pass through the liver under optimal conditions. This process prevents, or at least minimizes, the distribution of foreign chemicals to other parts of the body. The histopathological changes of grass carp liver exposed to diazinon in this study were similar to those reported by Rahman *et al.* (2002), in fish species such as *Anabas testudineus*, *Channa punctatus* and *Barbodes gonionotus* exposed to diazinon. Kabir and Begum (1978) had also reported histopathological changes such as cytoplasmic degeneration, pyknotic nuclei in liver tissues, vacuolation in hepatic cells and rupture of blood vessels, degenerative hepatic cells and necrotic nuclei when *Heteroneutes fossilis* was exposed for 25 days to 5, 10 and 20 ppm diazinon.

The kidney as a mixed organ comprising haemopoetic, reticuloendothelial, endocrine and excretory elements is one of the most important defensive organs of fish (Roberts, 2001). In this study, congestion and haemorrhage were observed in the early stages of exposure, which could have been due to the toxicant effect on the blood vessels wall, resulting in diapedesis of blood. Tubular and haematopoietic cells degeneration, vacuolation, pyknosis and karyolysis of nuclei, necrosis of the kidney hematopoietic tissue and, to some extent, cellular infiltration in intercellular spaces of the tissue were also observed. These histopathological changes are also reported by Rahman *et al.* (2002).

Different degree of necrosis in splenic ellipsoids, pyknosis of immunocompetent cells' nuclei and increase in hemosidrins in melanomacrophage centres were observed in the spleen sections. Pyknosis, karyolysis, vacuolar degeneration of nuclei and ultimately necrosis of spleen tissue, especially the haematopoietic tissue, were also seen in almost all treatments. Necrosis of the haematopoietic tissue

of spleen, which is a very sensitive and highly active tissue, may occur readily as a result of toxins circulated from peripheral (Roberts, 2001).

TEM examination of tissues revealed that diazinon could cause severe damages to the micro-structure of cells. SEM and TEM examinations of nostril tissue of fish which had close contact to the diazinon, showed vacuolation in the cytoplasmic area of club cells with their secretion canals (openings) being blocked, resulting in reduction, and ultimately blocking, of proteinous material excretion on the cellular surfaces.

In conclusion, the light microscopic findings show that diazinon at sublethal concentration can affect some vital organs of grass carp such as gill, kidney, spleen and liver. However, the severity of damages is dependent on both toxicant-dose and exposure-duration. Also, results obtained from TEM and SEM studies show that the cytoplasmic organelles and cell nuclei of haematopoietic tissues and nostril tissue are affected by diazinon at sublethal concentrations. Such histological damages make fish susceptible to infectious diseases through immunophysiological suppression.

Aknowledgement

This study was conducted under financial support from Iranian fisheries research organization (IFRO) and research deputy of University of Tehran (Applied plan) which is highly appreciated.

References

- Abel, P.D. , 1976.** Toxic action of several lethal concentrations of anionic detergent on the gills of the brown trout (*Salmo trutta L.*), *J. fish Biol.* **9**:441-446.
- Alam, M.A. and Maughan, O.E. , 1992.** The effect of malathion, diazinon, and various concentrations of zinc, copper, nickel, lead, iron and mercury on fish. *Biol. Iraq Elem. Res.* **34**:225- 236.

- Anderson, D.P. and Zeeman, M.G. , 1995.** Immunotoxicology in fish. *In*: Rand GM , ed, Fundamentals of Aquatic Toxicology: Effects , Environmental Fate , and Risk Assessment ,2nd ed.Taylor & Francis, Washington, DC, USA, pp.371- 404.
- Bailey, H.C. ; Deanovic, L. ; Reyes, E. ; Kimball, T. ; Larson, K. ; Cortright, K. , Conner, V. and Hinton, D.E. , 2000.** Diazinon and chlorpyrifos in urban waterways in northern California, USA. *Environ. Toxicol. Chem.* 19(1):82-87.
- Bailey, H.C ; Miller, J.L. ; Miller, M.J. ; Wiborg, L.C. ; Deanivic, L. and Shed, T. , 1997.** Joint acute toxicity of diazinon and chlorpyrifos to *Ceriodaphnia dubia*. *Environ. Toxicol. Chem*, 16:2304-2308.
- Bozzola, J.J. and Russell, L.D. , 1999.** Electron microscope, Principles and Techniques for Biologists. 2nd Ed. Jones and Bartlett, Boston, USA.
- Cross, F.A. ; Peters, D.S. and Schaaf, W.E. , 1985.** Implication of waste disposal in coastal waterson fish population. American Society for Testing and Material Special Technical Publication. 854, 383-399.
- Dutta M.H. ; Richmonds C.R. and Zeno, T. , 1993.** Effects of diazinon on the gills of bluegill sunfish *Lepomis macrochirus* J. of Environ. Pathology Toxicology and Oncology, 12(4):219-227.
- Eisler, R. , 2000.** Hand book of chemical risk assessment, health hazards to humans, plants and animal, Vol. 2, Organics, Lemis publishers, pp.961-982.
- Hamm, J.T. ; Wilson, B.W. and Hinton, D.E. , 1998.** Organophosphate induced acetylcholine esterase inhibition and embryonic retinal cell necrosis in vivo in the teleost (*Oryzias latipes*). *Neurotoxicology*, 19(6):853-870.
- Jago, H. and Haines, T.A. , 1983.** Alterations in gill epithelial morphology of yearling Sunapee trout exposed to acute acid stress. *Tran Amer Fish Soc.* 112:689-695.

- Kabir, S.M. and Begum, R. , 1978.** Toxicity of three organophosphorus insecticides to Singhi fish *Heteropneustes fossilis* (Bloch). Dhaka Univ. Stud. **B 26**:115-122.
- Keizer, J. ; De agostino, G. ; Vitozzi, L. , 1991.** The importance of biotransformation in the toxicity of xenobiotics to fish. 1. Toxicity and bioaccumulation of diazinon in guppy (*Poecilia reticulata*) and zebra fish (*Brachydanio rerio*). Aquat. Toxicol. **21**:239-245.
- Keizer, J. ; De Agostino, G. ; Nagel, R. ; Gramaenzi, F. and Vitozzi, L. 1993.** Comparative diazinon toxicity in guppy and zebra fish: Different role of oxidative metabolism, Environ. Toxicol. Chem. **12**:1243-1250.
- Keizer, J. ; Agostino, G.D. ; Nagal, R. ; Volpe, T. ; Gnemi, P. and vitozzi, L. , 1995.** Enzymological differences of AchE and diazinon hepatic metabolism; correlation of in vitro data with selective toxicity of diazinon to fish species. The science of the Total Environ. **171**:213-220.
- Khalaf-Allah, S.S. , 1999.** Effect of pesticide water pollution on some hematological, biochemical and immunological parameters in *Tilapia nilotica* fish. Deuts- Tierarztliche - Wochenschrift. **106(2)**:67-71.
- Klaassen, C.D. and Warkins, J.B. , 1984.** Mechanisms of bile formation, hepatic uptake, and biliary excretion. Pharmacological Reviews. **36**:1-67.
- Luskova, V. ; Svoboda, M. and Kolarova, J. , 2002.** The effects of diazinon on blood plasma biochemistry in carp (*Cyprinus carpio*). Acta vet. BRNO. **71**:117-123.
- Mallatt, J. , 1985.** Fish gill structural changes induced by toxicants and other irritants: a statistical review. *Can J. Fish Aquat. Sci.* **42**:630-648.
- Rahman, M.Z., Hossain, Z., Mollah M.F.A. and Ahmad, G.U., 2002.** Effect of diazinon 60 EC on *Anabas testudineus*, *Channa punctatus* and *Barbodes gonionotus*, Naga, The ICLARM Quarterly, **25(2)**:8-12, 18.
- Roberts, R.J., 2001.** Fish Pathology, 3rd ed. W.B. Saunders Co.

- Sancho, E., Ferrando, M. D., Andreau, E., Gamon, M. 1992.** Acute toxicity, uptake and clearance of diazinon by the European eel, *Anguilla anguilla* L., J. Environ. Sci. Health. Part B: Pestic. Food Contam. Agric. Wastes. **B 27**:209-221.
- Sancho, E. ; Ferrando, M.D. ; Andreau, E. and Gamon, M. , 1993.** Bioconcentration and excretion of diazinon by eel. Bull. Environ. Contam. Toxicol. **50**:578-585.
- Sancho, E. ; Ferrando, M.D. ; Andreau, E. , 1997.** Sublethal effects of an organophosphate insecticide on the European eel, *Anguilla anguilla*. Ecotoxicol. Environ. SCI. Health. B 27(2):209 - 221.
- Sheipline, R. , 1993.** Background information on nine selected pesticides. California Regional Water Quality Control Board, Sacramento, CA, USA.
- Skidmor, J.F. and Tovel, P.W.A. , 1972.** Toxic effects of zinc sulphate on the gills of rainbow trout. Wat. Res. **6**:217-230.
- Svoboda, M. ; Luskova, V. ; Drastichova, J. and Zolabek, V. , 2001.** The effect of diazinon on hematological indices of common carp (*Cyprinus carpio*). Acta Vet. BRNO. **70**:457-465.
- Talebi, Kh. , 1998.** Diazinon residues in the basins of Anzali lagoon, Iran. Bull. Environ. Contam. Toxicol. **61**:477-483.
- Tsuda, T. ; Aoki, Sh. ; Kojima, M. and Harada, H. , 1990.** Bio concentration and excretion of diazinon, IBP, malathion and feritrothion by carp. Comp. Biochem. Physiol. **96C(1)**:23-26.
- Tsuda, T. ; Kojima, M. ; Harada, H. ; Nakajima, A. ; Aoki, S. , 1997.** Acute toxicity, accumulation and excretion of organophosphorus insecticides and their oxidation products in killifish. Chemosphere. **35**:939-949.

مطالعه اندامهای ماهی کپور علفخوار (*Ctenopharyngodon idella*) بعد از مجاورت با غلظتهای مختلف تحت کشنده سم دیازینون با استفاده از میکروسکوپ نوری و الکترونی

عیسی شریف پور^{۱*}، رضا پورغلام^۱، مهدی سلطانی^۲، محی الدین داود حسن^۳،

سهراب اکبری^۴ و علی نوری^۵

issasharifpore@yahoo.com

- ۱- موسسه تحقیقات شیلات ایران، صندوق پستی: ۶۱۱۶-۱۴۱۵۵ تهران، ایران
- ۲- بخش بهداشت و بیماریهای آبزیان دانشکده دامپزشکی دانشگاه تهران صندوق پستی: ۶۴۵۳-۱۴۱۵۵
- ۳- واحد بهداشت آبزیان، بخش مطالعات کلینیکی دامپزشکی، دانشکده دامپزشکی دانشگاه پوترا مالزی
- ۴- دانشکده دامپزشکی دانشگاه شیراز
- ۵- موسسه واکسن و سرم سازی رازی کرج
تاریخ دریافت: تیر ۱۳۸۴
تاریخ پذیرش: آذر ۱۳۸۴

چکیده

در این مطالعه تا ثیر غلظتهای تحت کشنده (۱، ۲ و ۴ میلی گرم در لیتر) آفت کش ارگانوفسفره دیازینون بر روی آبشش، کبد، طحال و کلیه کپور علفخوار (*Ctenopharyngodon idella*) با وزن متوسط 85.0 ± 15.0 گرم در ۱، ۷، ۱۵، ۳۰ و ۴۵ روز بعد از مجاورت ۱۲ ساعته با سم، در درجه حرارت ۲۲-۱۸ درجه سانتیگراد با استفاده از میکروسکوپ نوری بررسی گردید. همچنین از بافت سوراخهای بینی به منظور مطالعات میکروسکوپی الکترونی (TEM, SEM) استفاده شد.

نتایج حاصل از مطالعه بافتها با استفاده از میکروسکوپ نوری نشان داد که این سم موجب صدمات شدید به ساختمان سلولها و بافتهای کلیه، طحال و کبد شده که بصورت پرخونی عروق خونی، خونریزی، نفوذ سلولهای آماسی، پیکنوزه شدن هسته‌های سلولی، دژنراسیون واکوتلی و نکروز عمومی مشاهده گردید. همچنین در آبششها هیپرپلازی و چسبندگی تیغه‌های ثانویه به هم، جدا شدن واقفادن بافت پوششی از لایه پایه دیده شد.

آزمایش TEM بافت سوراخهای بینی ماهی، حاکی از آسیب سلولهای پوششی از جمله واکوتله شدن سلولهای چماقی شکل و غیر عادی شدن هسته سلولها بود. درازمایش SEM بافت سوراخهای بینی ماهی، کاهش ترشح مواد پروتئینی و تعداد وزیکولها در سطح سلولها و نیز بسته شدن کانالهای ترشحي سلولی قابل مشاهده بود.

لغات کلیدی: کپور علفخوار (*Ctenopharyngodon idella*)، دیازینون، هیستوپاتولوژی، TEM، SEM

* نویسنده مسئول