# Occurrence and histopathology of *Ascocotyle tenuicollis* metacercaria in gill of platyfish (*Xiphophorus maculatus*) imported to Iran

**Shoaibi Omrani B.[1]*; Ebrahimzadeh Mousavi H. A. [2]; Sharifpour I.[3]**

Received: April 2009 Accepted: December 2009

**Abstract**

The objective of this study was to determine the prevalence of metacercarial infection in plathyfish imported to Iran. A total of 100 imported live common platyfish (*Xiphophorus maculatus*) from approximately 24 shipments were collected from a quarantine facility in Iran in 2007 and examined in our veterinary laboratory. Among 800 examined gill arches about 1300 cysts were found in different locations of gill filaments and were identified as a heterophyid parasite metacercaria; *Ascocotyle (Ascocotyle) tenuicollis* Price, 1935. The prevalence of this parasite was 58%, the maximum and minimum quantity of metacercarial cysts per infected platyfish were 70 and 10, respectively. The adult worms are non-pathogenic and are intestinal parasites of piscivorous birds (e.g. Heron and Egret) and mammals. The first intermediate hosts are snails and the second intermediate hosts are centrarchiid, cyprinodontid, mugilid, and poeciliid fishes. Histopathologic examination of the infected fish gills revealed cartilage proliferation around metacercarial cysts, hyperplasia, hypertrophy and fusion in the affected gill filaments. To our knowledge, this is the first report of infection with *Ascocotyle tenuicollis* in the imported platyfish in Iran.

**Keywords**: Metacecaria, Platyfish, Gill, Pathology, *Ascocotyle tenuicollis,* Iran

[ Downloaded from jifro.ir on 2026-11-23 ]

[ DOR: 20.1001.1.15622916.2010.9.3.9.5 ]

1-Faculty of Veterinary Medicine, Islamic Azad University-Karaj Branch, Karaj, Iran.

2-Department of Aquatic Animal Health & disease, Faculty of Veterinary Medicine, University of Tehran, Tehran, Iran.

3-Aquatic Animal Health & Diseases Department, Iranian Fisheries Research Organization,Tehran, Iran.

*Corresponding author's email: babak.shoaibi@kiau.ac.ir

## Introduction

Trematodes of the family Heterophyidae are microscopic pear-shaped flukes. Their metacercariae encyst in different organs of fish (Scholz et al., 2001; Steele, 2003). The adult worms are non-pathogenic, intestinal parasites of piscivorous, or fish-eating birds and mammals (Armitage, 1998). In the intestine, the parasite matures and produces eggs which are passed into the water. Because these organisms are hermaphroditic, one parasite can populate a marsh with eggs. The first intermediate hosts are amnicolid and hydrobiid snails, which take up the eggs while feeding over the bottom surface of the estuary. The eggs develop sporocysts containing many redia or brood stage, and often move from the snail digestive gland to the gonads or hepatopancreas where further development ensues. When mature, these cercariae leave the redia and swim out of the snail towards illuminated areas of the water. The second intermediate hosts are centrarchiid, mugilid, cyprinodontid, and poeciliid fishes, and in at least one instance, anuran tadpoles. Within the gills, *Ascocotyle* cercariae enter the blood stream by penetration of the vascular tissue and encyst to form metacercariae in the fish host (Armitage, 1998; Steele, 2003).

Cercariae swim near these fish and are taken up in the respiratory current. Some *Ascocotyle* will, at this point, attach to and penetrate the gill filaments of the fish, dropping their tails before or soon after penetration (Armitage, 1998). Some species will immediately encyst in the gill, by the producing a multilayered hyaline, while others will search for and enter the efferent blood vessels supplying blood to the gills. The metacercariae will travel within the blood system, either against or with blood flow, to the heart, liver, brain and other organs, where cysts will be produced and further development is arrested (Armitage, 1998).Host infection and even organ infection site is *Ascocotyle* species characteristic. It is at this point in the life cycle, that predation upon the infected fish by Herons, Egrets, or Raccoons and other mammals, must occur in order that the definitive host can become infected and the worm can sexually mature (Armitage, 1998). Three subgenera; *Ascocotyle*, *Phagicola*, *Leighia* were proposed for "*Ascocotyle* complex" (Hoffman, 1999).The parasitized gills of fish are having increasingly difficult time extracting dissolved oxygen from the liquid medium that depends on gill filament changes (Weis and Bass, 2007).The extent of host response to the presence of cysts varies considerably, but the typical response is the production of fibrous capsule of collagen surrounding the cyst produced by associated host fibroblasts with little, if any host immune response (Armitage, 2000).Of all the aquarium fishes, those which give birth to living young are probably the most popular of all. Many millions of these small fishes such as mollies, platies, sword tails and guppies are sold each year to beginners.Another important feature of livebearer from the point of view of the aquarists is that the fish are hardy, and easily bred (Axelrod et al., 1987).Gills vulnerability is considerable because their external location and necessarily intimate contact with the water means that they are liable to be damaged by any irritant

[ Downloaded from jifro.ir on 2026-11-23 ]

[ DOR: 20.1001.1.15622916.2010.9.3.9.5 ]

materials, whether dissolved or suspended in the water (Roberts, 2001). *Xiphophorus maculatus* Gunther, 1866 belongs to Poeciliidae family, ideal community fish, peaceful and fecund. The optimum temperature range is 18-25(22-25°C), pH is 7-8 and the hardness of water is 8-35dH (Sanford, 2004). Males are smaller than females and have gonopodium, but platyfish is also suitable for single species set up (Axelrod et al., 1987).There is a knowledge vacuum about the origin of some economical losses in ornamental fish industry. Thus, this study shows one origin of several unwanted costs.

## Materials and methods

A total of 100 live common platyfish (*Xiphophorus maculatus*) imported into Iran from South Asia were collected with their original water from a quarantine facility in 2007 and examined in the Parasitology Laboratory of the Faculty of Veterinary Medicine of Karaj, Iran. The fish were derived from approximately 24 shipments. After preparing wet mount from gills, a total of 800 gill arches were examined using both the stereo microscope (SA Iran, N-180) and light microscope (LABOVAL 4).The trematode metacercariae were released from their cysts for better examination either by teasing or applying pressure (FAO Publications) and the number of metacercariae per gill filament was determined for each platyfish using a dissecting microscope. Several dissected metacercarial cysts were fixed in warm ethyl alcohol-formalin- acetic acid according to a method described elsewhere (Olson and Pierce, 1997). The parasite was identified according to Scholz (Scholz et al., 1997) and Hoffman (Hoffman, 1999) keys.To determine the host tissue response to the parasite, some of the affected gill arches were separated and put in formalin (10%) for histological studies (Olson and Pierce, 1997). Standard methods were applied to prepare histological sections. Haematoxylin and eosin were used for gill tissue staining (Roberts, 2001).

## Results

Among 800 examined gill arches, about 1300 metacercarial cysts were found in different location of gill filaments and were identified as a heterophyid parasite; *Ascocotyle* (*Ascocotyle*) *tenuicollis* Price, 1935; (Two complete rows of circumoral spines were present. Two rows of 16 spines each (total 32) present, encysted in gills of poeciliid fishes).In this study, the prevalence of this parasite was 58%, the maximum and minimum quantity of metacercarial cysts per infected platyfish were 70 and 10 (Fig. 1).The mean length and width of the trematode were 185 µm and 115 µm, respectively (Fig. 2) with two rows of oral sucker (Fig. 3).The histological observations of infected platy gills showed that although microscopic sections indicate some pathologic effects (mentioned below), but presence of parasite cyst was probably not sufficient to be a direct cause of mortality. Around metacercarial cysts, cartilage proliferation (Fig. 4), hyperplasia, hypertrophy and fusion (Fig. 5) were present in the affected gill filaments.

[ Downloaded from jifro.ir on 2026-11-23 ]

[ DOR: 20.1001.1.15622916.2010.9.3.9.5 ]



**Figure 1: Heavy-affected gill arch of a platyfish**




**Figure 2: Metacercaria of *Ascocotyle* and its cyst**

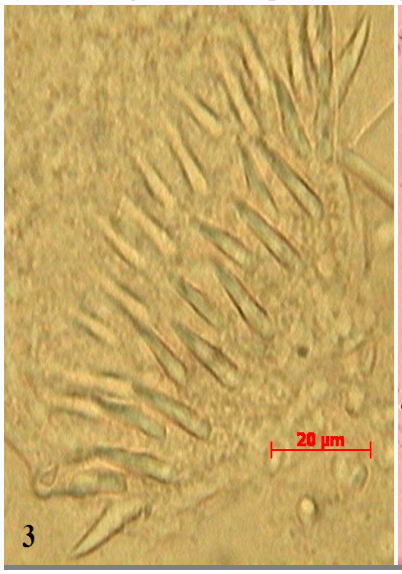


**Figure 3: Two rows-spined oral sucker**

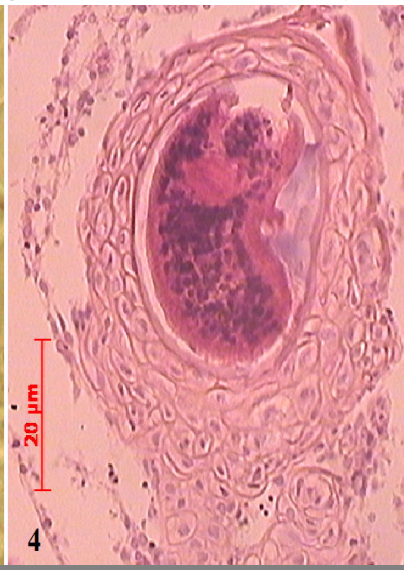


**Figure 4: Cartilage proliferation induced by a metacercaria**

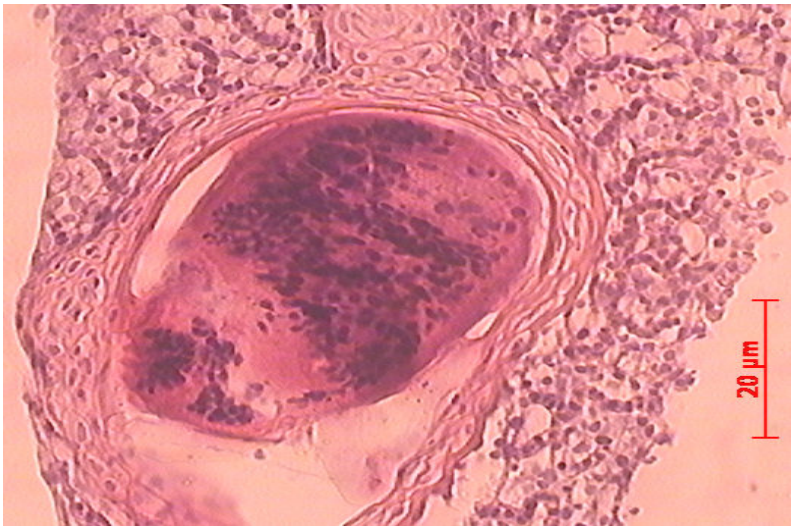


**Figure 5: Hyperplasia, hypertrophy and fusion of the gill filament and lamellae around the cyst**

[ Downloaded from jifro.ir on 2026-11-23 ]

[ DOR: 20.1001.1.15622916.2010.9.3.9.5 ]

## Discussion

To our knowledge, this is the first work and report about the *Ascocotyle* metacercarial infection in gill of imported platyfish in Iran.Iran as one of the ornamental fish markets, prefer to get the healthy fishes. Though these parasites cause no acute disease, but in long term they represent economical losses due to the large number of metacercariae damaging the gills. This condition results to low oxygen stress because of reduction in respiratory surface. Lesions of the gills associated with parasitic infection vary with the agent, host and density of infection (Roberts, 2001). In normal gill tissue, a filament is supported by a ray of specialized cartilage (Stoskopf, 1993; and Olson and Pierce, 1997).Reports of trematode metacercariae causing proliferation of gill cartilage have all been putatively caused by members of the family Heterophyidae (Olson and Pierce, 1997). Paperna (1991) reported similar respiratory stress in cichlids and carp and mortality in Farmed Japanese elvers, all infected by metacercariae *Centrocestus* sp. that located in gill cartilage. Sogandares-Bernal and Lumsden (1963) observed metacercariae of *Ascocotyle angrense* in the gill filament cartilage of cyprinodont and poeciliid fishes of the southern and eastern United States. There they encyst adjacent to the cartilaginous rod of the gill filament. The host then encloses the metacercaria in a thin layer of bone or cartilage.Blazer and Gratzek (1985) observed a reaction that often consisted of extensive cartilage proliferation around metacercariae in four species of naturally infected pond raised aquarium fishes in Florida (USA) and in two experimentally infected species and found that cartilage proliferation was associated with fusion of gill filaments (Olson and Pierce, 1997).Metacercariae of *Ascocotyle (Ascocotyle) tenuicollis* were reported from 8 families (such as; Characidae, Cichlidae, Eleotridae, Poeciliidae and more) and 40 species amongst Mexican freshwater fishes, but it found in several organs of fishes like as, heart, gill arches and exceptionally in mesentery (Salgado-Maldonado, 2006). Metacercariae of the genus reported in Belontiidae (Osphronemidae) family lives in freshwater of the Philippines (Arthur and Lumanlan-Mayo, 1997). *A. tenuicollis* also reported in heart of three Nicaraguan freshwater fish species and three species else in some organs such as, gill, gonad, kidney and muscle (Leopoldina et al., 2001).Control of *Ascocotyle* life-cycle is one of the most important ways to prevent the fish infection. The most practicable preventative method of controlling digenean infection in farmed fish is elimination of the vector snail. Available measures include use of chemical molluscicides. Of all these kinds of drugs to control the snails, only copper sulphate is of any practical use in fish ponds and circulation systems. Molluscicidal concentrations of niclosamide and N-tritylmorpholin currently recommended for snail control are toxic to fish. Copper sulphate (5-hydrate) molluscicide concentrations are tolerated by most fish (although some species and younger fish may be more susceptible). It is an inexpensive compound, widely used in fish ponds as an algicide, and it can be safely applied at a dose of 3.5 ppm to brackish-water ponds and at 2 ppm to neutral and hard fresh water ponds.However, in acid and soft fresh water (pH 6.8, calcium ions > 12 ppm), the same or even lower concentrations become toxic to fish. Copper salt may be applied by continuous dosing at a lower concentration (1 ppm), or as a low-soluble formulation (as copper carbonate or oxide) to produce long term residual effects. Treatment of drained ponds or raceways by copper sulphate, prior to stocking,

[ Downloaded from jifro.ir on 2026-11-23 ]

[ DOR: 20.1001.1.15622916.2010.9.3.9.5 ]

delayed but did not prevent repopulation by snails (FAO Publications). Most digenean trematode cercariae live approximately 24 hours, and are sophisticated swimmers with muscular tails (Weis and Bass, 2007).

Totally, in spite of understanding this way that the parasite cycle will not complete by keeping them in aquaria, but it affects on fish health, alertness and quantity of fish selling for the suppliers.

## References

**Alderton, D., 2005.** Encyclopedia of aquarium and pondfish. London, UK, DK Publisher. 400p.

**Armitage, M. H., 1998.** Complex Life Cycles in Heterophyid Trematodes: Structural and Developmental Design in the Ascocotyle Complex of Species. Fourth International Conference on Creationism, Pittsburgh, PA, Aug. 3-8 1998. Creation Science Fellowship.

**Armitage, M. H., 2000.** Ultrastructure of metacercarial cysts of six heterophyid trematodes from fish. *Parasitology Research*, **86**, 1003-1007.

**Arthur, R. J. and Lumanlan-Mayo, S., 1997.**Checklist of the parasites of fishes of the Philippines. FAO fisheries technical paper 369.

**Axelrod, H. R., Burgess, W. E., Emmens, C. W., Pronek, N., Walls, J. G. and Hunziker R., 1987.** Dr. Axelrod's mini-atlas of freshwater aquarium fishes.NJ., USA,T.F.H. publications Inc. 992P.

**Hoffman, G. L., 1999.** Parasites of north American freshwater fishes. 2nd edition, USA, Cornel University Press. 539P.

**Leopoldina Aguirre-Macedo M., Scholz, T., Gozales-Solis D., Vidal-Martines V. M., Posel P., Arjona-Torres G., et al., 2001.** Larval helminthes parasitizing freshwater fishes from the atlantic coast of Nicaragua, *Journal of comparative parasitology*, 68 (1), 42-51.

**Olson, R. E. and Pierce, J. R., 1997.** A Trematode Metacercaria Causing Gill Cartilage Proliferation in Steelhead Trout from Oregon. *Journal of wildlife Diseases*, 33(**4**), 886-890.

**Roberts, R. J., 2001.** Fish pathology, 3rd edition, London, UK, W.B.Saunders publishing. 472P.

**Salgado-Maldonado, G., 2006.** Checklist of helminth parasites of freshwater fishes from Mexico. Zootaxa 1324. New Zealand, Magnolia Press. 357 P.

**Sanford, G., 2004.** An illustrated encyclopedia of aquarium fish.Singapore, Select editions publications. 256P.

**Stoskopf, M. K., 1993.** Fish medicine. USA, W.B. Saunders. Publications, 882P.

**Scholz, T., Aguirre-Macedo, M. L. and Salgado-Maldonado, G., 2001.** Trematodes of the family Heterophyidae (Digenea) in Mexico: a review of species and new host and geographical records. *Journal of Natural History*, 35(**12**), 1733-1772.

**Scholz, T., Vargas-Vazquez, J., Aguirre-Macedo, L. and Martinez, v. M. V., 1997.** Species of *Ascocotyle* Looss, 1899 (Digenea: Heterophyidae) of the Yucatan Peninsula, Mexico, an notes on their life-cycles. *Systematic Parasitology*, **36**, 161– 181.

**Steele, E. and Hicks, T., 2003.** Histological effect of *Ascocotyle tenuicollis* (Digenea: Heterophyidae) metacercarial infection on the heart of *fundulus heteroclitus* (Teleostei: Cyprinodontidae). *Journal of the south Carolina academy of science*, 1(1),10-18.

**Weis, J. S. and Bass, C. S., 2007.** Parasite Effects on Host Behavior, Meri Grant Final Report (http://merilibrary.njmeadowlands.gov/dbtw-wpd/FullText/ML-07-11.pdf.

[ Downloaded from jifro.ir on 2026-11-23 ]

[ DOR: 20.1001.1.15622916.2010.9.3.9.5 ]