

A microscopic survey on Epicardial hemangioma-like structure in farmed sturgeon, *Acipenser baerii*

Rezaie A.^{1*}; Alishahi M.¹; Tulaby Dezfuly Z.¹

Received: November 2016

Accepted: July 2017

1-Faculty of veterinary medicine, Shahid Chamran University of Ahvaz, Ahvaz, Iran.

*Corresponding author's Email: a.rezaie@scu.ac.ir

Keywords: Cavernous Hemangioma like structure; Epicardium; Sturgeon; *Acipenser baerii*.

Introduction

As the main organ of the cardiovascular system, the vertebrate heart has been the focus of a myriad of morphological, functional, and molecular studies. The heart of fishes has not escaped from this stream of interest, and a wealth of information has accumulated on this subject over the past 50 years (Icardo, 2012). The heart of sturgeons is related to that of other ancient fish and the elasmobranchs in that it has a long conus arteriosus endowed with a muscular coat and several rows of conus valves (Icardo *et al.*, 2002). The subepicardium is a thin layer rich in collagen and elastin, fibroblasts, vessels, and nerves (Icardo *et al.*, 2000). Although this constitutes a general description, the subepicardium of the bulbus can be a more complex layer. For instance, it may contain lymphocytes, plasma cells, and

dendrite-like cells, and has been implied to be involved in the development of the humoral immune response (Icardo *et al.*, 1999). This is surprising, but it is not an isolated feature in fish. The subepicardium of the sturgeon contains thymus-like tissue (Icardo *et al.*, 2002) which has been implicated in the establishment and the maintenance of the cellular immune responses.

Haemangioma is a benign tumor of vascular endothelial cells or their progenitors. This tumor is common in dogs and rare in cats, horses and other domestic animals (Goldschmidt and Hendrick, 2002). Rare occurrences of capillary, cavernous haemangiomas, haemangioendotheliomas and haemangio-endotheliosarcomas affecting integument and visceral

organs have been recorded in fish from the USA by Harshbarger (1965).

Siberian sturgeon (*Acipenser baerii*), is considered as an important cultured sturgeon worldwide (Shi *et al.*, 2009). In recent years, some sturgeons have been listed as critically endangered species (IUCN Red Data List). Therefore, most countries has been focused on Siberian sturgeon for aquaculture. Fast growth rate in higher water temperature followed by the early sexual maturation has accelerated farming of this species in waters of temperate zone like Iran than the native environment (Moazen-zadeh *et al.*, 2018). In spite of extensive studies devoted to various aspects of biology and ecology, little attention has been paid to study of histological structure of vital organs like heart. There are various studies on heart structure in *Huso huso* and *A. naccarii* but to the best of our knowledge there is no report on heart structure of *A. baerii*.

Materials and methods

In spring of 2016, an *A. baerii*, (+3 years, 2.2 kg weight) was referred to department of Aquatic Animal health, faculty of Veterinary Medicine, Shahid Chamran university of Ahvaz with oxygenated plastic bag. The clinical signs were skeletal malformation, severe emaciation, exophthalmoses and skin ulcers. Wet mount of gill and skin scrapings was prepared for detection of any parasites involvement. Moderate infestation of the protozoan parasite, Trichodina, were seen in the skin and gills by light microscope (Noga, 2010).

After taking samples from skin and gill, euthanization and necropsy were carried out. Macroscopic examination revealed ascites. Also the heart had a cobblestone appearance which was characterized by multiple dark red cysts with different sizes (2-5 mm). They were raised from the surface and scattered on the ventricular and the atrium epicardium (Fig. 1). The heart were removed and fixed in 10% neutral buffered formalin. Other organs has normal structures. The sections of heart were processed by routine methods, embedded in paraffin, sectioned and stained with Haematoxylin and Eosin (H & E) (Luna, 1968).

Results and discussion

Microscopic examination of transverse sections of ventricles and atrium revealed multiple big cysts adhered to epicardium (Figs. 2, 3). They had different sizes and shapes (Fig. 4) and they were filled with erythrocytes and white blood cells (Fig. 5). They were covered by proliferated pleomorphic endothelial cells, which were cuboidal to squamous. They were supported by pericytes (Fig. 6). Intercavernous septa were contained stroma and number of fibroblasts and inflammatory cells (Fig. 5). The myocytes of ventricles and atrium had normal structures.

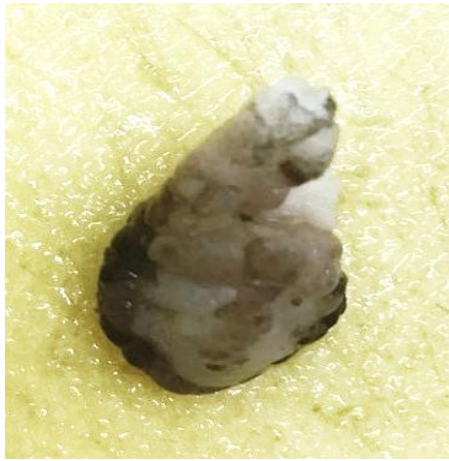

Figure 1: Heart of *Acipenser baerii*. Note the cobblerstone appearance of heart. There are different raised cysts on ventricles and atrium wall.

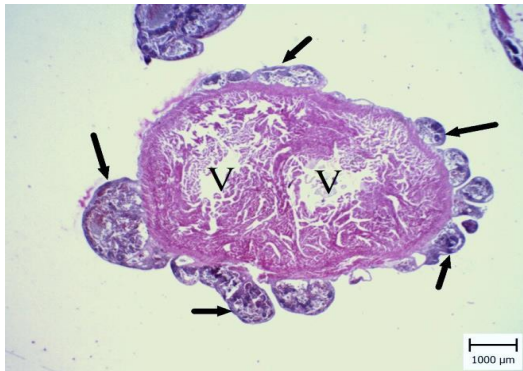

Figure 2: Heart of *Acipenser baerii*. Note to multiple raised cysts on the surface of ventricular (V) epicardium (arrows). They had different size and shape (H&E).

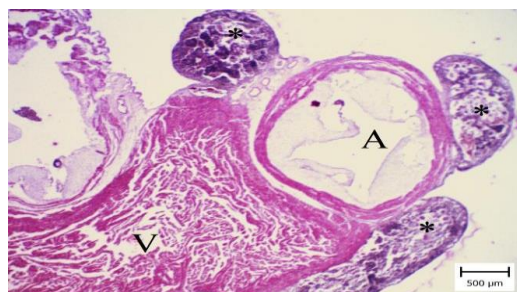


Figure 3: Heart of *Acipenser baerii*. Epicardial raised cysts (asterisks) on the surface of ventricle (V) and atrium (A) is obvious. They had different size and shape (H&E).

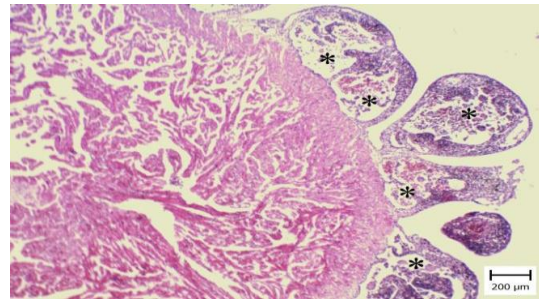


Figure 4: Heart of *Acipenser baerii*. The cysts (asterisks) are same as big stone on the surface of epicardium and they are filled with blood cells. Normal structure of myocardium is obvious (H&E).

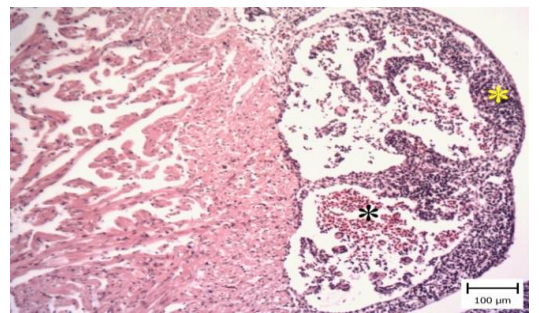


Figure 5: Heart of *Acipenser baerii*. Note to adherence of cysts to the epicardium filled with blood cells (black asterisk) and the thickened intercavernous septa (yellow asterisk) (H&E).

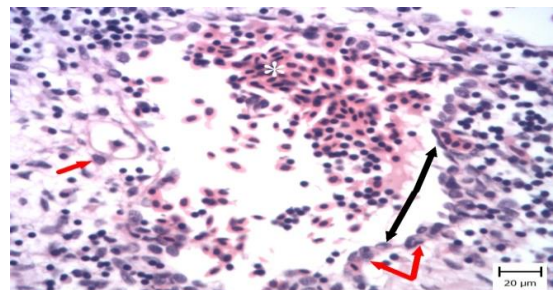


Figure 6: Heart of *Acipenser baerii*. Note to a big channel which is filled with erythrocytes and white blood cells. Also it is covered by endothelial cells (black arrows) which have variable shape, squamous to cuboidal. They are supported by pericytes (red arrows). The cysts are surrounded by stroma and inflammatory cells (H&E).

To date, a few reports focused on histological structures of heart in sturgeon. Icardo *et al.* (2002) reported that the subepicardial space in *A. naccarii* contains fat tissue, vessels, fibroblasts, and collagen. However, the most remarkable feature is the presence of large, ovoid-to-round nodular bodies containing a large vascular space lined by a continuous endothelium which is in agreement with this report. According Icardo *et al.* (2002) description, the wall of nodules is covered by dense connective tissue, and the nodes are bounded by similar structures and loose connective tissue or adipose tissue. In this report, there were no adipose tissue. Also the connective tissue in the wall of cysts were scant.

In this case most part of epicardium had cyst and there was no side predilection. The raised and convex cysts on the surface of the heart made a cobblestone appearance which was unique and it is in agreement with report of Joo *et al.* (1996). Hemangiomas are vascular tumors composed of blood vessels which can be either capillaries (capillary hemangioma) or large cavernous vascular channels (cavernous hemangioma). These cysts which were described are microscopically very similar to cavernous hemangioma. Hemangioma may result in compression of cardiac structures, congestive heart failure, cardiac rhythm disturbances or pericardial tamponade (Sata *et al.*, 2004). However, in this report, the fish was in poor condition. The most important clinical

manifestation was ascites which is the sign of heart failure. Also emaciation and muscular atrophy may be due to congestion and decreased food consumption. Although these cysts normally are exist, but in this case clinical signs probably were due to heart failure.

Differential diagnoses of masses in the heart myxoma, cysts, thrombi, lipoma, fibroma and malignant tumors which all have different microscopic features. Microscopic examination revealed big cysts filled with erythrocytes and leukocytes which were attached to epicardium and pericytes surrounded them. Also infiltration of inflammatory cells in the connective tissue of intercavernous septa were obvious and it is in accordance with other reports (Icardo *et al.*, 2002).

In conclusion this manuscript describes the clinical, macroscopic and microscopic features of heart in a farmed sturgeon, *Acipenser baerii*. The heart had cobblestone appearance and they were microscopically like epicardial cavernous hemangioma. Although these characteristics in sturgeon is normal, It may misdiagnose with other lesions.

References

- Goldschmidt, M.H. and Hendrick, M.J., 2002.** Tumors of the skin and soft tissues. In: Tumors in domestic animals (ed. by D.J. Meuten), Iowa State Press, Ames, Iowa, 45 P.
- Harshbarger, J.C., 1969.** Registry of tumors in lower animals. *National*

- Cancer Institute monograph*, 31, pp. XI-XVI.
- Icardo, J.M., Colvee, E., Cerra, M.C. and Tota, B., 1999.** Bulbus arteriosus of Antarctic teleosts. II. The red-blooded *Trematomus bernacchii*. *Anatomical Record*, 256, 116–126
- Icardo, J.M., Colvee, E., Cerra, M.C. and Tota, B., 2000.** The bulbus arteriosus of stenothermal and temperate teleosts: a morphological approach. *Journal of Fish Biology*, 57(suppl A), 121–135
- Icardo, J.M., Colvee, E., Cerra, M.C. and Tota, B., 2002.** The structure of the conus arteriosus of the sturgeon (*Acipenser naccarii*) heart: II. The myocardium, the subepicardium, and the conus-aorta transition. *Anatomical Record*, 268, 388–398.
- Icardo, J.M., 2012.** The teleost heart: A morphological approach. In: *Ontogeny and Phylogeny of the Vertebrate Heart* (ed. By D. Sedmera and T. Wang), Springer Science Media. 35 P.
- Joo, L.C., Moon, S.D., Jai, T.S., Soo, K.H., Byung, C., Bum, L.K., Hyuck, L.J. and Ryul, L.H., 1996.** Cardiac hemangioma arising in the epicardium. *Asian Cardiovascular and Thoracic Annals*, 4, 173–175.
- Luna, L.G., 1968.** Manual of histologic staining methods of the Armed Forces Institute of Pathology. New York, Blakiston Division, McGraw-Hill.
- Moazen-zadeh, K., Rajabi Islami, H., Zamini, A. and Soltani, M., 2018.** Effects of dietary zinc level on performance, zinc status, tissue composition and enzyme activities of juvenile Siberian sturgeon, *Acipenser baerii*. *Aquaculture Nutrition*, 1, 1–10.
- Noga, E.J., 2010.** Fish disease: Diagnosis and treatment. John Wiley and Sons. 137 P.
- Sata, N., Moriyama, Y., Hamada, N., Horinouchi, T. and Miyahara, K., 2004.** Recurrent pericardial tamponade from atrial hemangioma. *Annals of Thoracic Surgery*, 78, 1472–1475.
- Shi, X., Zhuang, P., Zhang, L., Feng, G., Chen, L., Liu, J. and Wang, R., 2009.** Growth inhibition of Siberian sturgeon (*Acipenser Baerii*) from dietary and waterborne fluoride. *Fluoride*, 42, 99–103.