

## Pathogenicity of *Aeromonas hydrophila* in giant freshwater prawn; *Macrobrachium rosenbergii*, cultured in East Malaysia

Abdolnabi S.<sup>1</sup>; Ina-Salwany M.Y.<sup>1,2\*</sup>; Daud H.M.<sup>1</sup>; Mariana N.S.<sup>2</sup>; Abdelhadi Y.M.<sup>3,4</sup>

Received: January 2014

Accepted: November 2014

### Abstract

*Aeromonas* infections are becoming a major risk factor in commercial aquaculture and it has been reported that a wide variety of fish and shellfish species are susceptible to this infection. In this study, 3 isolates of *Aeromonas hydrophila* were isolated from giant freshwater prawn (*Macrobrachium rosenbergii*) cultured in Kuala Pilah Simbilan Nigri in East Malaysia. Conventional and rapid identification systems (API 20E strips) were used for preliminary identification based on the biochemical characters of the isolated bacteria. On the other hand, polymerase chain reaction (PCR) using the universal primer; 16S rRNA, was done as an accurate and confirmatory identification. The virulence of *A. hydrophila* was determined using a pathogenicity test via I/M injection. The results revealed that the isolated bacteria were identified as *A. hydrophila* that revealed a high degree of similarity (98%) to the NCBI or Genbank database. Based on pathogenicity test results, LD<sub>50</sub> was determined as 1×10<sup>6</sup> CFU/50µl, while 1×10<sup>7</sup> CFU/50µl induced 100% mortality in the experimentally injected prawns. Histopathological changes were found in several organs including gill, hepatopancreas and heart. Those changes were mainly, melanisation, tissue erosion and necrosis, infiltration and hyperplasia of gill lamellae and mild or massive haemocyte reaction in the infected organs.

**Keywords:** *Aeromonas hydrophila*, Giant freshwater prawn, Pathogenicity, Malaysia

1-Department of Aquaculture, Faculty of Agriculture, Universiti Putra Malaysia, 43400, Serdang, Selangor, Malaysia

2-Laboratory of Marine Biotechnology, Institute of Bioscience, Universiti Putra Malaysia, 43400, Serdang, Selangor, Malaysia

3-Faculty of Veterinary Medicine, Universiti Malaysia Kelantan, 16100, Kota Bharu, Kelantan Malaysia

4-The Central laboratory for Aquaculture Research, Abbassa, Sharkia, Egypt

\*Corresponding author's email: salwany@upm.edu.my

## Introduction

Aquaculture is an important food source in Malaysia. The giant freshwater prawn *M. rosenbergii* (de Man) is an important freshwater farmed inland crustacean species in many countries because of its high commercial value (New.MB., 1982) and survival in a wide range of salinity between 0 and 18 ppt (Nelson *et al.*, 1977).

*M. rosenbergii* farming has dramatically expanded in many countries in the last decade when shrimp culture suffered a major setback due to repeated attack by viruses. The world production of the prawn species had increased to over 200,000 tonnes in 2002 (FAO, 2008) and the value of the prawn was US\$ 102.22 million in Malaysia during 2004, where the production of giant freshwater *M. rosenbergii* alone contributed US\$2.82 million or 2.8% of the total value (DOFM, 2008). The intensification of prawn aquaculture linked with deteriorating pond environment and resultant stress as well as poor quarantine, resulted in viral epizootics in this comparatively disease-resistant crustacean species.

Bacterial diseases associated with *Aeromonas* and other genera of chitinolytic bacteria (e.g., *Pseudomonas*, *Vibrio*, *Beneckea*, and *Leucothrix*) have been reported in Brazilian prawn hatcheries (Lombardi and Labao, 1991a,b), where they led to “black-spot” bacterial necrosis and gill obstruction, while Brady and Lasso (1992) reported a predominance of *Aeromonas* spp., *Bacillus* spp., and *Pseudomonas* spp.

among bacteria isolated from the hemolymph of prawn lesions.

Most significantly, both *Aeromonas* and *Pseudomonas* have been isolated from the hepatopancreas (HP) of apparently healthy prawns, and all of these *Aeromonas* and *Pseudomonas* isolates were able to produce five extracellular products (ECP): protease, gelatinase, chitinase, lipase, and hemolysin (Sung and Hong, 1997). For this reason *Aeromonas* spp. is considered to be the major threat to the commercial cultivation of *M. rosenbergii* aquaculture that caused high mortality in Taiwan (Sung *et al.*, 2000), Brazil (Lombardi and Labao, 1991a) and India (Chand *et al.*, 2006; Lalitha and Surendran, 2006; Sahoo *et al.*, 2007; Shankar *et al.*, 2011).

Therefore, the objectives of the present study were to investigate apparently healthy and moribund giant freshwater prawns; *M. rosenbergii* for isolation and phenotypic as well as genotypic characterization of *A. hydrophila* and to test its pathogenicity on the experimentally-infected prawns via the I/M injection.

## Materials and Methods

### *Prawn sampling and bacterial isolation*

A total of 105 apparently healthy prawns were collected from different farms of Kuala Pilah Simbilan Nigri Malaysia. Primary isolation was carried out by taking with loop from different organs of prawns including haemolymph, gill, carapace and telson. Samples were grown on TSB and the null isolates were

subcultured on TSA plates at 30°C for 24 hours for phenotypic and genotypic characterization studies.

#### *Phenotypic characterization of bacterial isolates*

Bacterial isolates selected from single colonies on TSA, were tested using Gram-staining, catalase and oxidase test. Strains, which had catalase positive and Gram negative rods, were subcultured on TSA and incubated overnight to get pure colonies. Purified bacterial cells were then inoculated into tryptic soy broth (TSB, Difco) for PCR assay and glycerol stocking.

The biochemical characteristics of bacteria isolates from *M. rosenbergii* were performed using API 20E strips (Biomérieux, France), according to the manufacturer's instructions. The conventional, API 20E was quality controlled and validated using a well-known isolate of *A. hydrophila* (ATCC 35654 strain). The classification method used to classify the bacterial genus and species was as described in Bergey's Manual of Systematic Bacteriology (Whitman *et al.*, 2012).

The bacteria were further characterized using selective medium, Rimler Shotts agar (Hi Media) and haemolytic reaction on blood agar base (Merck, Germany) with 5% sheep blood.

#### *Genotypic characterization of bacterial isolates using PCR assay*

DNA was extracted from five isolates that phenotypically close to *A. hydrophila* isolates using AllPrep DNA/RNA Mini Kit (QIAGEN-USA) following the manufacturer's instructions. The DNA amplification was performed on 1.7 µl DNA extract in 50 µl using High Fidelity PCR System (Eppendorf Master cycler Gradient-Germany). PCR products were visualized by red gel staining on 1.5% agarose gel electrophoresis. A1Kbp DNA ladder was used (Thermo scientific, USA).

PCR reactions have been carried out using 10µl 5X green go Taq, 1µl dNTP, 0.5 µl of the Universal primer (16S rRNA), 0.25 µl of Taq DNA polymerase enzyme, 3µl MgCl<sub>2</sub>, 10ng template DNA in an assay volume of 50 µl. These concentrations were determined by a series of preliminary standardizing experiments.

Based on morphological and biochemical characteristics colonies of recovered *Aeromonas* in this study were chosen for further identification based on 16S rRNA analysis. DNA extraction was first evaluated by the amplification of the 16S rRNA gene using the gene sequence of the universal primers shown in Table 1. The PCR products were purified by QIA quick PCR purification kit (QIAGEN-USA). Purified PCR products were sequenced directly by 1st BASE CO (DNA sequencing services) Malaysia.

**Table 1: Universal primer sequences used for PCR assay.**

| Primer pair | Sequences (5'-3')                | Target gene | PCR amplicon (pb) | Reference                           |
|-------------|----------------------------------|-------------|-------------------|-------------------------------------|
| 27F         | 5'-AGA GTT TGA TCC TGG CTC AG-3' | 16S rRNA    | 1100              | (Stackebrandt <i>et al.</i> , 1988) |
| 149R        | 5'-GGT TAC CTT GTT ACG ACT T-3'  |             |                   |                                     |

#### *Pathogenicity test, haematological and histopathological examination*

Healthy giant freshwater prawns; *M. rosenbergii* (21-25 g) were collected from a commercial monoculture pond of the Kuala Pilah, Negri Sembilan, Malaysia. Prawns were acclimated for seven days before experiment in 120 l capacity tank in aerated freshwater at 29-33 °C in the laboratory. Prawns were fed twice a day with commercial prawn basal feed of 4% of the body weight (Chand *et al.*, 2006). Ten percent of water was renewed daily to remove waste feed and fecal materials. During the acclimation and experiment period water temperature was maintained at 27±2°C, pH 7.2-8, total hardness 75-100 mg/l, dissolved oxygen 6-7 mg/l and ammonia concentration at <0.1 mg/l.

The virulent strain of *A. hydrophila* isolated from prawns with Beta hemolytic feature, was used in the pathogenicity test. The bacteria were grown on TSB for 24h at 30°C then broth cultures were centrifuged at 7000 rpm for 15 min at 4°C and the bacterial pellets were washed twice with sterile phosphate buffered saline (PBS; pH 7.4) via centrifuging at 14000 rpm for 1 min. The pellet was re-suspended in PBS and adjusted to an OD of 1.0 at 600 nm, equivalent to 1×10<sup>8</sup> CFU/ml, from this which, concentrations of 10<sup>5</sup>, 10<sup>6</sup> and

10<sup>7</sup> CFU in 50µl were prepared to conduct the pathogenicity test. Bacterial concentration was estimated by optical density, and using spectrophotometer. Experimental prawns were injected between the second and third abdominal segments with 3 different doses of *A. hydrophila* suspension.

The mean LD50 and total mortality was determined using the simplified method of Reed and Muench (1938). Tissue and hemolymph samples from moribund and infected prawns were collected for haematological and histological studies. Hepatopancreatic and muscle tissues of moribund prawns were fixed in Davidson's solution (Bell and Lightner, 1988). The fixed specimens were embedded in paraffin and cut into 5µm sections, stained with Gram stain and with modified Mayer's hematoxylin and eosin stain before viewing under the light microscope (Sheehan and Hrachak, 1980), also hemolymph (0.5ml) was withdrawn from the ventral sinus located at the base of the first abdominal segment of each prawn by 5 ml-syringe along with 26 gauge needle containing 4.5 ml fixative, 2-4% formaldehyde in 0.2 M sodium cacodylate buffer plus 10% sucrose in pH 7.4 and finally modified with Alsever solution as an anticoagulant (Kondo, 2003; O.I.E, 2005; Art *et al.*,

2007). A drop of haemolymph was placed on a hemocytometer and measure THC (total haemocyte count) and DHC (differential haemocyte count) using microscope, and 25µl haemolymph was taken and diluted (1:14) in TSB and spread on TSA plates in quadruplicate followed by 12 h incubation at 30°C to obtain bacterial counts. Counts were calculated taking the dilution factor into consideration and recorded as the mean cfu count±SE for the quadruplicate counts (Chand *et al.*, 2006) to measured bacterial clearance efficiency.

## Results

### Bacterial isolation

In primary characterization tests, 16 strains were described as Gram negative, rod shaped, motile, oxidase positive, catalase positive and fermentative

suggesting that colonies might be aeromonas.

### Phenotypic characterization of *A. hydrophila*

All the 16 bacterial isolates from giant freshwater prawns were identified to the species level as *A. hydrophila* by conventional biochemical characteristics and API 20E system. Isolates obtained from prawns (Table 2) were described as Gram negative, rod shaped, motile, oxidase positive, catalase positive and fermentative, Beta-haemolytic on blood agar (5% sheep blood) and growth on selective medium, Rimler Shotts agar. Rapid API 20E system successfully identified one isolate of *A. hydrophilaby* resulting in a profile number that matched with *A. hydrophila* profile number in API 20E manual.

**Table 2: Phenotypic characteristics of *Aeromonas hydrophila* isolated from giant freshwater prawns compared to standard *A. hydrophila* (ATCC 35654 strain) as reference strain.**

| Test                       | Isolated <i>A. hydrophila</i> | Standard <i>A. hydrophila</i> | Test                        | Isolated <i>A. hydrophila</i> | Standard <i>A. hydrophila</i> |
|----------------------------|-------------------------------|-------------------------------|-----------------------------|-------------------------------|-------------------------------|
| Gram staining reaction     | -                             | -                             | Beta-galactosidase          | +                             | +                             |
| Cell morphology            | Rod                           | Rod                           | Arginine dihydrolase        | +                             | +                             |
| Catalase production        | +                             | +                             | Lysine decarboxylase        | +                             | +                             |
| Oxidase production         | +                             | +                             | Ornithine decarboxylase     | -                             | -                             |
| Haemolysis (5% sheep RBC)  | β                             | β                             | Citrate utilization         | +                             | +                             |
| Growth on/in               |                               |                               | H <sub>2</sub> S production | -                             | -                             |
| Tryptic soy agar (TSA)     | +                             | +                             | Urease                      | -                             | -                             |
| Blood agar                 | +                             | +                             | Tryptophan deaminase        | -                             | -                             |
| Nutrient agar (N/A)        | +                             | +                             | Indole production           | +                             | +                             |
| Brain heart infusion (BHI) | +                             | +                             | Acetoin production          | +                             | +                             |
| BHI+4% NaCl                | +                             | +                             | Gelatinase production       | +                             | +                             |
| BHI+6.5% NaCl              | -                             | -                             |                             |                               |                               |

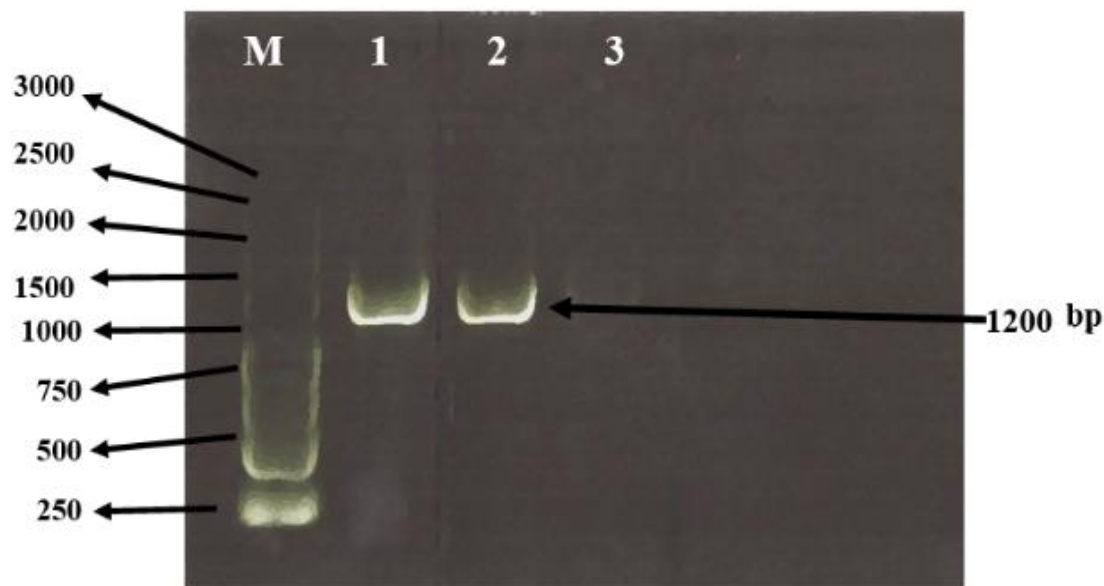
**Table 2 continued:**

|                    |   |   |                        |   |   |
|--------------------|---|---|------------------------|---|---|
| BHI+8% NaCl        | - | - | Utilization of glucose | + | + |
| Rimler Shotts agar | + | + | Manitol                | + | + |
| Temp 32-35°C       |   |   | Inositol               | - | - |
| Temp 35-37°C       | + | + | Sorbitol               | - | - |
| Temp 40-42°C       | - | - | Ramnose                | - | - |

*Genotypic characterization of A. hydrophila using PCR assay and sequencing results*

The PCR assay resulted in the amplification of 1200 bp band (16S

rRNA) in only one isolate confirmed as *A. hydrophila* with 98% similarity to GenbankBLAST (Fig. 1, Lane no.2).

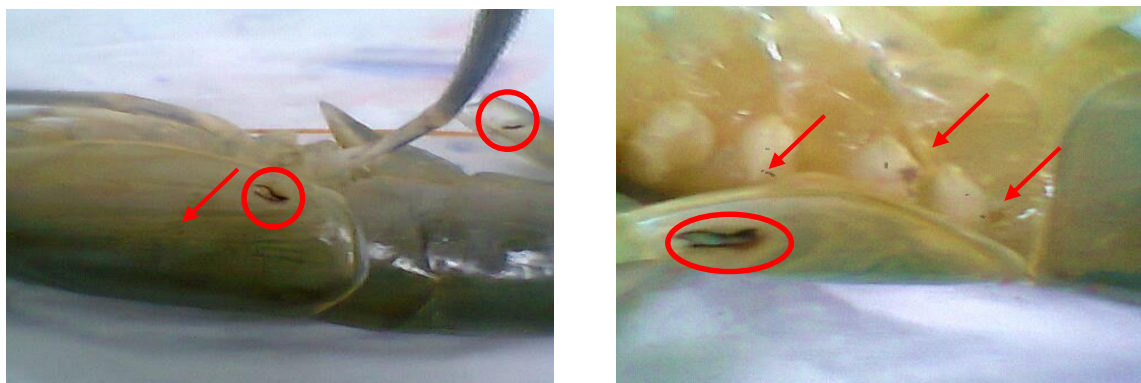

**Figure 1:** Agarose gel showing amplification products of *Aeromonas hydrophila* compared to standard *Aeromonas hydrophila* strain. M=1Kb molecular marker, Lane 1= *Aeromonas hydrophila* reference strain, Lane 2= prawn *Aeromonas hydrophila* isolate; Lane 3=negative control.

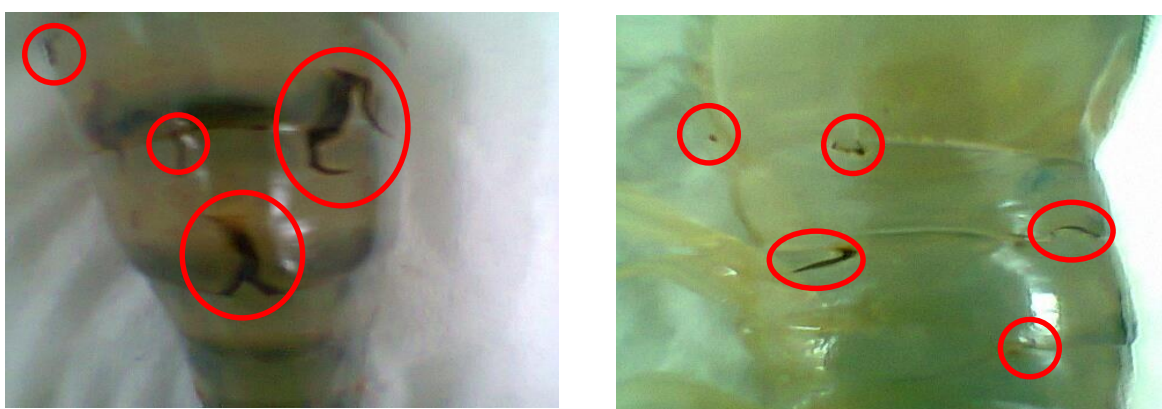*Pathogenicity, histopathological and haematological alterations induced by A. hydrophila*

Most of the giant freshwater prawn that were injected with high dose of bacteria ( $10^5$ - $10^7$ ) died within 3 days. Disease signs due to experimental infection were similar to those of infected prawn found

in commercial prawn farms. After 7-9 days, focal melanised lesions and hepatopancreas erosion observed in some of surviving prawn. Observed clinical signs were shown in Figs 2,3. However, some prawns died without showing any clinical signs.



**Figures 2: Focal melanised lesions on gill of infected prawns.**



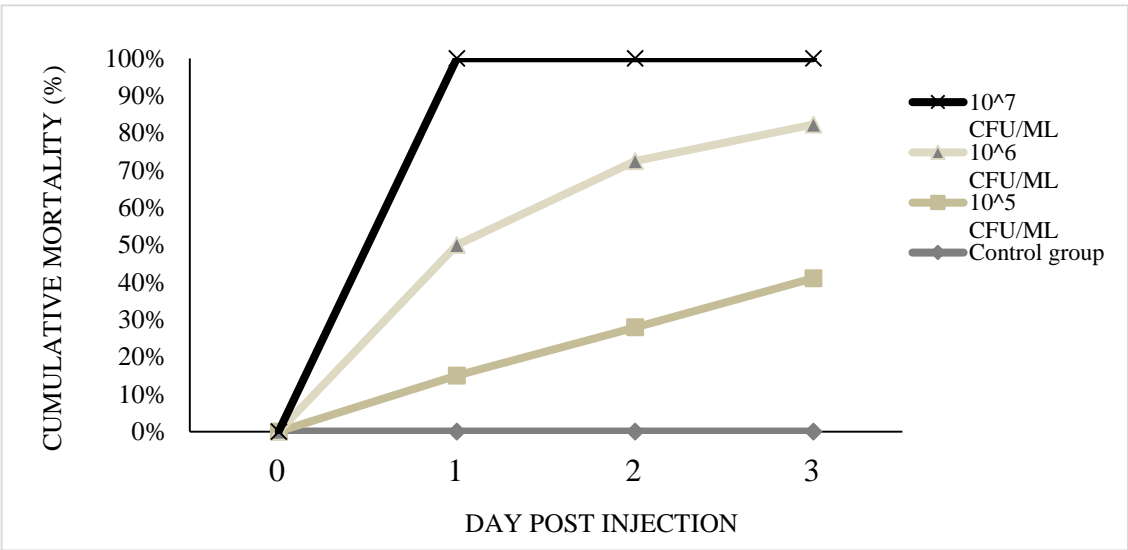
**Figures 3: Focal melanised lesions on different parts of the body of infected prawns.**

Re-isolation of *A. hydrophila* from apparently healthy prawns confirmed the pathogenic effect of this isolate to the injected prawns. In the experimental challenge test, a mortality of 50% ( $LD_{50}$ ) occurred in the prawns that were injected with 50  $\mu$ l PBS containing *A. hydrophila* at  $1 \times 10^6$  CFU/50  $\mu$ l and 100% mortality in *M. rosenbergii* injected with  $1 \times 10^7$  CFU/50  $\mu$ l of *A. hydrophila*

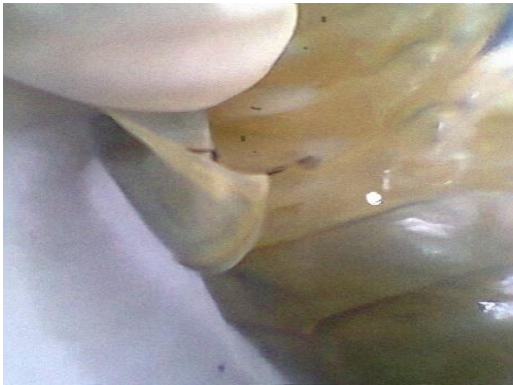concentration. No mortality occurred in the control group (Fig. 4).

Histopathological changes in giant freshwater prawns were found in several organs including gills, hepatopancreas and heart. The tissue exhibited focal necrosis, haemocytes infiltration, hyperplasia (Figs. 5,6). Muscular damage and mild or massive haemocyte reaction occurred at 1-6 hours after injection (Figs. 7,8).

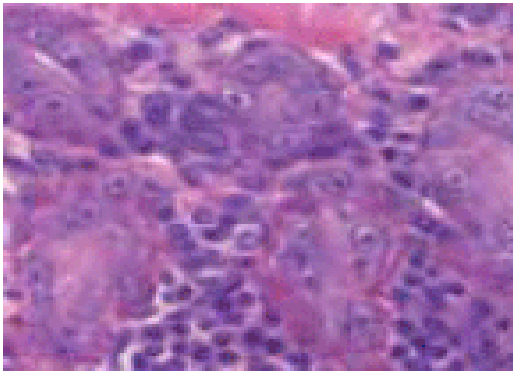




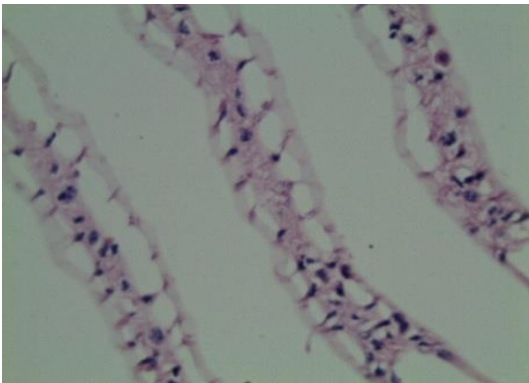
**Figure 4: Mortality rate of giant freshwater prawn intramuscularly injected with various concentrations of *Aeromonas hydrophila***



**Figure 5: Focal necrosis on carapace and gill of infected giant freshwater prawn.**



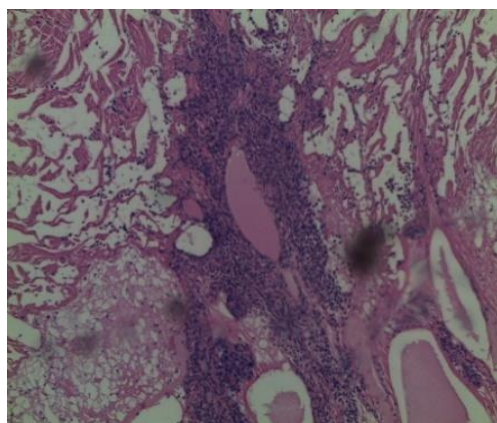
**Figure 7: Mild haemocytes reaction in hepatopancreas of infected giant prawns. (100X).**



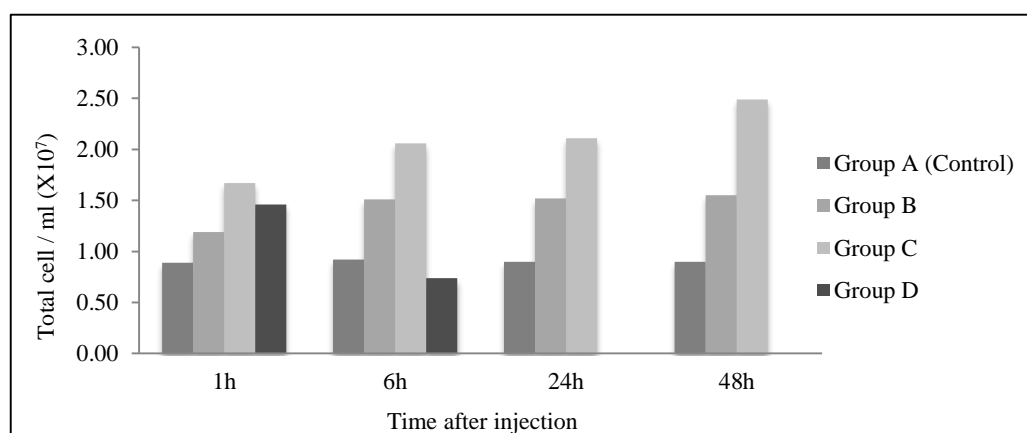
**Figure 6: Haemocytes infiltration and epithelial cell hyperplasia in gill lamellae of infected giant freshwater prawn. (100X).**

Hematologic assay showed that total haemocyte counts (THC) did not significantly increase at any time in *M. rosenbergii*. Just a small rise was observed after 24 h in the group that was injected with  $1 \times 10^6$  CFU/50 $\mu$ l of *A. hydrophila* concentration (Fig. 9). For bacterial clearance efficiency, statistic analysis showed that the bacterial counts significantly increased with time (Fig. 10).

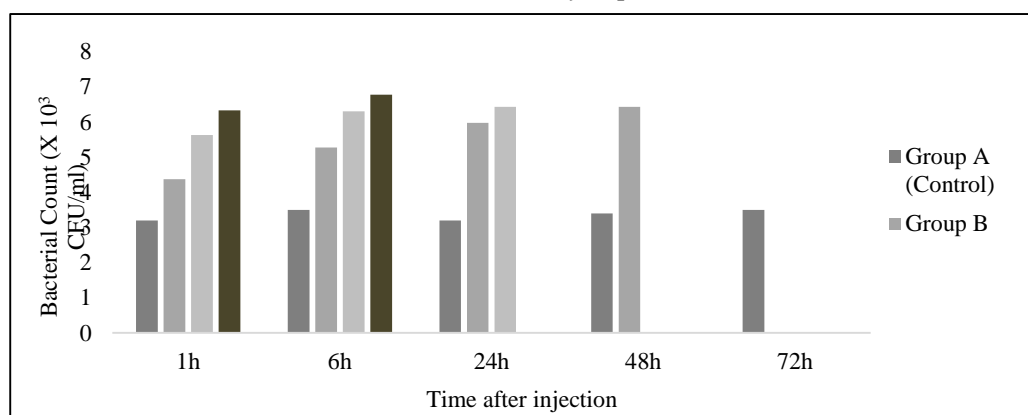




**Figure 8: Massive haemocytes reaction and melanisation in heart of infected prawns. (100X).**



**Figure 9: Total haemocyte count of giant freshwater prawn intramuscularly injected with various concentrations of *Aeromonas hydrophila*.**



**Figure 10: Bacterial clearance efficiency of giant freshwater prawn intramuscularly injected with various concentrations of *Aeromonas hydrophila*.**

## Discussion

A wide variety of fish and shellfish including giant freshwater prawn has been reported to be susceptible to *A. hydrophila* by a number of authors

(Tonguthai, 1992; Esteve *et al.*, 1994). *A. hydrophila* is also believed to be a pathogen of emerging importance for humans through consuming fish and shellfish contaminated with *A.*

*hydrophila* (Vivekanandhan *et al.*, 2005).

The basic clinical signs of *A. hydrophila* in *M. rosenbergii* were the presence of one to several focal melanin lesions on the outer body surface. Infected prawns showed melanisation at the site of infection and the disease was usually found focally on the gills, carapace, appendages, uropods, telson, or body cuticle, etc. (Te, 1994; Be, 2002).

The chitinolytic action of certain small bacteria is thought to support their greater virulence (Delves-Broughton *et al.*, 1976; Chan *et al.*, 1979). The erosion thus, produced in some lesions further exposes the epithelial layer and connective tissue underneath. The typical dark color of such lesions is due to local formation and deposition of melanin. As a consequence of inflammation, the activation of the proPO system defense response against the invading bacteria and tissue restoration, takes place. In cases of further progression of this syndrome, bacteria may reach the hemolymph via deep lesions and spread throughout the body (New and Valenti, 2008). The bacteria were rapidly distributed to various tissues viz., gills, heart, hepatopancreas within 1 h, and the tissues revealed haemocytic nodule formation after 3 h of injection. There was rapid clearance of both the forms of bacteria from the circulation. Similarly, the nodule formation, that was prominent in cardiac musculature, was rapidly eliminated from the tissues of the group injected with opsonized bacteria.

Also gill, heart and hepatopancreas had massive and mild haemocyte reaction respectively (Sahoo *et al.*, 2007). When the body cavity of a crustacean is invaded by a large number of microorganisms, some may be removed directly by phagocytosis, while many others are confined to nodules or clumps of cells. In response to the presence of these infected tissues, it has been suggested that some hemocytes may migrate into connective tissue (Factor and Beekman, 1990), the blood sinuses between the hepatopancreatic tubules, and the gills (Fontaine and Lightner, 1974; Smith *et al.*, 1984; Sung and Song, 1996).

Thelestam and Ljungh (1981) reported that lung fibroblasts treated with  $\alpha$ - and  $\beta$ -hemolysin of *A. hydrophila* for 30 min at 37°C showed significant morphological changes. Cells exposed to the  $\alpha$ -hemolysin were rounded and retracted from each other and to some extent from the polystyrene surface. On the contrary, the  $\beta$ -hemolysin induced a characteristic vacuolization of the cytoplasm, with nuclei and nucleoli distinctly seen. Also histopathological studies of moribund crayfish showed that extensive necrotic nuclei and clump-infiltrated hemocytes were found in observed tissues including gill, heart, hepatopancreas and the circulatory system (Jiravanichpaisal *et al.*, 2009). Histopathology of hepatopancreas and gill sections in crayfish that were injected with *A. hydrophila* showed the hemocyte aggregation and necrosis within pyknosis of nucleus. In lower

concentrations of bacteria no pathological changes of heart were observed. In digestive tract no changes were appeared in treatments, but in concentration of  $3 \times 10^8$  CFU ml/1 a low aggregation of hemocytes was revealed (SamCookiyaei *et al.*, 2012).

The results obtained in this study suggested that the clinical sings and histopathological alterations induced by the present isolates were similar to those caused by *A. hydrophila*, isolated in previous studies (Sung *et al.*, 2000; Chand and Sahoo, 2006; Chand *et al.*, 2006; Sahoo *et al.*, 2007). Besides, the present isolates were biochemically and physiologically similar to the isolates that were found by Thangaviji *et al.*, 2012.

In crustaceans, circulating hemocytes play an important role in defense (Jiravanichpaisal *et al.*, 2009) Firstly, they remove foreign particles in the haemolymph by phagocytosis, encapsulation and nodule aggregation. Secondly, the haemocytes take part in wound healing by cellular clumping and initiation of coagulation processes as well as release of prophenoloxidase system.

For crustaceans, some information exists on increase in THC in relation to disease resistance, lower THC in hypoxic conditions and the highest haemocyte numbers during the post-moult stage. The circulatory haemocytes act as a stress indicator but this parameter varies non-specifically according to the natural rhythms of the environment and chemical and physiochemical stress. The higher THC may provide an enhanced

immune capability during periods of higher activity or enhanced environmental bacterial loads when the risk of injury or infection is increased. Fontaine and Lightner observed that the large haematogenous cells migrated into the injection site and phagocytosed carmine and large clumps of multinucleated cells were formed by phagocytic haemocytes in white shrimp, *Penaeus setiferus*, after injection with carmine. Smith and Ratcliffe reported that the haemocyte count of *C. maenas* recovered after 24 h of injection of *Bacillus cereus* and *Morexella*, and indicated that the mobilization of a sessile pool and/or haemopoiesis occurred. Sequeira *et al.* (1996) indicated that the haemocyte count of *P. japonicus* consequent to injection of bacterial or foreign material is compensated by the proliferation of circulating haemocytes. Concerning the total haemocyte count of *M. rosenbergii*, no major alteration in THC or DHC population was observed inspite of the formation of large numbers of haemocytic nodules in various tissues. Thus, it may be concluded that the peripheral haemocyte population is being maintained to an optimum level in case of recruitment to the tissues during foreign body entry either via increased haemopoiesis or mobilization of haemocytes from a sessile pool or rapid multiplication of haemocytes in the circulation or tissues at the place of bacterial settlement.

In the present study, we did not observe THC rising in different groups through time but three types of

haemocytes were observed; The fusiform cells 65.4%, large ovoid cells 22.2% and small round cells from 12.4% in different groups of experimental prawns.

These types of haemocytes in this species were also described earlier. Similarly, Vazquez *et al.* (1997) also found 70% fusiform or hyaline haemocytes, 20% granular haemocytes and 10% agranular haemocytes in the intermoult *M. rosenbergii*. In this species, the fusiform haemocyte was the most abundant haemocyte found as opposed to other crustaceans. However, injection of bacteria failed to influence the differential haemocyte count except for a slight change in fusiform cells after 2 days and a rise in small round haemocytes after 24 h with an increase in the dose of bacteria as compared to the control.

The rapid API 20E system successfully identified the present isolates as a *A. hydrophila* but failed to identify one of the samples, where the isolate that didn't match with the reference strain. This poor identification agreed with the observations of Lee *et al.* (2000) when using the API 20E system.

PCR assay confirmed the identification of 1 strain as *A. hydrophila* using the universal primer; 16S rRNA, which amplified a specific 1200 bp band or DNA fragment from the isolated *A. hydrophila* in this study as well as from the *A. hydrophila* references train. These results agreed with Thangaviji *et al.*, (2012) who reported a 1200 bp

product from *A. hydrophila* using the same primer; 16S rRNA.

## References

- Be, L.M., 2002.** Investigation on diseases of giant freshwater prawn (*Macrobrachium rosenbergii*) in ponds and rice-prawn farming systems in An Giang province. Msc. thesis (in Vietnamese).
- Brady, Y.J. and De La Vega, E.L., 1992.** Communications: Bacteria in the Hemolymph of the Freshwater Prawn *Macrobrachium rosenbergii*. *Journal of aquatic animal health*, 4(1), 67-69.
- Chan, J., Lewis, D. and Leong, J., 1979.** Abrasion and bacterial infection as the probable cause of exoskeletal lesions in the Hawaiian freshwater shrimp, *Atya bisulcata*. Paper presented at the Proceedings of the 2nd Biennial Crustacean Health Workshop, 20–22 April 1977, Galveston, Texas.
- Chand, R.K., and Sahoo, P.K., 2006.** Effect of nitrite on the immune response of freshwater prawn *Macrobrachium malcolmsonii* and its susceptibility to *Aeromonas hydrophila*. *Aquaculture*, 258(1), 150-156.
- Chand, R.K., Sahoo, P.K., Kumari, J., Pillai, B.R., and Mishra, B.K., 2006.** Dietary administration of bovine lactoferrin influences the immune ability of the giant freshwater prawn *Macrobrachium rosenbergii* (de Man) and its resistance against *Aeromonas hydrophila* infection and nitrite stress. *Fish and Shellfish Immunology*, 21(2), 119-129.

- Delves-Broughton, J., amp. and Poupard, C., 1976.** Disease problems of prawns in recirculation systems in the UK. *Aquaculture*, 7(3), 201-217.
- DOFM., 2008.** *Macrobrachium rosenbergii*, Department of Fishery Malaysia (DOFM) <http://www.dof.gov.my/v2/perangkaan>.
- Esteve, C., Amaro, C. and Toranzo, A.E., 1994.** O-Serogrouping and surface components of *Aeromonas hydrophila* and *Aeromonas jandaei* pathogenic for eels. *FEMS Microbiology Letters*, 117(1), 85-90.
- FAO., 2008.** *Macrobrachium rosenbergii*, [http://www.fao.org/fishery/culturedspecies/Macrobrachium\\_rosenbergii/en](http://www.fao.org/fishery/culturedspecies/Macrobrachium_rosenbergii/en).
- Jiravanichpaisal, P., Roos, S., Edsman, L., Liu, H. and Söderhäll, K., 2009.** A highly virulent pathogen, *Aeromonas hydrophila*, from the freshwater crayfish *Pacifastacus leniusculus*. *Journal of Invertebrate Pathology*, 101(1), 56-66.
- Lalitha, K.V. and Surendran, P.K., 2006.** Microbiological changes in farm reared freshwater prawn (*Macrobrachium rosenbergii* de Man) in ice. *Food Control*, 17(10), 802-807.
- Lee, S., Kim, S., Oh, Y. and Lee, Y., 2000.** Characterization of *Aeromonas hydrophila* isolated from rainbow trouts in Korea. *Journal of Microbiology-Seoul*, 38(1), 1-7.
- Lombardi, J.V. and Labao, V.L., 1991a.** Disease and conditioning factors of mortality in larval culture of prawn of the genus *Macrobrachium*. In "Proceedings of the 3<sup>rd</sup> Brazilian Symposium on Shrimp Culture". Joao Pessoa, Paraiba, Brazil, pp. 401-408.
- Lombardi, J.V. and Labao, V.L., 1991b.** Diseases and other factors leading to mortality in juveniles and adults belonging to the genus *Macrobrachium*. In "Proceedings of the 3<sup>rd</sup> Brazilian Symposium on Shrimp Culture". Joao Pessoa, Paraiba, Brazil, pp. 409-419.
- Nelson, S.G., Armstrong, D.A., Knight, A.W. and Li, H.W., 1977.** The effects of temperature and salinity on the metabolic rate of juvenile *Macrobrachium rosenbergii* (Crustacea: Palaemonidae). *Comparative Biochemistry and Physiology Part A: Physiology*, 56(4), 533-537.
- New, M.B. and Valenti, W.C., 2008.** Freshwater Prawn Culture: the farming of *Macrobrachium rosenbergii*: Wiley. com.
- New, M.B., 1982.** Giant prawn farming. developments in aquaculture and fisheries science,, 10(Elsevier Scientific Publishing Co., Amsterdam. 532P.
- Reed, L.J. and Muench, H., 1938.** A simple method of estimating fifty per cent endpoints. *American Journal of Epidemiology*, 27(3), 493-497.
- Sahoo, P.K., Pillai, B.R., Mohanty, J., Kumari, J., Mohanty, S. and Mishra, B.K., 2007.** In vivo humoral and cellular reactions, and fate of injected bacteria *Aeromonas hydrophila* in freshwater prawn *Macrobrachium rosenbergii*. *Fish & amp; Shellfish Immunology*, 23(2), 327-340.
- SamCookiyaei, A., Afsharnasab, M., Razavilar, V., Motalebi, A.,**

- Kakoolaki, S., Asadpor, Y. and Nekuie Fard, A., 2012.** Experimentally pathogenesis of *Aeromonas hydrophila* in freshwater Crayfish (*Astacus leptodactylus*) in iran. *Iranian Journal of Fisheries Sciences*, 11(3), 644-656.
- Sequeira, T., Tavares, D. and Arala-Chaves, M., 1996.** Evidence for circulating hemocyte proliferation in shrimp *Penaeus japonicus*. *Developmental and Comparative Immunology*, 20, 97-104.
- Shankar, R., Murthy, H.S., Sujatha, H.R., Jayaraj, E.G., Tejpal, C.S. and Chinthamani, V.S., 2011.** Effect of nucleotide on growth, immune responses and resistance of *Macrobrachium rosenbergii* (De Man) to *Macrobrachium rosenbergii* nodavirus (MrNV) and extra small virus (XSV) and *Aeromonas hydrophila* infection. *Aquaculture International*. pp. 1-12.
- Stackebrandt, E., Murray, R. and Trüper, H., 1988.** Proteobacteria classis nov., a name for the phylogenetic taxon that includes the "purple bacteria and their relatives". *International Journal of Systematic Bacteriology*, 38(3), 321-325.
- Sung, H.H. and Hong, T.Y., 1997.** The gram-negative bacterial flora in hepatopancreas of giant freshwater prawn (*Macrobrachium rosenbergii*): Antibiotic sensitivities and production of extracellular products. *Journal of the Fisheries Society of Taiwan*, 24(3), 211-223.
- Sung, H.H., Hwang, S.F. and Tasi, F.M., 2000.** Responses of giant freshwater prawn (*Macrobrachium rosenbergii*) to challenge by two strains of *Aeromonas* spp. *Journal of invertebrate pathology*, 76(4), 278-284.
- Te, B.Q. and Tam, V.T. 1994.** Common diseases in cultured fish and shrimp at Mekong delta - treatment and prevention methods. *Agricultural Publishing House. (in Vietnamese)*.
- Thangaviji, V., Michaelbabu, M., Anand, S.B., Gunasekaran, P. and Citarasu, T., 2012.** Immunization with the *Aeromonas* OMP Provides Protection against *Aeromonas hydrophila* in Goldfish (*Carassius auratus*). *Microbial and Biochemical Technology*, 4, 045-049.
- Tonguthai, K., 1992.** Diseases of the freshwater prawn *Macrobrachium rosenbergii* in Thailand. In *Diseases in Asian Aquaculture*, (Ed. by I.M. Shariff, R.P. Subasinghe & J.R.Arthur) Asian Fisheries Society, Manila. pp. 89-95.
- Vezquez, L., Perez, A., Millan, D., Agondis, C., Martin, G., Cooper, C., Lascurain, R. and Zenteno, E., 1997.** Morphology of hemocytes from the freshwater prawn *Macrobrachium rosenbergii*. *Journal of Morphology*, 234, 147-153.
- Vivekanandhan, G., Hatha, A. and Lakshmanaperumalsamy, P., 2005.** Prevalence of *Aeromonas hydrophila* in fish and prawns from the seafood market of Coimbatore, South India. *Food Microbiology*, 22(1), 133-137.
- Whitman, W.B., Goodfellow, M., Kämpfer, P., Busse, H.J., Trujillo, M. E., Ludwig, W. and Parte, A., 2012.** *Bergey's manual® of systematic bacteriology* (Vol. 5): Springer.1750P.