

Infection of skipjack tuna *Katsuwonus pelamis* (Linnaeus 1758) of Oman Sea with cestode *Trypanorhyncha* (Diesing 1863)

Sattari, A.*¹; Kheirandish, R.²; Nourollahi-Fard, S. R.²; Shoaibi Omrani, B.³;

Sharifpour, I.⁴

Received: December 2012

Accepted: February 2014

Abstract

Numerous reports on existence of white cysts in musculature of skipjack tuna *Katsuwonus pelamis* and lack of information about the quality of cysts and individual responses of fish to them led the authors to focus on this fish as a commercially valuable species. This study investigated the histopathologic responses of skipjack tuna to highly prevalent cystic larval stages of *Trypanorhyncha*. Some 92.25% of 400 examined skipjack tuna of Oman Sea (Iran) captured from processing center in Chabahar have been diagnosed infected by *Trypanorhyncha* Larvae through gross muscle examination. Minimum of 5 to maximum of 19 cysts were observed per each flank flesh with no significant difference between number of cysts from right (9 ± 4) and left flanks (10 ± 4) and also males and females ($p > .05$, t- student test (spss version 16)). Using hematoxylin and eosin (H&E) staining of $4\mu\text{m}$ sections of surrounded cysts with muscle and light microscopy observations each metacestode was distinguished encapsulated by surrounding fibrous cyst wall consists of thin inner layer and a thick outer layer with the minimal histopathologic changes around it. The highly prevalent *Trypanorhyncha* infection in Oman Sea represents the high rate of infection among elasmobranchs. The ability of encapsulated parasite to escape from the immune system of the host is assumed as one reason for the observed minimal tissue response in infected fish and the continuation of infection among elasmobranchs and teleosts of Oman Sea.

Keywords: Skipjack tuna, Oman Sea, *Trypanorhyncha*, Histopathology.

1-Corresponding author, Department of Food Hygiene and Quality Control, Faculty of Veterinary Medicine, Shahid Bahonar University of Kerman, Kerman, Iran. PO box: 76169133

2-Department of Pathobiology, Faculty of Veterinary Medicine, Shahid Bahonar University of Kerman, Kerman, Iran

3-Department of Animal Health and Nutrition, College of Veterinary Medicine, Karaj Branch, Islamic Azad University, Alborz, Iran.

4-Department of Aquatic Animal Health and Diseases, Iranian Fisheries Research Organization, Tehran, Iran

*Corresponding author's email: amirsattari@uk.ac.ir

Introduction

The tuna fishes are spread across environmentally and ecologically appropriate conditions of Iranian coastal waters of Oman Sea (610Km). The lower salinity of coastal waters attracts the fish population (James and Jayaprakash, 1988; James and Jayaprakash, 1991; Banks, 1993). The skipjack tuna is important species that is fished traditionally and industrially in Chabahar (Southeast Iran).

The presence of parasites in tuna flesh is considered seriously from two points of view; first the parasites with zoonotic importance and then the ones which decrease the marketability of product and consumer desire leading to economical losses (Dias et al., 2010). Of the second mentioned importance Campbell and Beveridge (1994) believe that the *Trypanorhyncha* cestodes comprise a great diversity of parasites of which adults parasitize elasmobranchs (sharks and rays) and larval stages are found in abdominal cavity and musculature of teleosts. Parasitism of *Trypanorhyncha* worms has been shown in the king mackerel *Scomberomorus cavalla* with the data on intensity, abundance and sanitary aspects of the infection (Dias et al., 2010). In a mouse model the crude larval extract of a specific *Trypanorhyncha* is approved to contain allergenic molecules which can represent a risk for fish consumers (Go`mez-Morales et al., 2008).

Combination of clinical signs and histopathological features of tissues and organs (pathology) is a key diagnostic method (Feist and Longshaw, 2008).

One of the interesting fields of research on *Trypanorhyncha* is evaluation of

physiological and histopathological responses of vertebrate and invertebrate hosts. The host response of white shrimp *Penaeus setiferus* to larval stage of *Trypanorhyncha* was investigated by Sparks and Fontaine (1973) and also two types of Penaeid shrimps in Florida have been compared in response to infection with plerocercoid of *Trypanorhyncha* (Feigenbaum & Carnuccio 1976). Since such studies have not been performed in teleost; tuna fish and because of frequent non documented reports on infection of the species; the objective of this study is to explain the histopathologic findings in skipjack tuna (*Katsuwonus pelamis*) infected with *Trypanorhyncha* and infection prevalence rate at Chabahar (northern Oman Sea).

Materials and methods

Based on the reports of the health and hygiene inspectors on the intensity of white colored cysts in tuna flesh, 400 skipjack tuna of 8 ± 2 kg were randomly obtained from the Chabahar fish Industry Center between June-September 2010 (4-5 fish per day).

The fish were decapitated and eviscerated after gender recognition then sectioned on the midsagittal line dividing the fish into right and left flanks. The specimens (half trunk or flank) were macroscopically examined and dissected for the presence and number of white cysts in the body musculature then muscular tissues sectioned into blocks (1.5×1.5 cm) each one contained at least one cyst and surrounding muscle and were collected in 10% formalin for fixation and in order to subsequent microscopic and histopathological

investigations. After one week of fixation, tissue samples were trimmed, processed routinely for paraffin embedding, sectioned at $4\mu\text{m}$, stained with (H&E) permanently mounted on glass slides using standard histological techniques and examined by bright field microscope. To observe the individual larvae the metacestode was excavated from the cyst and observed after staining with fushin. The t- student test (SPSS version 16, $p < .05$) was used to compare the status of infection between right and left flank fleshes and males and females.

Results

369 out of 400 (92.25%) examined fish were positive for presence of *Trypanorhyncha* larvae recognized through the observation of 4 tentacles (191 female fish, 169 male fish and 10 undistinguished) (Figs. 1, 2 & 3). The number of cysts ranged from 5 to 19 per each flank flesh. No significant difference was observed between number of cysts in fleshes (mean \pm SD) obtained from right (9 ± 4) and left flank (10 ± 4) and also between males and females ($p > .05$).

The fleshes contained 5 cysts were the most frequent infected right fleshes (61 flesh) and the fleshes with 15 and 16 cysts were the least frequent (4) fleshes of right flank. Among left flank fleshes 8cyst containing fleshes were the most (57) and 14cyst containing fleshes were the least (6) fleshes (Fig. 4).

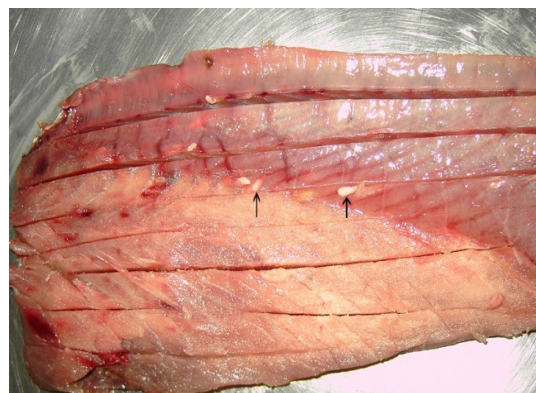


Figure 1: Encapsulated cysts of *Trypanorhyncha* (arrows) within the muscle of fish

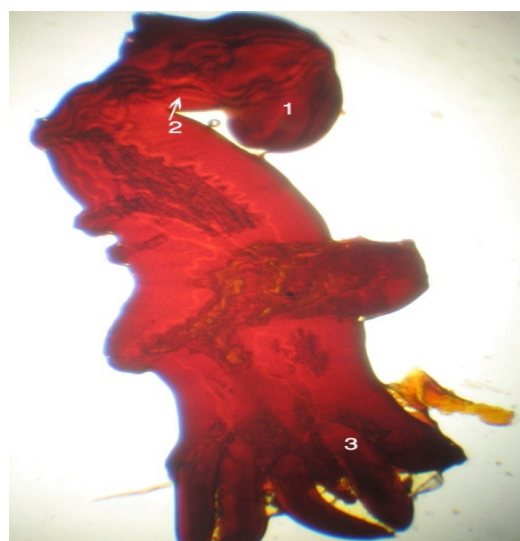


Figure 2: The fushin stained metacestode of parasite (*Trypanorhyncha*) under light microscope. X100; 1. Bothridium, 2. Tentacle sheath, 3. Tentacle bulb

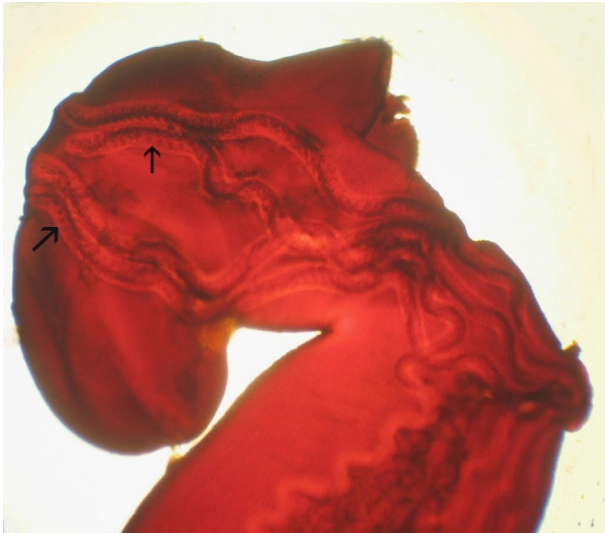


Figure 3: The larger view of bothridium of *Trypanorhyncha* metacestod with 4 hooked tentacles (arrows). X400

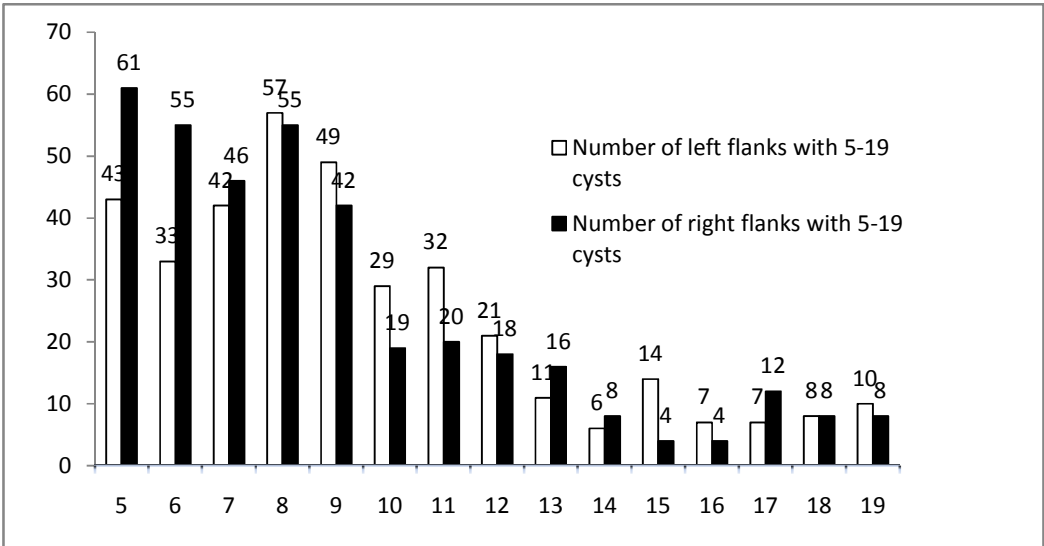


Figure 4: The frequency of right and left flank fleishes (vertical axis) infected with specific number of cysts (horizontal axis, 5-19 cysts per flank). Fleishes with 5 cysts are the most frequent (61) and fleishes with 15 -16 cysts are least frequent (4).

The histopathological changes tended to be minimal and localized to the region of parasitic cysts (Fig 5). The metacestodes were found encapsulated by a fibrous cyst wall consist of thin inner layer and a thick outer

layer surrounding the metacestodes within the muscle fibers. The amorphous eosinophilic material filled the cysts and a mild inflammatory reaction around the cyst was observed in which infiltration of lymphocytes

and presence of edema caused a gap between cyst walls and muscle fibers. The growth of parasitic cyst had resulted in pressure atrophy of surrounding musculature (Fig. 5).

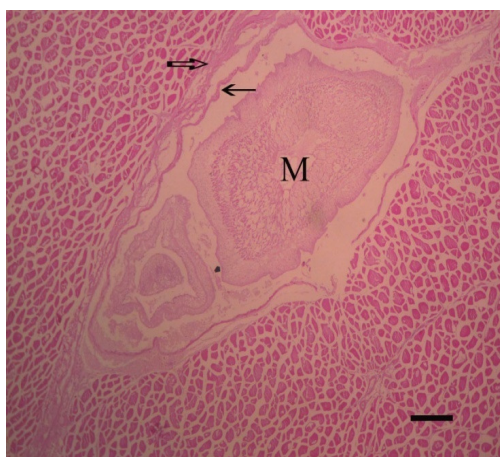


Figure 5: Metacestode of *Trypanorhyncha* (M) in the muscle of skipjack tuna surrounded by fibrous cyst wall that is consisted of thin inner layer (arrow) and a thick outer layer (open arrow). H&E. Bar=250µm.

Discussion

92.25% of examined fish contained between 5-19 cysts of metacestode of trypanorhyncha per each flank with no significant difference between number of cysts in right (9 ± 4) and left (10 ± 4) flank and also between males and females ($p > .05$). Microscopically metacestodes (larvae) were embedded in cysts with two layer wall of thin (inner) and thick (outer) layer inside which amorphous eosinophilic material filled the cysts with mild inflammatory reactions around the cyst.

Parasitism is one of the most successful ways of life that its diversity exceeds that of

non parasitic life (Poulin and Morand, 2000; Rohde, 2002). Parasitic infections in fishes are extremely common, especially in wild populations from diverse aquatic environments where ecological requirements for intermediate hosts and parasite transmission are met (Feist and Longshaw, 2008).

In natural conditions, most parasites do not severely injure their hosts and do not cause mortalities (Scholz, 1999). Otherwise the infected communal moving species like tuna were unlikely be able to move in community and would not be easily fished. That is the reason of observation of such number of parasitized fish in this study.

Estimation of the actual harm to fish caused by the presence of parasites is assumed very difficult in cultured fish and almost impossible in feral fish populations and it does not necessarily imply the manifestation of a disease (Scholz, 1999).

The success of parasitism is based on many methods of avoiding immune recognition and evading immune response in order to ensure parasite proliferation, survival and persistence in the host while the immune systems have responded with the evolution of numerous ways of countering these evasive strategies (Riffkin et al., 1996; Cox, 1997).

Although almost all principle histopathological lesions may be encountered as a result of parasitic infections and various categories of acute and chronic inflammation and degenerative changes are frequently observed (Feist and Longshaw, 2008) it is very important to understand the sometimes surprising ability of the host to compensate for some significant organ dysfunction.

Accordingly in this study the mild inflammatory response of host determined by light infiltration of lymphocytes and edema around the cyst walls is observed and is indicative of parasite ability to escape and not to provoke the immune reaction of the host in order to resist and preserve its infective nature until ingested by host of elasmobranch.

The amorphous eosinophilic material around the metacestodes in this study has been also observed in lesions associated with the attachment of adult stage of trypanorhynch to the gastrointestinal tract of elasmobranchs.

This anatomical sequestration is similar to escape mechanism of some nematode larval stages encyst in the host muscle fibers and are surrounded by a cystic wall (Else, 2005).

Loss of significant difference between the number of cysts of right and left flank is indicative of similar and steady rate of circulation in the muscular mass of right and left flanks. However the phenomenon that the flanks with 5 and 15-16 cysts are respectively the most and least frequent infected flanks is probably caused by the intensity of parasite in the surrounding area and feeding rate of fish that leads to specific range for number of ingested larvae. In some cases the broad range of 1 to 678 plerocerci per fish has been reported (Palm and Overstreet, 2000). The prevalence of 92.25% for metacestode infection observed in the skipjack tuna of this study is categorized as highly prevalent but the prevalence of up to 98% has been observed in butter fish in Gulf of Mexico. In accordance to our study some slight tissue response involving fatty infiltration and inflammatory infiltrations

was associated with the metacestode presence (Palm and Overstreet, 2000).

The type of lesions associated with the attachment of adult trypanorhynch to gastrointestinal tract of elasmobranch is different from and more severe than what we observed as tissue response to cystic metacestodes. Borucinska and Caira (2006) reported the lesions in digestive tract of sharks ranged from acute necrotizing to chronic granulomatous gastroenteritis; regenerative hyperplasia and intestinal metaplasia of gastric epithelium were also present (Borucinska and Caira, 2006).

In this study as the number of cysts per flank increase the frequency of infected flanks decrease (Fig. 4). This decreasing trend of infection is probably related to the load of infection in the environment and the potency of immune system in response to specific number of metacestodes and also probable natural elimination of highly infected hosts.

After gross and histopathology examination of infected fish with white cysts of parasites authors conclude that the highly prevalent *Trypanorhyncha* infection in Oman Sea represents the high rate of infection among elasmobranchs of that area. The ability of encapsulated parasite to escape from the immune system of the host is the reason for the observed minimal tissue response in infected fish.

To cope with the decreased marketability of the infected flesh and economic loss it is reasonable to apply methods of preservation and processing which lead to inactivation of the parasite and transform the flesh to a processed product more favorable for

consumption. The mariculture of tuna in the area can be useful to decrease the infection rates through the prevention of elasmobranchs contacts with teleosts.

Acknowledgments

The authors appreciate the cooperations of personnel and inspectors of Chabahar Fish Processing Center and assistances of pathology laboratory of Veterinary Medicine Faculty at Shahid Bahonar University of Kerman. Also this study performed under funding of research budget of Shahid Bahonar University of Kerman which had no any additional involvement in practical stages of research.

References

- Banks, W. J., 1993.** Applied veterinary histology. Mosbey Year Book. Inc. St. Louis. (3rd), pp.469-470.
- Borucinska, J. D. and Caira, J. N., 2006.** Mode of attachment and lesions associated with trypanorhynch cestodes in the gastrointestinal tracts of two species of sharks collected from coastal waters of Borneo. *Journal of Fish Diseases* 29, 395-407.
Doi: 10.1111/j.1365-2761.2006.00730.x
- Campbell, R. A. and Beveridge, I., 1994.** Order *Trypanorhyncha* Diesing, 1863. In: Khalil, L. F., Jones, A. and Bray, R. A. (Eds) *Keys to the cestode parasites of vertebrates*. Wallingford: CAB International, pp.51-148. Record number: 19950800500.
- Cox, F., 1997.** Designer vaccines for parasitic diseases. *International Journal of Parasitology* 27(11), 47-57.
Doi: 10.1016/S0020-7519(97)00112-4.
- Dias, F. J. E., São Clemente, S. C. and Knoff, M., 2010.** Larvae of Anisakidae nematodes and *Trypanorhyncha* cestodes of public health importance in *Aluterus monoceros* (Linnaeus, 1758) in Rio de Janeiro State, Brazil. *Revista Brasileira de Parasitologia Veterinária* (Online). 19(2), 94-97.
Doi: 10.1590/S1984 29612010000200005.
- Else, K., 2005.** Have gastrointestinal nematodes outwitted the immune system? *Parasite Immunology*, 27(10-11), 407-415.
Doi: 10.1111/j.1365-3024.2005.00788.x.
- Feigenbaum, D. and Carnuccio, J., 1976.** Comparison between the trypanorhynchid cestode infections of *Penaeus duorarum* and *Penaeus brasiliensis* in Biscayne Bay, Florida. *Journal of Invertebrate Pathology*, 28(1), 127-130.
Doi: 10.1016/0022-2011(76)90078-1.
- Feist, S. W. and Longshaw, M., 2008.** Histopathology of fish parasite infections - importance for populations. *Journal of Fish Biology*, 73, 2143-2160.
Doi: 10.1111/j.10958649.2008.02060.x.
- Go`mez-Morales, M. A., Ludovisi, A., Giuffra, E., Manfredi, M. T., Piccolo, M. and Pozio, E., 2008.** Allergenic activity of *Molicola horridus* (Cestodea, *Trypanorhyncha*), a cosmopolitan fish parasite, in a mouse model. *Veterinary Parasitology*, 157, 314-320.
Doi: 10.1016/j.vetpar.2008.07.010.

- James, P. and Jayaprakash, A., 1988.** Status of tuna fishery in India. Collective Volume of Working Documents No3, IPTP/FAO *Expert consultation on stock Assessment of tunas in the Indian Ocean*, 3, 278-291.
- James, P. and Jayaprakash, A., 1991.** The status of fisheries for small tunas in India. *Journal of Marine Biology Association of India*. 33(1,2), 182-193.
- Palm, H. W. and Overstreet, R. M., 2000.** *Otobothrium cysticum* (Cestodea: *Trypanorhyncha*) from the muscle of butterfishes (Stromateidae). *Parasitology Research*, 86, 41-53. PMID: 10669135.
- Poulin, R. and Morand, S., 2000.** The diversity of parasites. *Quarterly Review of Biology*, 75, 277-293. PMID:11008700.
- Riffkin, M., Seow, H. F., Jackson, D., Brown, L. and Wood, P., 1996.** Defence against the immune barrage: Helminth survival strategies. *Immunology and Cell Biology*, 74(5), 564-574. PMID:8989595.
- Rohde, K., 2002.** Ecology and biogeography of marine parasites. *Advances in Marine Biology* (Academic Press), 43(1e), 1-83. Doi: 10.1016/S0065-2881(02)43002-7.
- Scholz, T., 1999.** Parasites in cultured and feral fish. *Veterinary Parasitology* 84,317-335. Doi: 10.1016/S0304-4017(99)00039-4.
- Sparks, A. K. and Fontaine, C. T., 1973.** Host response in the white shrimp, *Penaeus setiferus*, to infection by the larval trypanorhynchid cestode, *Prochristianella penaei*. *Journal of Invertebrate Pathology*. 22(2), 213-219. Doi: 10.1016/0022-2011(73)90136-5.