

Research Article

# Molecular detection and histopathological characterization of koi herpesvirus disease in carp farm mortalities in the Susangerd region

Alishahi M.<sup>1</sup>, Ghobadian Diali H.<sup>2\*</sup>, Moftakhar P.<sup>1</sup>, Rezaei A.<sup>2</sup>, Mohammadian T.<sup>1</sup>

1Department of Aquatic Health, Faculty of Veterinary Medicine, Shahid Chamran University of Ahvaz, Ahvaz, Iran

2Department of Pathobiology, Faculty of Veterinary Medicine, Shahid Chamran University of Ahvaz, Ahvaz, Iran

\*Correspondence: h.ghobadian62@gmail.com

## Keywords

Viral infection,  
Carp,  
Koi herpesvirus disease,  
*Cyprinid herpesvirus 3*

## Abstract

Viral infections pose a significant challenge to modern aquaculture. Among these, koi herpesvirus disease (KHVD) causes significant economic losses in carp aquaculture. KHVD is a highly contagious and emerging disease that causes significant mortality in common carp and koi. It is caused by *Cyprinid herpesvirus 3* (CyHV-3), commonly known as “koi herpesvirus.” The World Organization for Animal Health has classified KHVD as a notifiable infectious disease since 2007, emphasizing the need for early detection and reporting to facilitate effective disease management. This study aimed to detect KHVD at the molecular level and conduct a histopathological examination of suspected carp farm mortalities in the Susangerd region (Khuzestan, Iran). Gill tissue samples were collected from infected fish at affected farms, followed by molecular assays and pathological analyses to identify CyHV-3. This study represents the first confirmed detection of KHV in carp farm mortalities in the region using clinical, histopathological, and molecular investigations. Clinically, infected fish exhibited lethargy, erratic swimming, congregation on the surface of the water, movement along the pond’s perimeter, frequent gasping for air, occasional excessive mucus production on the skin, and sunken eyes before death. The histopathological analysis revealed gill tissue abnormalities, including hyperplasia, congestion, and intranuclear inclusions with chromatin margination. Additionally, the sequence analysis of the polymerase chain reaction (PCR) product confirmed CyHV-3 as the causative agent of these mortalities. The sequenced viral product was submitted to GenBank under accession number PQ120584.

## Article info

Received: January 2025

Accepted: April 2025

Published: July 2025



Copyright: © 2025 by the authors. Licensee MDPI, Basel, Switzerland. This article is an open access article distributed under the terms and conditions of the Creative Commons Attribution (CC BY) license (<https://creativecommons.org/licenses/by/4.0/>).

## Introduction

With a rapidly growing human population, the aquaculture sector has become a significant contributor to sustainable food production. It is increasingly recognized for its ability to meet the increasing demand for protein while offering a more environmentally sustainable alternative to conventional livestock production. Beyond its ecological advantages, aquaculture holds significant economic importance, playing a crucial role in food security, employment generation, and rural development. Research suggests that by 2050, aquaculture is expected to account for more than 60% of global seafood production, making it a key component of the international food supply chain (FAO, 2020).

However, this industry faces numerous challenges, particularly infectious diseases (such as viral infections) that can cause significant economic losses worldwide (Kibenge, 2019; Mugimba *et al.*, 2021). In the late 1990s, *Cyprinid herpesvirus 3* (CyHV-3) emerged as the causative agent of a highly contagious viral disease known as koi herpesvirus disease (KHVD). This disease spread rapidly, causing significant economic damage to the common carp, koi industries, and their hybrids. The virus has been documented in nearly every region worldwide, with the exceptions of South America and Australia. Its global spread is primarily attributed to the unrestricted and unregulated transit and trade of fish, particularly koi, which are often asymptotically infected (Bavarsad *et al.*, 2024).

KHVD belongs to the genus *Cyprinivirus* in the family

*Alloherpesviridae* and order *Herpesvirales*. It was previously identified as carp interstitial nephritis and gill necrosis virus (King *et al.*, 2011). Like other herpesviruses, CyHV-3 infects cells through 2 primary mechanisms: lytic and latent infections. In the lytic cycle, the virus replicates and produces offspring virions, ultimately causing cell lysis. During latency, the virus remains dormant without active replication or viral particle production, persisting as an uncoordinated episome while exhibiting minimal viral activity and microRNA expression (Donohoe, 2013). Lytic replication can be reactivated under specific conditions, primarily influenced by temperature and stress factors. The latent genome levels of CyHV-3 have been estimated to range from 2 to 150 copies per microgram of total DNA (Eide *et al.*, 2011), with polymorphonuclear granulocytes and IgM<sup>+</sup> B cells serving as primary reservoirs of viral persistence (Bergmann *et al.*, 2010a; Reed *et al.*, 2014).

KHVD outbreaks typically occur in water temperatures between 18 and 28°C, making them seasonal (Gotesman *et al.*, 2013). The virus spreads horizontally through direct physical contact with infected or carrier fish, as well as via necrophagous behavior in carp. Indirect or vector-mediated transmission pathways include aquatic invertebrates, sediment, piscivorous birds, water (as the primary abiotic vector), fish waste, and plankton. Additionally, mating behavior may facilitate viral transmission by suppressing immune responses and aggregating infected fish. To date, there is no evidence

supporting vertical transmission of CyHV-3 (Bavarsad *et al.*, 2024).

Currently, 4 distinct CyHV-3 strains have been identified in different regions: the Israeli strain (CyHV-3 I), the Japanese strain (CyHV-3 J), the US strain (CyHV-3 U) (Aoki *et al.*, 2007), and the Chinese strain (CyHV-3 GZ11) (Li *et al.*, 2015). Despite their geographical separation, the CyHV-3 I, J, and U strains exhibit nearly 100% genetic similarity (Radosavljević *et al.*, 2017). Although the CyHV-3 GZ11 strain originates primarily from the Asian lineage, it also contains small genetic elements from the European lineage (Li *et al.*, 2015). Additionally, 9 distinct genotypes of CyHV-3 have been identified: 2 from Asia (A1 and A2) and 7 from Europe (E1–E7) (Kurita *et al.*, 2009). These genotypic variations result from minor genetic modifications, which appear to be normal and do not significantly impact the virus's ability to replicate or cause disease in common carp (Bergmann *et al.*, 2020).

KHVD has significant consequences for aquaculture, affecting wild fish populations, biodiversity, employment, and various ecological and socioeconomic factors. Due to its devastating impact, the World Organization for Animal Health classified KHVD as a notifiable disease in 2007, requiring the mandatory reporting of outbreaks (Gotesman *et al.*, 2014; Bavarsad *et al.*, 2024). Several reports have documented the presence of this virus in fish farm mortalities across Iran (Rahmati-Holasoo *et al.*, 2016; Taheri Mirghaedi *et al.*, 2019; Ahmadiwand *et al.*, 2020; Shahvazi *et al.*, 2022). However, to the best of our knowledge, no published

studies have confirmed its occurrence in fish farm mortalities in the Susangerd region (Khuzestan, Iran). This study aimed to detect KHVD at the molecular level and perform a histopathological examination of suspected carp mortalities in the Susangerd region.

## Materials and methods

### Sampling

In spring 2024, dead fish from carp farms in the Susangerd region were submitted to the Aquatic Animal Department, Faculty of Veterinary Medicine, Shahid Chamran University of Ahvaz due to widespread mortalities. All examined fish exhibited consistent clinical signs, including gill hyperemia, necrosis, and sunken eyes (Fig. 1).

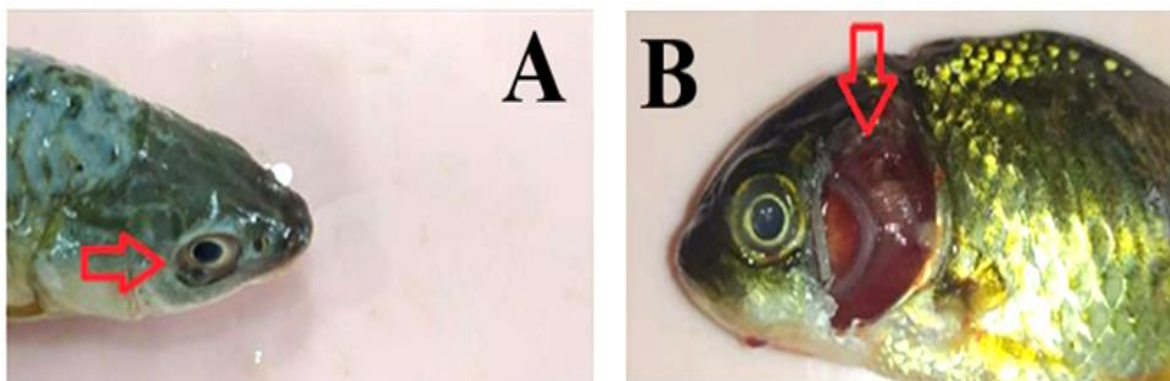
Farm owners reported pre-mortality symptoms, such as lethargy, erratic swimming, congregation on the surface of the water, movement along pond edges, frequent gasping for air, and occasional excessive mucus secretion on the skin. Based on these observations and the clinical signs seen in the dead fish, a preliminary diagnosis of KHVD was strongly suspected. To confirm the diagnosis, polymerase chain reaction (PCR) assays and histopathological investigations were conducted. Gill tissue samples were collected separately from dead fish originating from each affected farm.

### Histopathological studies

For histological examinations, gill samples were dissected, fixed in 10% buffered formalin, dehydrated, and embedded in paraffin using a paraffin tissue processor

(DS 2080/H; Did Sabz Co., Iran) and a paraffin dispenser (DS 4LM; Did Sabz Co., Iran). Tissue sections were cut at 5- $\mu$ m thickness using a rotary microtome

(RM2145; Leica, Germany), stained with hematoxylin and eosin, and examined under a light microscope (E600; Nikon, Japan).



**Figure 1: Clinical signs observed in affected fish. (A) Sunken eyes and (B) gill hyperemia.**

#### *PCR detection*

Nested PCR was used to detect CyHV-3. The gill tissue samples from 3 fish per farm were pooled and homogenized separately. DNA was extracted from each pooled sample using a commercial DNA extraction kit (Raha Zist Padtan, Iran)

following the manufacturer's instructions. The Nested PCR was conducted using primers targeting the polymerase gene (Table 1) and an amplicon master mix.

**Table 1: Primer sequences used in this study.**

Primer name	Sequence (5' to 3')	Product size
CyHVpolF1	CCAGCAACATGTGCGACGG	362 bp
CyHVpolR1	CCGTARTGAGAGTTGGCGCA	
CyHVpolF2	CGACGGVGGYATCAGCCC	
CyHVpolR2	GAGTTGGCGCAYACYTTCATC	339 bp

*The PCR cycling conditions were as follows:*

Initial denaturation: 95°C for 3 minutes; amplification (40 cycles): 95°C for 30 seconds (denaturation), 55°C for 30 seconds (annealing), 72°C for 45 seconds (extension); and final extension: 72°C for 10 minutes (Engelsma *et al.*, 2013). Each PCR contained 12.5  $\mu$ L of amplicon master mix (2X), 3  $\mu$ L of template DNA, 1  $\mu$ L of each 10 $\mu$ M primer, and nuclease-

free water, making up a final volume of 25  $\mu$ L. In the PCR assays, distilled water was used as the negative control, while DNA extracted from carp mortalities attributed to CyHV-3 in Gilan province (provided by the Department of Virology, Faculty of Veterinary Medicine, University of Tehran) was used as the positive control. Following PCR, the amplified products were analyzed using gel electrophoresis on a 1.5% agarose gel containing a safe DNA

stain (CinnaGen, Iran), alongside a 100-base pairs (bp) DNA molecular weight marker (CinnaGen, Iran). Electrophoresis was conducted at 100 V for 40 minutes, and DNA bands were visualized using a UV transilluminator (Uvtec, England).

#### *Sequencing of PCR products and phylogenetic analyses*

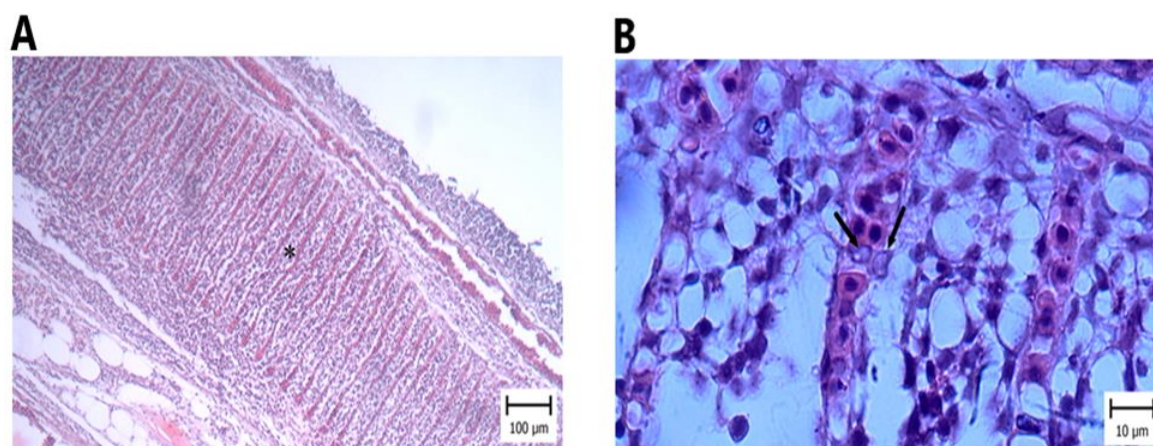
A representative amplicon of approximately 339 bp, generated through nested PCR, was submitted to Gene Fanavaran Company for Sanger dideoxy sequencing along with the corresponding nested primer pairs. Upon receiving the raw sequence data, manual curation and editing were performed using the BioEdit sequence alignment editor version 7.2.5.0. To ensure the accuracy of the obtained nucleotide sequence, a BLAST (basic local

alignment search tool) analysis was conducted. Finally, phylogenetic analyses were performed using the Molecular Evolutionary Genetics Analysis (MEGA X) software package. The analyzed nucleotide sequence was aligned with CyHV-3 sequences and other carp-associated herpesvirus sequences (including types 1 and 2) from various geographical origins, followed by a phylogenetic evaluation.

## **Results**

### *Histopathology*

Histopathological analysis of the gills revealed hyperplasia and congestion (Fig. 2A). Additionally, intranuclear inclusions with chromatin margination were observed in some cells (Fig. 2B).



**Figure 2:** Carp infected with KHV. (A) Hyperplasia and congestion (indicated by the star) and (B) intranuclear inclusions with chromatin margination (indicated by the arrow).

### *PCR results*

Based on the molecular analysis of 3 composite gill tissue samples (each consisting of pooled gill tissue from 3 individual fish per farm), all 3 samples tested positive by nested PCR, producing

an amplified product of approximately 339 bp (Fig. 3).

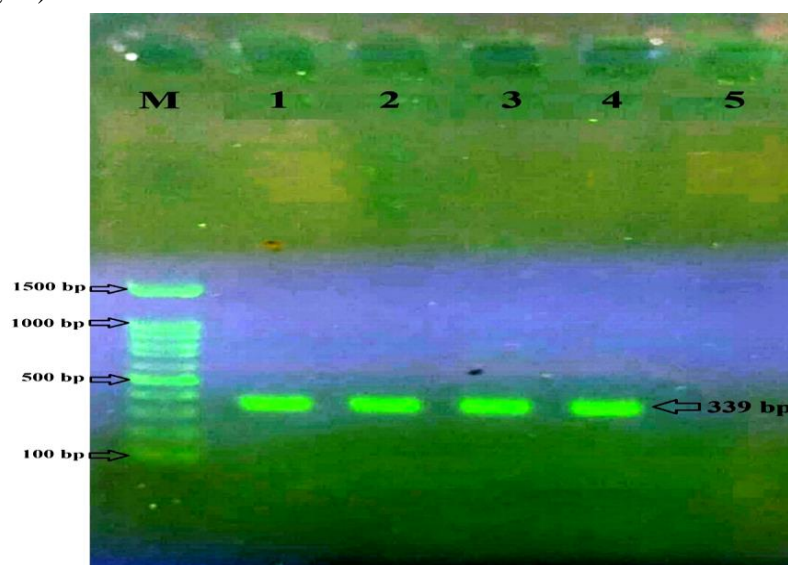
### *Sequence analysis and phylogenetic*

The sequence analysis of the PCR amplicon, combined with a preliminary BLAST analysis, revealed a high degree of

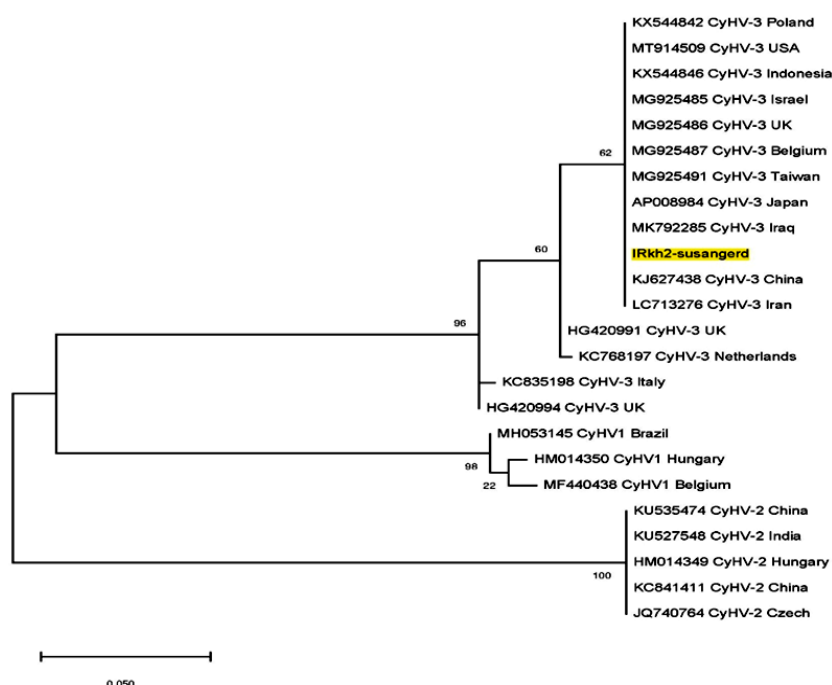


sequence homology between the studied isolate (designated IRKh2-Susangerd) and previously characterized CyHV-3 isolates. Multiple nucleotide sequence alignments and subsequent phylogenetic tree construction (Fig. 4) further confirmed the

identification of the isolate as CyHV-3. The isolate was assigned GenBank accession number PQ120584 for public access.



**Figure 3:** Nested PCR results were visualized on an agarose gel. The expected 339-bp product was successfully amplified in the positive control (lane 1) and all farm samples (lanes 2–4), confirming the presence of the target sequence. No amplification was detected in the negative control (lane 5), ensuring assay specificity. Lane M contains a 100-bp DNA ladder for size reference.



**Figure 4:** Phylogenetic analysis. The phylogenetic analysis illustrates the placement of the sequenced PCR product, IRKh2-Susangerd (highlighted in yellow), within a phylogenetic tree constructed using sequences of carp herpesvirus types 1, 2, and 3 retrieved from GenBank.

## Discussion

CyHV-3 poses a significant threat to both common carp and koi farming, leading to increased mortality rates and a serious risk to the sustainability of carp aquaculture. Due to its devastating impact, the World Organization for Animal Health classified KHVD as a notifiable disease in 2007, requiring the mandatory reporting of outbreaks (Gotesman *et al.*, 2014; Bavarsad *et al.*, 2024). While CyHV-3 has been reported in various regions of Iran in connection with fish farm mortality (Rahmati-Holasoo *et al.*, 2016; Taheri Mirghaed *et al.*, 2019; Ahmadvand *et al.*, 2020; Shahvazi *et al.*, 2022), our study is the first to directly link this virus to carp farm mortality in the Susangard region.

The disease is characterized by symptoms such as sunken eyes, increased mucus production, and pale or necrotic gills, with affected organs showing viral intranuclear inclusion bodies (Gotesman *et al.*, 2013; Rahmati-Holasoo *et al.*, 2016). Similar clinical signs were observed in the present study. KHVD is a globally distributed disease that affects carp, excluding Australia and South America (Bavarsad *et al.*, 2024). Although the presence of CyHV-3 had been previously reported, its official confirmation in Iran was made in 2021 by the Iran Veterinary Organization. The first documented case in Iran was reported by Rahmati-Holasoo *et al.* (2016), with the virus initially detected in koi juveniles and broodstock at ornamental fish breeding sites in Tehran province using clinical, histological, and molecular (nested PCR) tests. Subsequent studies across Iran, including Tehran, Alborz, Mazandaran, and Isfahan

provinces, confirmed the presence of CyHV-3 (Ahmadvand *et al.*, 2020; Bavarsad *et al.*, 2024).

Further clinical and molecular research by Taheri Mirghaed *et al.* (2019) on carp mortality incidents in Khuzestan and Gilan provinces (2015–2016) also confirmed the presence of KHVD in specific aquaculture facilities in those regions. However, the exact counties in Khuzestan province where the samples were collected were not specified. In contrast, Shahvazi *et al.* (2022) used molecular (nested PCR) methods to identify CyHV-3 in southern Khuzestan farms, including those near Ahvaz city. Our study represents the first documented instance of KHVD-related fatalities in carp farms in western Khuzestan province, specifically in Susangerd, the administrative center of the Dasht-e Azadegan region.

The cell culture-based isolation of CyHV-3 remains challenging and does not consistently provide accurate diagnoses of KHVD (Haenen *et al.*, 2004). Currently, the most reliable and efficient diagnostic method is PCR. Several studies have demonstrated that PCR-based techniques are the most sensitive for detecting CyHV-3 (Haenen *et al.*, 2004; Bergmann *et al.*, 2010b; Monaghan *et al.*, 2015). Notably, the thymidine kinase gene-based PCR assay is as sensitive as the virus isolation method, the gold standard for KHV diagnosis. It can detect as little as 10 femtograms of KHV DNA, corresponding to just 30 virions (Bercovier *et al.*, 2005; Rahmati-Holasoo *et al.*, 2016). When combined with sequencing, this PCR method also allows for accurate identification of genotype isolates from

both Asian (Japan strain) and European (Israel and USA strains) origins (Kurita *et al.*, 2009; Dong *et al.*, 2011).

Rahmati-Holasoo *et al.* (2016) and Ahmadvand *et al.* (2020) used TK gene-based PCR testing to detect and genotype CyHV-3 in various Iranian regions, consistently finding the Asian genotype in all samples. In contrast, Taheri Mirghaied *et al.* (2019) and Shahvazi *et al.* (2022) used a DNA polymerase gene-based PCR test to detect and identify the virus in other parts of Iran. Similarly, the present study employed a polymerase gene-based PCR test to identify CyHV-3 in carp mortality cases in the Susangerd region. Although the DNA polymerase gene is highly conserved within the family *Alloherpesviridae* (van Beurden *et al.*, 2010), it is unsuitable for CyHV-3 genotyping, meaning our findings may not accurately reflect the circulating genotypes in the Susangerd region. This highlights the need for further research to identify the virus's genotypes in the region.

Although the TK gene-based PCR test offers excellent sensitivity and accuracy for virus detection and genotyping, Engelsma *et al.* (2013) found that it fails to detect certain strains of the virus that can be identified with the polymerase gene-based PCR assay. Therefore, we recommend using both TK gene-based and polymerase gene-based PCR tests for optimal detection.

KHVD is a rapidly emerging disease that poses a serious threat to the cyprinid aquaculture industry. Currently, there is no available treatment to save infected fish, and legislative restrictions on the potential reactivation or return to virulence of the

virus have prevented the introduction of a vaccine for global use (Bavarsad *et al.*, 2024). Aquaculture facilities and hatcheries must adhere to strict biosecurity measures to prevent CyHV-3's spread, including viral testing before fish import and export, restricting fish movement, and thoroughly sanitizing equipment. Predictive algorithms may also be developed to identify high-risk infection zones, enabling more targeted resource allocation for monitoring. The presence of CyHV-3 has already been reported in Iranian aquaculture. Moreover, the unregulated importation of ornamental fish and live aquatic animals, especially goldfish, increases the risk of the virus spreading to carp farms (Bavarsad *et al.*, 2024).

## Conclusions

Given the aforementioned risks, researchers must investigate and implement targeted measures to prevent the potentially catastrophic consequences of CyHV-3's entering Iran's aquaculture sector. Our findings reveal the initial identification of KHVD in specific farms located in the western Khuzestan province, specifically in the Susangerd region. These results highlight the need for urgent attention from fish farmers, veterinarians, and the Iranian Veterinary Organization to ensure the implementation of preventive measures and the optimal use of available resources. Given the heightened vulnerability of carp to KHVD and its significant economic impact, regular surveillance of carp farms is essential. Additionally, it is crucial to provide training to farm owners on effective



control strategies to reduce the spread of the disease. Furthermore, considering the ability of herpesviruses like CyHV-3 to cause latent infections, conducting molecular assays to detect this virus in licensed fry supplier farms across the country and issuing certifications will help curb the disease's spread. Detecting the virus in its latent phase is challenging due to its low concentration, so ongoing research to develop more accurate and sensitive diagnostic tools is essential.

### Acknowledgment

The authors extend their sincere appreciation to the Department of Virology, Faculty of Veterinary Medicine, University of Tehran, for generously providing the positive control DNA essential for the successful completion of this study.

### Conflicts of interest

The authors hereby declare that there are no conflicts of interest regarding the publication of this manuscript.

We confirm that the research was conducted impartially, and all authors contributed to the study without any external influence that could potentially compromise the integrity of the research.

### References

- Ahmadivand, S., Soltani, M., Shokrpour, S., Rahmati-Holasoo, H., El-Matbouli, M. and Taheri-Mirghaed, A., 2020. Cyprinid herpesvirus 3 (CyHV-3) transmission and outbreaks in Iran: Detection and characterization in farmed common carp. *Microbial Pathogenesis*, 149, 104321.
- DOI:10.1016/j.micpath.2020.104321
- Aoki, T., Hirono, I., Kurokawa, K., Fukuda, H., Nahary, R., Eldar, A., Davison, A.J., Waltzek, T.B., Bercovier, H. and Hedrick, R.P., 2007. Genome sequences of three koi herpesvirus isolates representing the expanding distribution of an emerging disease threatening koi and common carp worldwide. *Journal of Virology*, 81, 5058-5065. DOI:10.1128/jvi.00146-07
- Bavarsad, M., Abed-Elmdoost, A., Tabandeh, M., Farahmand, H., Alishahi, M., Mirvaghefi, A., Avazeh, A., Adel, M., Jafari, A. and Zorriehzahra, M., 2024. Cyprinid herpesvirus 3 (CyHV-3), koi herpes virus disease (KHVD) and their current status in Iran: A review. *Iranian Journal of Fisheries Sciences*, 23, 783-802. DOI:10.22092/ijfs.2024.131748
- Bercovier, H., Fishman, Y., Nahary, R., Sinai, S., Zlotkin, A., Eyngor, M., Gilad, O., Eldar, A. and Hedrick, R.P., 2005. Cloning of the koi herpesvirus (KHV) gene encoding thymidine kinase and its use for a highly sensitive PCR based diagnosis. *BMC Microbiology*, 5, 1-9. DOI:10.1186/1471-2180-5-13
- Bergmann, S., Sadowski, J., Kielpiński, M., Bartłomiejczyk, M., Fichtner, D., Riebe, R., Lenk, M. and Kempter, J., 2010a. Susceptibility of koi× crucian carp and koi× goldfish hybrids to koi herpesvirus (KHV) and the development of KHV disease (KHVD). *Journal of fish diseases*, 33, 267-272.

- Bergmann, S.M., Riechardt, M., Fichtner, D., Lee, P. and Kempter, J., 2010b.** Investigation on the diagnostic sensitivity of molecular tools used for detection of koi herpesvirus. *Journal of Virological Methods*, 163, 229-233. DOI:10.1016/j.jviromet.2009.09.025
- Bergmann, S.M., Jin, Y., Franzke, K., Grunow, B., Wang, Q. and Klafack, S., 2020.** Koi herpesvirus (KHV) and KHV disease (KHVD)—a recently updated overview. *Journal of Applied Microbiology*, 129, 98-103. DOI:10.1111/jam.14616
- Dong, C., Weng, S., Li, W., Li, X., Yi, Y., Liang, Q. and He, J., 2011.** Characterization of a new cell line from caudal fin of koi, *Cyprinus carpio* koi, and first isolation of cyprinid herpesvirus 3 in China. *Virus research*, 161, 140-149. DOI:10.1016/j.virusres.2011.07.016
- Donohoe, O., 2013.** An investigation into the existence of Cyprinid Herpesvirus 3 encoded microRNAs. *Dublin City University*, Ireland, 342 P.
- Eide, K., Miller-Morgan, T., Heidel, J., Bildfell, R. and Jin, L., 2011.** Results of total DNA measurement in koi tissue by Koi Herpes Virus real-time PCR. *Journal of virological methods*, 172, 81-84. DOI:10.1016/j.jviromet.2010.12.012
- Engelsma, M.Y., Way, K., Dodge, M.J., Voorbergen-Laarman, M., Panzarin, V., Abbadi, M., El-Matbouli, M., Skall, H.F., Kahns, S. and Stone, D.M., 2013.** Detection of novel strains of cyprinid herpesvirus closely related to koi herpesvirus. *Diseases of Aquatic Organisms*, 107, 113-120. DOI:10.3354/dao02666
- Food and Agriculture Organization (FAO), 2020.** The State of World Fisheries and Aquaculture 2020: Sustainability in action. *FAO, Rome*. 30 P. DOI:10.4060/ca9229en
- Gotesman, M., Kattlun, J., Bergmann, S.M. and El-Matbouli, M., 2013.** CyHV-3: the third cyprinid herpesvirus. *Diseases of aquatic organisms*, 105, 163-174. DOI:10.3354/dao02614
- Gotesman, M., Soliman, H., Besch, R. and El-Matbouli, M., 2014.** In vitro inhibition of Cyprinid herpesvirus-3 replication by RNAi. *Journal of virological methods*, 206, 63-66. DOI:10.1016/j.jviromet.2014.05.022
- Haenen, O., Way, K., Bergmann, S. and Ariel, E., 2004.** The emergence of koi herpesvirus and its significance to European aquaculture. *Bulletin of the European Association of Fish Pathologists*, 24, 293-307.
- Kibenge, F.S., 2019.** Emerging viruses in aquaculture. *Current Opinion in Virology*, 34, 97-103. DOI:10.1016/j.coviro.2018.12.008
- King, A.M., Lefkowitz, E., Adams, M.J. and Carstens, E.B., 2011.** Virus taxonomy: *ninth report of the International Committee on Taxonomy of Viruses*, Elsevier, 9, 108.
- Kurita, J., Yuasa, K., Ito, T., Sano, M., Hedrick, R.P., Engelsma, M.Y., Haenen, O.L., Sunarto, A., Kholidin, E.B. and Chou, H.-Y., 2009.** Molecular epidemiology of koi herpesvirus. *Fish Pathology*, 44, 59-66. DOI:10.3147/jsfp.44.59

- Li, W., Lee, X., Weng, S., He, J. and Dong, C., 2015.** Whole-genome sequence of a novel Chinese cyprinid herpesvirus 3 isolate reveals the existence of a distinct European genotype in East Asia. *Veterinary microbiology*, 175, 185-194. DOI:10.1016/j.vetmic.2014.11.022
- Monaghan, S., Thompson, K., Adams, A. and Bergmann, S.M., 2015.** Sensitivity of seven PCR s for early detection of koi herpesvirus in experimentally infected carp, *Cyprinus carpio* L., by lethal and non-lethal sampling methods. *Journal of Fish Diseases*, 38, 303-319. DOI:10.1111/jfd.12235
- Mugimba, K.K., Byarugaba, D.K., Mutoloki, S., Evensen, Ø. and Munang'andu, H.M., 2021.** Challenges and solutions to viral diseases of finfish in marine aquaculture. *Pathogens*, 10, 673. DOI:10.3390/pathogens10060673
- Radosavljević, V., Maksimović-Zorić, J., Veljović, L., Ljubojević, D., Ćirković, M., Marković, Z. and Milićević, V., 2017.** Cyprinid herpesvirus diseases. *Arhiv veterinarske medicine*, 10, 51-60. DOI:10.46784/e-avm.v10i1.81
- Rahmati-Holasoo, H., Zargar, A., Ahmadvand, S., Shokrpour, S., Ezhari, S. and Ebrahimzadeh Mousavi, H., 2016.** First detection of koi herpesvirus from koi, *Cyprinus carpio* L. experiencing mass mortalities in Iran: clinical, histopathological and molecular study. *Journal of fish diseases*, 39, 1153-1163. DOI:10.1111/jfd.12448
- Reed, A.N., Izume, S., Dolan, B.P., LaPatra, S., Kent, M., Dong, J. and Jin, L., 2014.** Identification of B cells as a major site for cyprinid herpesvirus 3 latency. *Journal of Virology*, 88, 9297-9309. DOI:10.1128/jvi.00990-14
- Shahvazi, S., Rezaii, A., Seifiabadshapoori, M.R., Alishahi, M. and Ahangarzadeh, M., 2022.** Molecular study of Koi herpesvirus in warm-water fish farms mortality in Khuzestan province. *Iranian Scientific Fisheries Journal*, 31, 129-138. DOI:10.22092/isfj.2022.127732 (In Persian)
- Taheri Mirghaed, A., Enayati, A., Soltani, M., Alishahi, M., Rahmati-Holasoo, H., Haghighi Kaibanian Asl, A. and Hosseini Shekarabi, P., 2019.** Study of Koi Herpes Virus Disease (KHVD) in Some Carp farm of Iran: A Molecular and Pathological Study. *Iranian Veterinary Journal*, 15, 69-78
- Van Beurden, S.J., Bossers, A., Voorbergen-Laarman, M.H., Haenen, O.L., Peters, S., Abma-Henkens, M.H., Peeters, B.P., Rottier, P.J. and Engelsma, M.Y., 2010.** Complete genome sequence and taxonomic position of anguillid herpesvirus 1. *Journal of General Virology*, 91, 880-887. DOI:10.1099/vir.0.016261-0