

Research Article



Efficiency of dietary black seed (*Nigella sativa*) essential oil for incisional skin wound healing in goldfish (*Carassius auratus*)

Khaleghi H.¹; Sattari A.^{2*}; Azizi S.³; Sharifpour I.⁴

Received: November 2021

Accepted: October 2022

Abstract

This study evaluated the healing effect of black seed essential oil (*Nigella sativa*; NS) dietary supplementation on skin wound in goldfish (*Carassius auratus*). Some 48 goldfish were divided into 4 groups, including the control and 3 treatment groups in three replications and kept for study period of 7 days. NS essential oil was added to the basal diet of treatment groups at the concentration of 2% for the NS2 group, 4% for the NS4 group, and 6% for the NS6 group. The control group was fed the basal diet without NS during the experimental period. The 5 mm incision made by scalpel on the right flank of all fishes below the dorsal fin above the lateral line. The fish fed three times a day with assigned diet for a week. Histological investigations approved the effects of NS essential oil on skin wound healing. Diet with 6% concentration of NS6 revealed the improved healing outcomes such as re-epithelialization, muscle regeneration and scale formation rather than NS2 and NS4 groups.

Keywords: Black seed (*Nigella sativa*), *Carassius auratus*, Dietary, Healing, Skin wound

1-Shahid Bahonar University of Kerman, Kerman, Iran.

2-Department of Food Hygiene and Public Health, Shahid Bahonar University of Kerman, Kerman, Iran.

3-Department of Pathobiology, Faculty of Veterinary Medicine, Shahid Bahonar University of Kerman, Kerman, Iran.

4-Iranian Fisheries Sciences Research Institute, Agricultural Research, Education and Extension Organization, Tehran, Iran.

*Corresponding author's Email: amirsatari@uk.ac.ir

Introduction

Cutaneous wound is the most common disorder in fish that significantly increases morbidity and mortality due to access of various pathogens and predators to underlying tissues (Schmidt, 2013; Coutant *et al.*, 2019). The immediate treatment of wounds is substantial for reasons such as repairing integumentary adaptations to aquatic habitats and preventing tissues contaminations (Richardson *et al.*, 2013; Schmidt, 2013). Suboptimal conditions in aquariums make the ornamental goldfish (*Carassius auratus*) susceptible to bacterial diseases. Also cultured fish will be suffering from superficial injuries and different stressors as a result of intensification in fish farms (Brown *et al.*, 2018; Reyes, 2019). Recently, nutritional scientists used medicinal plants and their bioactive principles or extracts for many different purposes in aquaculture farms. They exhibited various advantageous properties such as growth-promoting, antimicrobial, immunostimulant, antioxidants, and hepatoprotective activities. Growth promotion, appetite and immune stimulation and antimicrobial and anti-stress properties are some of the biological activities of medicinal plants in aquatic organisms (Citarasu, 2010; Chakraborty and Hancz, 2011; Awad and Awaad, 2017). Black cumin (*Nigella sativa*) and its derivatives have some beneficial therapeutic features for farmed fish. Black seeds contain thymoquinone with anti-cancer, anti-inflammatory and immune-boosting properties and carotene that can be

converted to vitamin A (required in cell growth and skin healthy) (Abd El-Hack *et al.*, 2021). In case of cutaneous injuries, healing agents must be available and the dietary supplementation of medical plants acts as alternative (Jinendiran *et al.*, 2019).

The wound healing effects of black seed essential oil in fish species have not been widely investigated yet. However, the antibacterial efficacy of black seed on fresh fish (*Barbus grypus*) fillets during storage has been proved by Ozpolat and Duman (2016). Considering the sequence and frequency of skin injuries of fish in different breeding systems caused by manipulations, transportation, density, parasitic factors, etc. The present study investigates the role of oral use of black seed essential oil as a feasible and less stressful method in the healing process of skin incisional wounds of goldfish.

Materials and methods

Fish

A total of 48 healthy goldfish were bought and transferred to Aquatic Laboratory of Veterinary Faculty, Shahid Bahonar University of Kerman. The goldfish are considered free of diseases by general observation and macroscopic and microscopic wet mount examination of skin investigations. The fish were maintained in 100 L water rectangular aquarium for 7 days of acclimation period. Water quality characteristics during the experimental period were as follow: temperature ($28.3 \pm 0.1^\circ\text{C}$), pH (7.3 ± 0.2), and dissolved oxygen (6.3 ± 0.3 mg/L). The

fish were fed three times a day at the rate of 5% of their body weight. Uneaten feeds and feces were siphoned daily, and a water exchange of (25-50%) was performed every two days. The day/night cycle was kept at a constant change of 12h light/ 12h dark.

Experimental design

Forty-eight fish (8.5 ± 1.8 g) were divided randomly into four main groups of 12 fish (each group with three replications of 4 fish) in separate aquaria (45×15 cm) as control and 3 treatment groups including NS2 (2% concentration of NS oil), NS4 (4% concentration of NS) and NS6 (6% concentration of NS) provided with aerator. In order to study the efficacy of feasible and reliable parenteral treatment method on wound healing, the essential oil of NS (Barij Essence Co., Kashan, Iran) was sprayed evenly on and mixed well with the feed grains (Energy®, Thailand, protein: 28%, Fat 3%, Fiber 4%, Moisture 10%) at the levels of 2, 4 and 6 g/100g diet after wounding and fed twice a day (Dorucu *et al.*, 2009).

Skin wounding procedure

All fish were fasted 24 hours before anesthesia with 50 PPM solution of clove oil for 5 min. Each individual was placed in lateral recumbency out of water for the wounding procedure once a surgical plane of anesthesia was achieved (Sladky *et al.*, 2001). Then sterile disposable scalpel was used to gently remove scales on the incision area of skin before wounding and the exposed

skin was flushed thoroughly with sterile saline solution (0.9% sodium chloride).

A 5 mm horizontal wound was made by a disposable scalpel into the right dorsal myotomal muscle of each anesthetized fish just below the dorsal fin with the depth of whole skin thickness to subcutaneous muscle in the control and treatment groups. After wounding, fish were returned to the aquaria where they were kept under observation for the gross appearance of wound site healing for a week until sacrificed.

In order to prevent the missing microscopic early and rapid differences in the healing tissue between treatment and control groups and based on the gross visual differences of wound sites after 7 days, the decision was made to euthanize the fish a using high concentration of clove oil for subsequent microscopic examinations. However, the continued periods of investigations are performed on another fish type by Sveen *et al.* (2018). Skin and underlying muscle samples were taken with 5 mm margin and fixed in 10% neutral buffered formalin for at least 24 hours, then embedded in paraffin, sectioned at 5µm and stained with hematoxylin and eosin (Merk®, cat. No. 1.5938, Germany) stain.

Photography

The gross wound photos were taken using a digital camera (Panasonic®-Lumix DMC-Lx3 Fk8HA002283, Japan) on day 7 after wounding and microscopic imaging was performed from the stained tissue slides by means

of Nikon® (Eclipse50i Digital camera, Japan) afterward.

Results

Pathologic findings

The 7th day after wounding, macroscopic observations showed wound closure, reduction of the size of the wound, and hyperemia in the fish fed

with different concentrations of NS oil supplemented diets in comparison with the control group. The control wounds were more hyperemic with edematous margins. Between the treatment groups, fish fed with 6% concentration of NS oil had more efficacy and the incision lines had almost faded (Fig. 1).

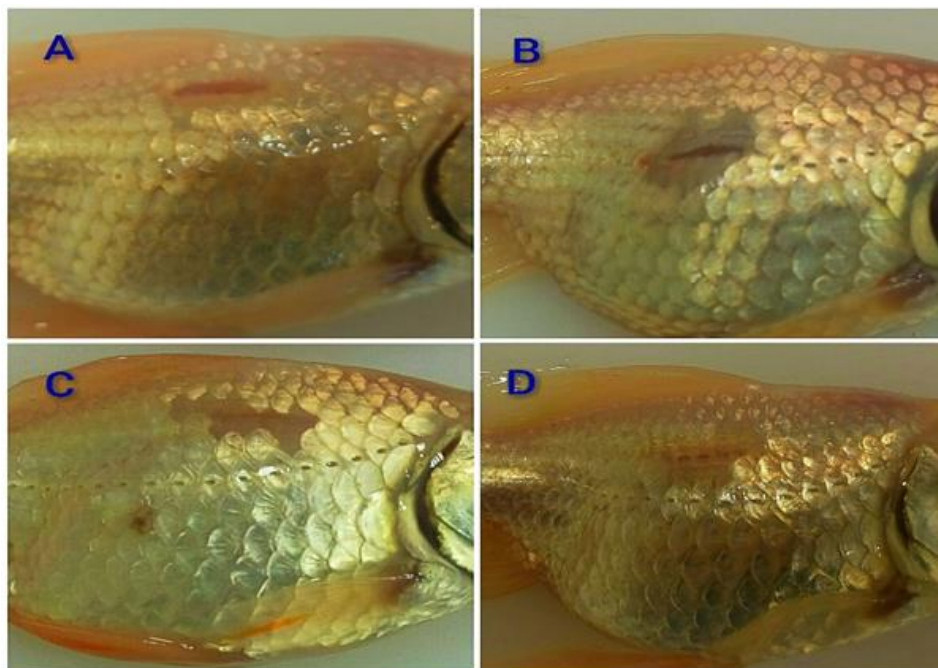


Figure 1: Gross appearance of wound healing 7 days after incision. A: skin wound healing of control group, B: 2% oral NS (NS2), C: 4% oral NS (NS4), D: 6% oral NS (NS6).

At 7th day post wounding, some parameters were observed in all wounds of the control and treatment groups. All wounds were completely re-epithelialized and covered with a new multiple-layer epidermis. Mucous cells were present in the surface of the new epidermis. Melanin pigments were also scattered throughout the thickness of the epidermis.

In the control group, the epidermis was thickened and irregular in different parts. In the dermis layer, formation of granulation tissue was poor.

Inflammatory cells were dispersed among disintegrated muscular fibers. Weak regeneration of muscular tissue was observed in this group.

Treated groups that were fed with NS oil supplemented diet in 3 different concentrations showed distinguished wound healing in a dose-dependent manner. In the NS6 group, the new epidermis was more resemble to the intact skin with enclosed scale pockets and scales within them. Under the epidermis layer, collagen fibers were regressed and substituted with

regenerated muscular tissue. Also, regeneration of subepidermal muscles occurred rather faster than NS2 and NS4 groups. Inflammatory cells were infiltrated in the hypodermis with various intensities without considerable difference between the treated groups.

In the NS2 group, muscular regeneration and scale formation was slow and weak in comparison with the NS4 and NS6 groups. The scale pockets with no embedded scales within them were formed in this group (Fig. 2).

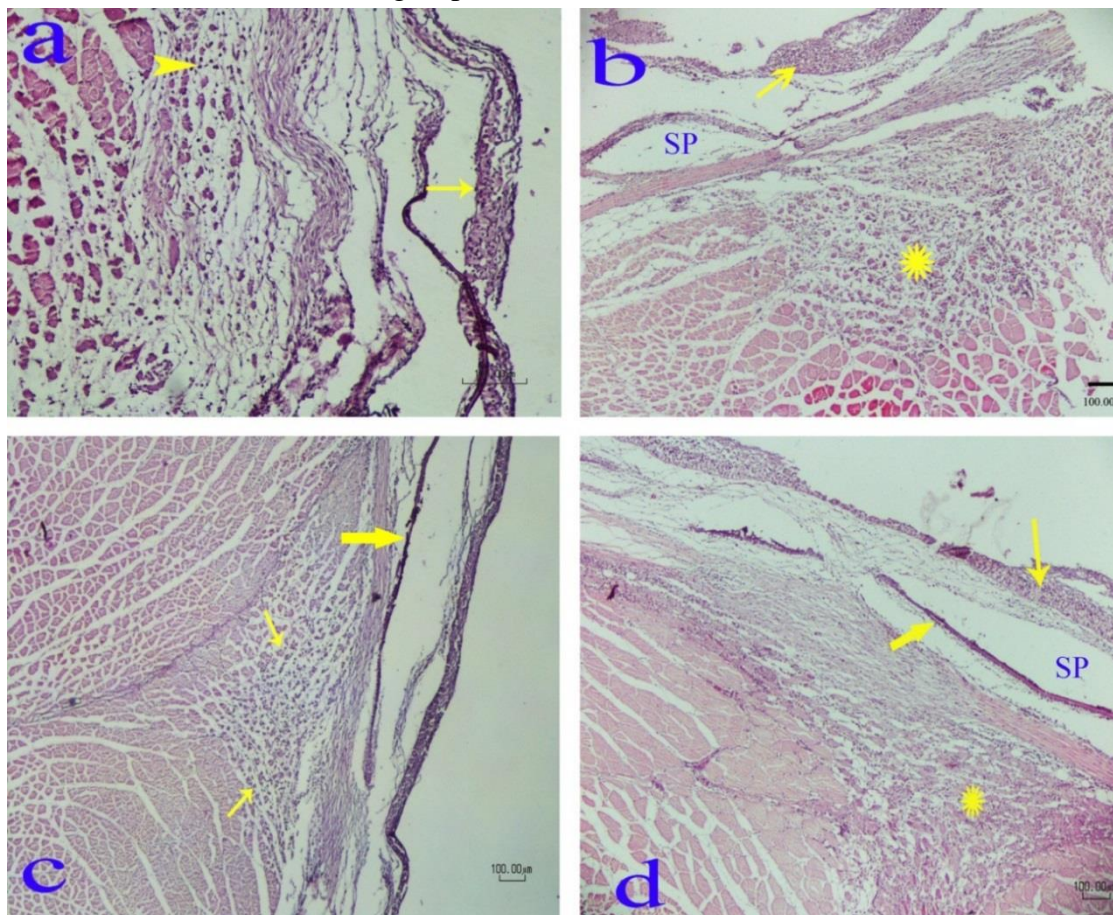


Figure 2: Effect of NS essential oil supplemented diet on wound healing at 7th-day post wounding. a) Control group: the new epidermis is slightly hyperplastic and irregular (arrow) and inflammatory cells were infiltrated between decomposed muscle tissues (arrowhead). b) NS2 group. The irregular new epidermis, scale pocket (SP) and mild muscular regeneration (asterisk) are observed. c) NS4 group. The photograph shows the formation of regular neo-epidermis as well as scale (thick arrow), and the regeneration of sub-epidermal muscles, especially in the margins wound (arrows), has been increased. d) NS6 group. Re-epithelialization (thin arrow) with technically sloughing a part of it, the presence of scale pockets with scales (thick arrow) within them and more muscular regeneration (asterisk) rather than other groups are obvious.

Discussion

In order to evaluate the efficacy of wound healing therapy, many wound healing models have been developed. At

the pre-clinical level, animal models for various skin depths and co-morbidity were available (Kumar *et al.*, 2013). In terms of wound depth, a wound can be

either a superficial, partial-thickness, or full-thickness wound (Percival, 2002). Full-thickness skin wounds involve all skin layers and may extend to muscles and bones, such as incision wounds or gunshot wounds. Based on the criteria, this study attempted to evaluate a trend of full thickness wound healing process of goldfish, which involves the epidermis, dermis, hypodermis, and sub-dermal muscular tissue.

Various animal models, such as bovine, sheep, dog, porcine, zebrafish, etc., have been selected to evaluate the therapeutic effect of any treatment for wound repair in different conditions (Grada *et al.*, 2018). However, there are a few studies reporting effect of environmental factors and dietary components on the cutaneous wound healings of fish (Sveen *et al.*, 2018). In some species, such as rainbow trout, the regeneration process is slow and muscle wounds does not regenerate within 100 days Furthermore it remains fibrotic at least one-year post-wounding (Schmidt *et al.*, 2016) that is in contrary with the observed healing rapidity in goldfish during the present study.

Because of osmotic deteriorations after wound incident, the rapid healing trend would be vital in aquatic organisms. When skin damage occurs, a rapid wound healing process is essential to prevent entry of pathogens to subcutaneous tissues and secondary infections (Zydlewski *et al.*, 2010; Olsen *et al.*, 2012). Wound healing speed varies between different species of fish, among which, the fastest trend belongs to a member of the cyprinids

(Sharifpour, 2004). This study is based on a 7 days monitoring period of healing and accordingly, the macro and microscopic observations revealed its efficacy for *C. auratus*.

Therapeutic outcomes of wound healing intervention can be evaluated from the combination of macroscopic and histological observations, biochemical and biomechanical measurements to estimate the effect of a therapy on the progression of wound repair (Dorsett-Martin and Wysocki, 2008). The macroscopic evaluation, also known as gross morphology observation, provides an early indication of wound healing efficiency. Parameters that can be obtained from this observation include time to complete healing, wound contraction, and wound closure (de Moura Estevão *et al.*, 2019). It is important to note that wound closure does not guarantee quality of skin regeneration (Takeo *et al.*, 2015). As such, a microscopic evaluation of skin regeneration is paramount.

Gross investigations of goldfish wounds displayed more appropriate wound closure in our treated fish and reduction of wound size and hyperemia were notable. The control wounds were more hyperemic with edematous margins, which imply the inflammatory responses of post wounding cascade (Sveen *et al.*, 2019). Between the treatment groups, fish fed with 6% concentration of NS oil had more efficacy and the incision lines had almost faded.

The wound healing process involves four consecutives, yet overlapping,

phases comprising haemostasis, inflammatory, proliferative, and remodeling phases (Singh *et al.*, 2017). Any disruption or imbalance in each phase can result in wound healing attenuation or over induction. This phenomenon implies that the classification and quantitative calibration of wound healing phases and processes through scorings and statistics are less applicable and reliable than qualitative followings and observations. This fact has been the intellectual support of the authors of the current study to prioritize the qualitative assessments of wound healing process.

Wound healing in fish is a cascade comprised of re-epithelialization, inflammation, granulation tissue formation, and tissue remodeling, which are all activated initially through the occurrence of deep injuries (Guerra *et al.*, 2008; Richardson *et al.*, 2013; Schmidt, 2013, 2016; Sveen *et al.*, 2019). Despite the similarities, the initial re-epithelialization stage is replaced by the initial blood clot formation in mammals (Sveen *et al.*, 2020).

NS has had a special status as a medicinal herb since ancient time (Ijaz *et al.*, 2017). NS and its main content thymoquinone are well known to have a wide range of therapeutic effects mainly attributed to their anti-inflammatory, antioxidant, anticancer, antibacterial, nephroprotective, and neuroprotective properties that have been revealed in various in vivo studies (Cascella *et al.*, 2018).

Thymoquinone contributes in several biological activities of the black seeds

(Ali and Blunden, 2003). It would appear that the beneficial effects of thymoquinone might be related to its cytoprotective and antioxidant actions, and effect on some inflammatory mediators, which mainly contributed to wound healing process (Darakhshan *et al.*, 2015; Cascella *et al.*, 2017; 2018).

In the present study, dietary administration of NS facilitated migration and proliferation of malpighian cells or regeneration of the new epidermis. Also, the number of mucous cells in the NS groups was more than the control group. In aquatic organisms, the mucous layer and epidermis have important role in barrier function during steady conditions and skin repair (Wainwright and Lauder, 2017). In fish, rapid superficial wound repair and scale regeneration is essential for restoration the integument integrity and osmotic regulation (Zydlewski *et al.*, 2010; Olsen *et al.*, 2012). Accordingly in our study, muscles and scales begun to regenerate in the first week after wounding and the process was more complete in the treatment groups that is mainly due to the induction of angiogenesis, increased fibroblast proliferation, and subsequent collagen synthesis (Shahani *et al.*, 2013). Seo *et al.* (2017) revealed that regeneration of muscle tissues is accelerated by other substances such as silver nanoparticles in both direct skin application and immersion treatments. Arginine is one of the important amino acid and does exist in Black seed (Yimer *et al.*, 2019). It has been shown to cooperate in cutaneous wound healing

by enhancing skin mucosal function, regeneration and biosynthesis of the extracellular matrix (Chen *et al.*, 2020). Thus, dietary supplementation of black seed essential oil has potentially beneficial on mucosal barrier functions, homeostasis and consequently the initial re-epithelialization step in fish. The current study emphasizes that even oral usage of black seed essential oil provides acceptable speed of healing process and performance and is less expensive and easier to use for users in comparison with the local superficial treatments.

The authors showed that dietary supplementation with 6% concentration of NSessential oil accelerates the skin wound healing process. The oral effectiveness of this product on skin wound healing confirms the variety of paths and mechanisms through which skin regenerates, but more studies are required to clarify its mechanisms and effective compounds. These results can open new possibilities in environmentally supportable innovations that lead to the replacement of antibiotics with natural sources and less risk of antibiotic resistance. To the best of our knowledge, this is the first dietary form of black seed administration for wound healing of goldfish.

Acknowledgement

The current research was asserted by the Research Committee of Shahid Bahonar University of Kerman, Iran, which hereby is appreciated.

References

- Abd El-Hack, M. E., Mohamed, E., Abdelnour, S.A., Khafaga, A.F., Taha, A.E. and Abdel-Latif, H.M., 2021.** *Nigella sativa* Seeds and Its Derivatives in Fish Feed. In *Black cumin (Nigella sativa) seeds: Chemistry, Technology, Functionality, and Applications*, 297-315. Springer, Cham. http://doi:10.1007/978-3-030-48798-0_19.
- Ali, B.H. and Blunden, G., 2003.** Pharmacological and toxicological properties of *Nigella sativa*. *Phytotherapy Research: An International Journal devoted to Pharmacological and Toxicological Evaluation of Natural Product Derivatives*, 17(4), 299-305. <http://DOI:10.1002/ptr.1309>
- Awad, E. and Awaad, A., 2017.** Role of medicinal plants on growth performance and immune status in fish. *Fish & Shellfish Immunology*, 7, 40-54. <http://doi:10.1016/j.fsi.2017.05.034>.
- Brown, C., Wolfenden, D. and Sneddon, L., 2018.** Goldfish (*Carassius auratus*). *Companion Animal Care and Welfare: The UFAW Companion Animal Handbook*, 467-478. <http://doi:10.1002/9781119333708.ch23>.
- Cascella, M., Palma, G., Barbieri, A., Bimonte, S., Amruthraj, N.J., Muzio, M.R., Del Vecchio, V., Rea, D., Falco, M., Luciano, A. and Arra, C., 2017.** Role of *Nigella sativa* and its constituent thymoquinone on chemotherapy-induced nephrotoxicity: evidences from experimental animal studies. *Nutrients*, 9(6), p.625.
- Cascella, M., Bimonte, S., Barbieri,**

- A., Del Vecchio, V., Muzio, M.R., Vitale, A., Benincasa, G., Ferriello, A.B., Azzariti, A., Arra, C. and Cuomo, A., 2018.** Dissecting the Potential Roles of *Nigella sativa* and Its Constituent Thymoquinone on the Prevention and on the Progression of Alzheimer's Disease. *Frontiers in Aging Neuroscience*, 10, 6 P. <http://doi:10.3389/fnagi.2018.00016>.
- Chakraborty, S.B. and Hancz, C., 2011.** Application of phytochemicals as immunostimulant, antipathogenic and antistress agents in finfish culture. *Reviews in Aquaculture*, 3(3), 103-119. <http://doi:10.1111/j.1753-5131.2011.01048.x>.
- Chen, Z., Ceballos-Francisco, D., Guardiola, F.A. and Esteban, M.Á., 2020.** Influence of skin wounds on the intestinal inflammatory response and barrier function: Protective role of dietary *Shewanella putrefaciens* SpPdp11 administration to gilthead seabream (*Sparus aurata* L.). *Fish & Shellfish Immunology*, 99, 414-423. <http://doi:10.1016/j.fsi.2020.02.022>.
- Citarasu, T., 2010.** Herbal biomedicines: a new opportunity for aquaculture industry. *Aquaculture International*, 18(3), 403-414. <http://doi:10.1007/s10499-009-9253-7>.
- Coutant, T., Vergneau-Grosset, C. and Lair, S., 2019.** Effect of a Misoprostol/Phenytoin Gel on Experimentally Induced Wounds in Brook Trout—A Preliminary Study. *Journal of Aquatic Animal Health*, 31(2), 214-221. <http://doi:10.1002/aah.10071>.
- Darakhshan, S., Pour, A.B., Colagar, A.H. and Sisakhtnezhad, S., 2015.** Thymoquinone and its therapeutic potentials. *Pharmacological Research*, 95, 138-158. <http://doi:10.1016/j.phrs.2015.03.011>.
- de Moura Estevão, L.R., Cassini-Vieira, P., Leite, A.G.B., de Carvalho Bulhões, A.A.V., da Silva Barcelos, L. and Evêncio-Neto, J., 2019.** Morphological evaluation of wound healing events in the excisional wound healing model in rats. *Bio-protocol*, 9(13), e3285. <http://doi:10.21769/BioProtoc.3285>.
- Dorsett-Martin, W.A. and Wysocki, A.B., 2008.** Rat models of skin wound healing. In *Sourcebook of Models for Biomedical Research* pp. 631-638. Humana Press.
- Dorucu, M., Ispir, U., Colak, S., Altinterim, B. and Celayir, Y., 2009.** The effect of black cumin seeds, *Nigella sativa*, on the immune response of rainbow trout, *Oncorhynchus mykiss*. *Mediterranean Aquaculture Journal*, 2(1), 27-33. <http://doi:10.21608/maj.2009.2667>.
- Grada, A., Mervis, J. and Falanga, V., 2018.** Research techniques made simple: animal models of wound healing. *Journal of Investigative Dermatology*, 138(10), 2095-2105. <http://doi:10.1016/j.jid.2018.08.005>.
- Guerra, R.R., Santos, N.P., Cecarelli, P., Silva, J.R.M.C.D. and Hernandez-Blazquez, F.J., 2008.** Healing of skin wounds in the African catfish *Clarias gariepinus*. *Journal of Fish Biology*, 73(3), 572-583. <http://doi:10.1111/j.1095-8649.2008.01950.x>.
- Ijaz, H., Tulain, U.R., Qureshi, J., Danish, Z., Musayab, S., Akhtar,**

- M.F., Saleem, A., Khan, K.A.U.R., Zaman, M., Waheed, I. and Khan, I., 2017.** *Nigella sativa* (Prophetic Medicine): A Review. *Pakistan Journal of Pharmaceutical Sciences*, 30(1), 229-234.
- Jinendiran, S., Nathan, A.A., Ramesh, D., Vaseeharan, B. and Sivakumar, N., 2019.** Modulation of innate immunity, expression of cytokine genes and disease resistance against *Aeromonas hydrophila* infection in goldfish (*Carassius auratus*) by dietary supplementation with *Exiguobacterium acetylicum* S01. *Fish & Shellfish Immunology*, 84, 458-469. <http://doi:10.1016/j.fsi.2018.10.026>
- Kumar, V., Khan, A. A. and Nagarajan, K. 2013.** Animal models for the evaluation of wound healing activity', *Int. Bull. Drug Res. Citeseer*, 3(5), 93–107.
- Olsen, R.E., Oppedal, F., Tenningen, M. and Vold, A., 2012.** Physiological response and mortality caused by scale loss in Atlantic herring. *Fisheries Research*, 129, 21-27. <http://doi:10.1016/j.fishres.2012.06.007>.
- Ozpolat, E. and Duman, M., 2016.** Effect of black cumin oil (*Nigella sativa* L.) on fresh fish (*Barbus grypus*) fillets during storage at 2±1 C. *Food Science and Technology*, 37,148-152. <https://doi.org/10.1590/1678-457X.09516>
- Percival, N.J., 2002.** Classification of wounds and their management. *Surgery (Oxford)*, 20(5), 114-117. <https://doi.org/10.1383/surg.20.5.114.14626>.
- Reyes, A.T., 2019.** Two-tailed fancy goldfish challenged with *Bacteroides* spp. isolated from shubunkin goldfish. *Journal of Drug Delivery and Therapeutics*, 9(3), 360-365. <http://doi:10.22270/jddt.v9i3.2681>.
- Richardson, R., Slanchev, K., Kraus, C., Knyphausen, P., Eming, S. and Hammerschmidt, M., 2013.** Adult zebrafish as a model system for cutaneous wound-healing research. *Journal of Investigative Dermatology*, 133(6), 1655-1665. <http://doi:10.1038/jid.2013.16>.
- Schmidt, J.G., 2013.** Wound healing in rainbow trout (*Oncorhynchus mykiss*) and common carp (*Cyprinus carpio*): with a focus on gene expression and wound imaging. PhD Thesis. Technical University of Denmark. (DTU), 194.
- Schmidt, J.G., Andersen, E.W., Ersbøll, B.K. and Nielsen, M.E., 2016.** Muscle wound healing in rainbow trout (*Oncorhynchus mykiss*). *Fish & Shellfish Immunology*, 48, 273-284. <http://doi:10.1016/j.fsi.2015.12.010>.
- Seo, S.B., Dananjaya, S.H.S., Nikapitiya, C., Park, B.K., Gooneratne, R., Kim, T.Y., Lee, J., Kim, C.H. and De Zoysa, M., 2017.** Silver nanoparticles enhance wound healing in zebrafish (*Danio rerio*). *Fish & Shellfish Immunology*, 68, 536-545. <http://doi:10.1016/j.fsi.2017.07.057>.
- Shahani, M.Y., Memon, S., Shahani, S.B., Bano, U. and Arain, S.N., 2013.** Effect of *Nigella sativa* extract oil on granulation tissue in cutaneous wound: an experimental study in a rabbit model. In *Medical Forum Monthly* 24(2), 72-77. em Inglês |

- IMEMR ID: emr-127296.
- Sharifpour, I., 2004.** Experimental study on histology of circumstance of wound healing process in common carp (*Cyprinus carpio*). *Iranian Scientific Fisheries Journal*. 13(2), 91-116. (in Persian)
- Singh, S., Young, A. and Mc Naught, C.E., 2017.** The physiology of wound healing. *Surgery (Oxford)*, 35(9), 473-477. [http://doi: 10.1016/j.mpsur.2017.06.004](http://doi:10.1016/j.mpsur.2017.06.004).
- Sladky, K.K., Swanson, C.R., Stoskopf, M.K., Loomis, M.R. and Lewbart, G.A., 2001.** Comparative efficacy of tricaine methanesulfonate and clove oil for use as anesthetics in red pacu (*Piaractus brachypomus*). *American Journal of Veterinary Research*, 62(3), 337-342. <https://doi.org/10.2460/ajvr.2001.62.337>
- Sveen, L.R., Timmerhaus, G., Krasnov, A., Takle, H., Stefansson, S.O., Handeland, S.O. and Ytteborg, E., 2018.** High fish density delays wound healing in Atlantic salmon (*Salmo salar*). *Scientific Reports*, 8(1), 1-13. [http://doi: 10.1038/s41598-018-35002-5](http://doi:10.1038/s41598-018-35002-5).
- Sveen, L.R., Timmerhaus, G., Krasnov, A., Takle, H., Handeland, S. and Ytteborg, E., 2019.** Wound healing in post-smolt Atlantic salmon (*Salmo salar* L.). *Scientific Reports*, 9(1), 1-16. [http:// doi: 10.1038/s41598-019-39080-x](http://doi:10.1038/s41598-019-39080-x).
- Sveen, L., Karlsen, C. and Ytteborg, E., 2020.** Mechanical induced wounds in fish—a review on models and healing mechanisms. *Reviews in Aquaculture*, 12(4), 2446-2465. [http://doi: 10.1111/raq.12443](http://doi:10.1111/raq.12443).
- Takeo, M., Lee, W. and Ito, M., 2015.** Wound healing and skin regeneration. *Cold Spring Harbor Perspectives in Medicine*, 5(1), p.a023267. [http://doi: 10.1007/978-3-319-74144-4_10](http://doi:10.1007/978-3-319-74144-4_10).
- Wainwright, D.K. and Lauder, G.V., 2017.** Mucus matters: the slippery and complex surfaces of fish. *Functional Surfaces in Biology III*, 223-246. Springer, Cham. [http://doi: 10.1007/978-3-319-74144-4_10](http://doi:10.1007/978-3-319-74144-4_10)
- Yimer, I. M., Tuem, K.B., Karim, A., Ur-Rehman, N. and Anwar, F. 2019.** ‘*Nigella sativa* L.(Black Cumin): A Promising Natural Remedy for Wide Range of Illnesses’, *Evidence-Based Complementary and Alternative Medicine*. Hindawi, 1–16. [http://doi: 10.1155/2019/1528635](http://doi:10.1155/2019/1528635).
- Zydlewski, J., Zydlewski, G. and Danner, G.R., 2010.** Descaling injury impairs the osmoregulatory ability of Atlantic salmon smolts entering seawater. *Transactions of the American Fisheries Society*, 139(1), 129-136. [http://doi: 10.1577/t09-054.1](http://doi:10.1577/t09-054.1).