

## The pretreatment potential effects of omy-miR-731 Antagomir in brain tissue of rainbow trout *Oncorhynchus mykiss* infected with viral hemorrhagic septicemia virus

Zamannejad N.<sup>1\*</sup>; Bigdeli M.R.<sup>1</sup>; Motallebi A.A.<sup>2</sup>; Kohram H.<sup>3</sup>;  
Haghighi Khiabani ASL A.<sup>4</sup>

Received: October 2018

Accepted: December 2018

### Abstract

Among the viral diseases in trout farming, viral hemorrhagic septicemia (VHS) could be mentioned as the most devastating worldwide viral infection. In the present investigation, the influence of the omy-miR-731 Antagomir pretreatment on VHS in rainbow trout was examined. Trout (20±1) g were examined in four main groups subdivided into three subgroups, including a negative control without any injection, a vehicle that received saline, a positive control that was infected by VHSV, and an experimental group that received omy-miR-731 Antagomir by injection, then they were challenged by VHSV. The survival rate, average weight gain, histopathology, Immunohistochemistry and Blood-brain barrier impermeability were assessed in each group. The survival rate and average weight gain in the positive control group was significantly decreased in comparison with other groups. Remarkable histopathological changes and virus detection by immunohistochemistry test were observed in the positive control, whereas no sign of the virus was observed in the vehicle and the negative control groups. The histologic changes in the experimental group were significantly less than the positive control group. Also, the Blood-brain barrier impermeability was significantly decreased in the other groups compared to the positive control group. Although more studies are needed to verify the exact mechanisms of pretreatment potential effects of omy-miR-731 Antagomir, the present results proved that pretreatment potential of omy-miR-731 Antagomir can protect the brain tissue against signs of VHS and preferably would be a new approach against VHSV infection in rainbow trout.

**Keywords:** Viral hemorrhagic septicemia, omy-miR-731 Antagomir, Blood-brain barrier, Flurescent isothiocyanate, Neurohistopathology, Immunohistochemistry.

1-Department of Animal Sciences and Biotechnology, Faculty of life Sciences and Biotechnology, Shahid Beheshti University, Tehran, Iran.

2-Department of Food Hygiene, Research and Science Unit, Islamic Azad University, Tehran, Iran.

3-Department of Animal Science, University College of Agriculture and Natural Resources, University of Tehran, Karaj, Iran.

4- Department of Pathology, Faculty of Specialized Veterinary Sciences, Islamic Azad University, Tehran, Iran.

\*Corresponding author's Email: [zamannejadnooshin@gmail.com](mailto:zamannejadnooshin@gmail.com)

## Introduction

Viral hemorrhagic septicemia virus (VHSV) is known as a prominent infectious disease in various kinds of freshwater and marine fish such as rainbow trout, a freshwater fish that is farmed worldwide (Ito *et al.*, 2012). It can cause high mortality in trout aquaculture and has been recorded by the World Organization for Animal Health (Munro *et al.*, 2015). Outbreaks of VHS have taken place in many of the rainbow trout farms in Iran in 2013 which resulted in 25% decrease in production of cold water industry (Sharifnia and Kazemi, 2008). So, many approaches have been designed to manage the expansion and distribution of the virus. The VHSV is an enveloped, bullet-shaped particle with single-stranded RNA belonging to the family Rhabdoviridae and genus *Novirhabdovirus*. This virus has single-stranded negative-sense RNA genome, containing six open reading frames (Haghighi Khiabani Asl, 2011). They express the following proteins known as: nucleoprotein (N), polymerase-associated phosphoprotein (P), non-virion protein (NV), glycoprotein (G), matrix protein (M), and the large RNA-dependent RNA polymerase (L) protein (Haghighi Khiabani Asl, 2011).

The signs of VHS disease are described as: Skin darkening, lethargy, anemia, exophthalmia and vast hemorrhages that are mostly occurred in the gills, eyes, skin, and the internal section of fins bases (Sharifnia and Kazemi, 2008). Besides, internal hemorrhage in various parts such as viscera, peri-ocular tissues, and skeletal

muscle, as well as liver congestion and hematopoietic degeneration can also be detected (Bela-Ong, 2014). Due to the observation of the signs of infection in the brain tissue of the infected trout, this research was done on the pretreatment potential effects of omy-miR-731 Antagomir in brain tissue. As various brain diseases are associated with brain vascular system, changes in brain vessel function could be mentioned as an indicator of different diseases, so in order to study the regulation of ion balance, nutrient transport facilitation and a potential barrier against harmful molecules in the central nervous system, the Blood-brain barrier impermeability as a target in traumatic brain injury was investigated (Kishimoto *et al.*, 2012).

Central nervous system and peripheral circulation system are associated with BBB. It was believed that nothing could penetrate the BBB except highly lipophilic molecules through the specific pathway. Therefore, the BBB was considered as an impenetrable, static function (Kishimoto *et al.*, 2012). The major issue in BBB investigation in in vivo studies is the analysis of brain extraction of injected molecules which cannot intact and cross BBB. Internal molecules assessment is normally limited by the BBB in the parenchyma of the brain. Since protection of the BBB is critical in some neurological conditions, a sensitive, objective method for BBB evaluation is needed (Huppert *et al.*, 2010). Using immunofluorescent is one of the most usual techniques used to estimate

changes in the BBB permeability. One of the most important markers in BBB is fluorescein isothiocyanate (FITC) - dextrans. They are polysaccharides containing different lengths of glucose molecules (Desai *et al.*, 2007). Their molecular weights are between 4 to 70 kDa that can be used to discover ion, solute and protein penetration in the BBB (Hoffmann *et al.*, 2011). At present, in vivo permeability of BBB is evaluated with FITC by comparison with the spectrophotometer (Wunder *et al.*, 2012).

BBB is essentially specialized capillary composition on the brain endothelial cells that form tight junctions via claudins, zona occludens and occlude between each other and contains highly specific transport systems. Dysfunction of the BBB occurs in many pathological conditions, such as brain injuries (McDannold *et al.*, 2008), CNS infections (Huang *et al.*, 2007), neurological diseases (Huppert *et al.*, 2010). However, under normal conditions, BBB is not permeable to neurotoxic structure and is changed in conditions that allow neurotoxins to enter the brain (Lochhead *et al.*, 2017).

The BBB dysfunction results in a decrease of perfusion and beta-amyloid accumulation in the brain parenchymal, which leads to the neurodegeneration and inflammation diseases (Sweeney *et al.*, 2018). There are some contributing factors such as peripheral immune disruption, immune system problems, which are related to age, may result in neuro-inflammation after damaged BBB (Higashida *et al.*, 2011). BBB

capillary vessels consist of a monolayer of endothelial cells which contain numerous mitochondria, and low pinocytotic activity to make tight junction (Nahirney *et al.*, 2016; Chen *et al.*, 2017). Endothelial cells in the brain, pericytes and astrocytes work together as a “neurovascular unit,” which is necessary for supporting and maintaining the BBB structure. The astrocytes, allows nutrient transportation between parenchymal and endothelial cells. Astrocytes delivers growth factors such as, glial cell line-derived neurotrophic factor (GDNF), fibroblast growth factor- $\beta$  (FGF- $\beta$ ), transforming growth factor- $\beta$  (TGF- $\beta$ ), and interleukin-6 (IL-6) which promote the expression of endothelial cell signaling proteins, such as tyrosine kinase receptors, and transport proteins such as P-glycoprotein and GLUT-1 (Johnson *et al.*, 2018). Due to research on miRNA's inhibitory effects on viral replication, the miR-731 was used for the possible suppression of the growth of the virus.

Micro-ribonucleic acids (microRNAs or miRNAs) as a noncoding RNAs are a class of short nucleotide chain (roughly 22 nt in length), that can control the expression of post-transcriptional genes by inhibiting protein synthesis or negatively regulating the transcript levels (Lyck and Enzmann, 2017). They play crucial roles in biological processes including, metabolism, development, host-pathogen interactions and immune responses (D’Juan and McManus, 2017). Changes of the expression of miRNAs are occurred through different

pathological conditions, which reveal the essential function of miRNAs in normal physiological condition (Bela-Ong, 2014). The strong effects of two types of miR-731 and miR-462 are identified in the fish liver. It seems that although different miRNA is conserved in vertebrates, these two miRNAs are restricted in teleost fish and involved in responses to the virus (Bela-Ong, 2014). Zhang and colleagues in 2016 have demonstrated that overexpression of interferon regulating factor 7 and p53 will stop both stimulatory and inhibitory effect of pol-miR-731 in biological process and viral replication. Also, the effects of AntamiR- 731 in Rhabdovirus-induced micro ribonucleic acids in rainbow trout *Oncorhynchus mykiss* Walbaum as a teleost miRNA were observed (Bela-Ong, 2014).

In this context, the aim of this study was to determine the pretreatment potential effects of omy-miR-731 Antagomir in brain tissue, in terms of the survival rate, mean weight, BBB impermeability, histopathology and immunohistochemistry to the harmful effects of the VHSV in the brain of rainbow trout. The sensitive and specific techniques for the detection of VHSV, such as Real-time PCR were necessary for approving the omy-miR-731 Antagomir pretreatment (OIE, 2006), for which another article was written by the authors. These data would be a new approach against VHSV infection in rainbow trout.

## Materials and methods

### Ethics statement

In approving the study protocol, fish research was conducted with the permission of the Animal Support Committee of the Iranian Veterinary Organization. Fish were sacrificed by using an overdose of Tricaine methanesulfonate prior to dissection (Munro *et al.*, 2015).

### VHS Virus

VHSV high virulence, Strain DK-3592B (Skall *et al.*, 2004), isolated from a rainbow trout, were intraperitoneally injected in the experimental and positive control group with nearly  $10^4$  TCID<sub>50</sub> ml<sup>-1</sup> (Zhang *et al.*, 2016). In order to conduct this test, the fiberglass tanks were put in a bio-security situation (Isolation challenge room in Khojir Research Station) in accordance with the protocol of the Iranian Veterinary Organization. To verify VHSV infection in animals, the Q-PCR method was performed.

### Preparation of omy-miR-731 Antagomir

The omy-miR-731 Antagomir was designed and synthesized by the Gene pharma company (Shanghai, China) (Bela-Ong, 2014; Hu *et al.*, 2017). Mature sequences of the miR-731 cluster were obtained from the miRBase Release (www.mirbase.org) (Accession number: M10004776) (Kozomara and Griffiths, 2011). Fish sequences were adapted from *Oryzias latipes*, *Danio rerio*. Higher vertebrate sequences were taken from *Monodelphis domestica*, *Salmo salar*, *Astatotilapia burtoni*, *Metriaclicha zebra*, *Neolamprologus brichardi*, *Oreochromis niloticus*, *Pundamilia*

*nyererei*, *Gadus morhua*, Target Scan Fish and Cichlid fish (<http://www.ebi.ac.uk/Tools/msa/clustalo/>) (Goujon *et al.*, 2010). Identification of miRNA sequences was performed at the Research and Development Branch of Razi Vaccine and Serum Research Institute.

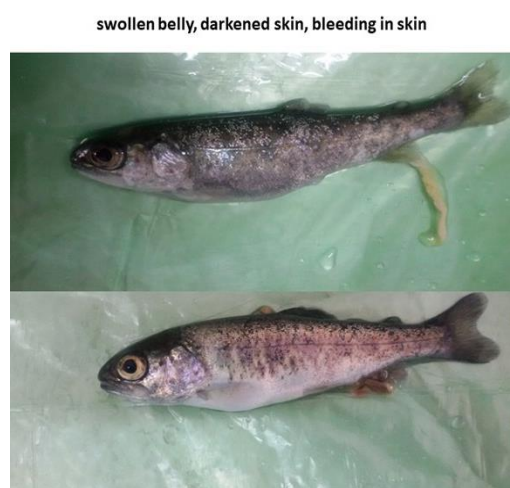#### *Experimental design*

This experiment was carried out with 240 rainbow trout juveniles, (weighing  $20 \pm 1$  g), which was prepared from Roodehen town (Jajrood trout farm). They had VHS free certificate approved by the Iranian Veterinary Organization. Fish were transferred to the Khojir National Park Research Station and were kept in a tank at  $14.9 \pm 0.5$  °C (experimental temperature). They were adapted in the challenge room for 5 days prior to the trial. Pathogen-free state of the fish was confirmed again by examination of bacterial and viral hemorrhagic septicemia virus by the National Reference Laboratories, Applied Science and Diagnosis of the Iranian Veterinary Organization. Each tank contained 270 L of water, changing continuously by a flow-through system. Fifty percent of all tank waters were replaced daily with fresh water. The fish were hand fed three times daily with pellets supplied by Cheeneh food Company, for 45 days after the start of the experiment. Then they were randomly divided into four groups in twelve fiberglass tanks (each group with three replicates and 20 fish in each tank). The first group served as the negative control group, the second group served as the vehicle group with

saline injection, the third group served as a positive control group, which were challenged by VHSV, and the last group were injected omy-miR-731 Antagomir at the first day of the beginning of the experiment (Bela-Ong, 2014; Hu *et al.*, 2017), then, after 48 hours they were challenged with VHSV isolate DK-3592B ( $10^4$  TCID<sub>50</sub> ml<sup>-1</sup>).

Disease signs were developed nearly after 5 days. The external sign of disease such as swollen belly, darkened skin, swollen eyes and also bleeding in the skin and eyes were observed in moribund trout (Fig. 1) (Bela-Ong, 2014). The sampling was performed at days 4, 8 and 12 after the viral injections (Zhang *et al.*, 2016). Then sample collection was performed for histopathology, immunohistochemistry, BBB impermeability, VHSV expression level, NMDA NR1 expression level by Real-time PCR, and eye affection syndrome investigation by carbonic anhydrase. In this article, we discussed only about histopathology, immunohistochemistry, some growth factors, and BBB impermeability. Dissection occurred with lethal anesthesia in an overdose of 3-aminobenzoic acid ethyl ester methanesulfonate (Sigma-Aldrich, St. Louis, MO, USA, 0.1 g mL<sup>-1</sup>, Poole, UK) and brain tissue were collected for further investigation. The remaining fish were kept until the 45th day in order to determine the survival rate and weight percentage as they were anesthetized using  $3.5 \pm 0.5$  °C ice water. After anesthesia, these fish were immediately recovered by immersion in a tank containing 8°C warm water

(Matthews and Varga, 2012). The study was terminated by lethal anesthesia at day 45. During the test, oxygen ( $\text{mg L}^{-1}$ ), pH, and temperature ( $^{\circ}\text{C}$ ) levels were 7.5 to 9,  $7.9 \pm 0.1$ ,  $14.9 \pm 0.5$ , respectively. For the expression of circadian rhythms, the trout were kept in holding tanks filled with filtered, DE chlorinated water on a 12:12 light and dark cycle. The spontaneous death of fish without euthanasia was observed after viral challenge and monitoring points of experiments (Zhang *et al.*, 2016).



**Figure 1:** Moribund *Oncorhynchus mykiss* showing external sign of disease including, swollen belly, darkened skin, swollen eyeballs and bleeding in the skin and eyes in the positive control group.

### Sampling methods

The brain of all groups was removed aseptically by quick dissection, followed by several washes in ice-cold saline water in order to remove possible blood or debris from brains (Kinkel *et al.*, 2010). The brain of experimental group were fixed in phosphate buffer formalin solution (10% buffer formalin) (pH: 7.4) for histopathology and immunohistochemistry investigation

and embedded in paraffin according to the previous described procedures (Sharifnia and Kazemi, 2008). Rapid progression of the disease results in animal death during the viral challenge was confirmed by the Shahid Beheshti University's Animal Care. Real-time PCR test was administrated to verify VHSV infection in suffered trout.

### Neurohistopathology

The histopathological procedures were used to evaluate the effect of miRNA and VHSV on brain tissue (Hong *et al.*, 2005). Ten days post infection (Haghighi Khiabani Asl, 2011), brain samples were preserved for neurohistopathological observation. Cases selected, met the following criteria: the trout were euthanized by an overdose of Tricaine methanesulfonate prior to dissections (Munro *et al.*, 2015). Five samples from each treatment group were chosen (Sharifnia and Kazemi, 2008). 10% formalin solution was used for fixation of the brain samples and after 24 hours, brains were dehydrated through a graded series of methanol, cleared with toluene, and embedded in paraffin (Garver *et al.*, 2005). Samples were cut into 5  $\mu\text{m}$  sections and were stained with hematoxylin-eosin, and then treated with mounting media. In order to avoid cross-contamination during the collection of tissue, using different fixative containers, cleaning of equipment between samples, and new solvents for dehydration (Evensen and Olesen, 1997) were done. Information obtained from the brain samples of 4 groups, histopathologic data analysis

showed the presence or absence the signs of VHS in groups containing the location of the lesion, distribution, and kind of lesions. All observations routinely were made by Hematoxylin and eosin staining sections. An average of 5 sections was available per case.

#### *Immunohistochemistry*

Immunohistochemistry techniques were used for virus detection in paraffin-embedded brain tissue (Garver *et al.*, 2005). This method was based on the modified method (Al-Hussiney *et al.*, 2016). After deparaffinization, the brain sections were incubated with 5% bovine serum albumin solution (BSA) in Tris-buffered saline (TBS, pH 7.4) for 20 minutes to avoid nonspecific binding (Depiereux *et al.*, 2014). Blotting off the slides was done by the monoclonal antibody (Animal Research Kit, Dako, the primary antibody) at a dilution ratio of 1: 500 and then, it was incubated for 30 minutes. The biotinylated (ab) 2 rabbit- anti-mouse IgG HRP as a secondary antibody diluted 1:300 (Glostrup, Denmark) was incubated for 30 minutes. After TBS washing, avidin-biotin alkaline phosphatase was added (1: 300 dilutions, Dakopatts) and incubated at room temperature for 45 min. After washing naphtol AS-MX- phosphate (0.2 g l<sup>-1</sup>, Sigma, USA) with inhibitor, they were added (1mM levamisole) to 0.1 M TBS and let them rest for 20 minutes. Samples were incubated as followed: Non-immune serum for control and vehicle and both non-immune and immune serum for experimental group (Adel *et al.*, 2015).

The primary antibody with positive reaction was incubated for 30 minutes at room temperature (Depiereux *et al.*, 2014). Immunohistochemistry analysis results showed presence or absence of the signs of VHS (grey matter) in groups containing the location of lesion and distribution. All observations were made by immunohistochemistry sections.

#### *Blood-brain barrier*

BBB impermeability was examined after 5 days' post challenge by fluorescent isothiocyanate (Kishimoto *et al.*, 2012). After 1, 4, 8 and 12 hours intra-peritoneal injection of isothiocyanate the brains were collected and kept in saline (Hoffmann *et al.*, 2011; Kishimoto *et al.*, 2012). In this way, five samples of each treatment were intraperitoneally injected with fluorescent isothiocyanate 5 days' post infection. FITC in a 500  $\mu\text{mol g}^{-1}$  concentration was mixed with phosphate buffer solution for injection. The measurements of FITC, dextran 150 (FD150S, 150 kDa, Sigma-Aldrich, St Louis, USA) was done 1, 4, 8 and 12 hours after FITC injection. Trouts were euthanized by Tricaine methane sulfonate prior to injection. Each injected trout, perfused at 1, 4, 8 and 12 hours after injection by making a fissure on the heart to exit all blood by heart pumping. Dissection occurred with an overdose of Tricaine methanesulfonate. During transportation, each brain was kept in a saline container at 4 °C. All samples were tested and prepared at a humidity of 34 – 35% at 22 °C (Hoffmann *et al.*,

2011). The trout brain placed in screw cap tubes (Cat19-650) with 500 µl of saline (pH=7.6). The trout brain of each treatment was homogenized in the Bead Rupture Elite (Cat,19-040E) fitted with a 2 ml tube carriage (Cat,19-010-310) at 5m s<sup>-1</sup> for 17 seconds then centrifuged at 11000 g for 3 minutes. Then 1µl of the supernatant was used to determine the isothiocyanate concentration at absorbance 540 nm on the Spectrophotometer (Nano Drop 1000 Spectrophotometer, Thermo Fisher Scientific; (de Albuquerque Oliveira *et al.*, 2016).

#### Statistical analyses

Statistical analyses were achieved by using analysis of variance (ANOVA). The accessed data were processed with SPSS 20 (IBM Corp., New York, NY, USA) and analyzed by Dunn's Multiple Comparison post hoc test to check for statistical significance between groups. Normally, a  $p < 0.05$  was considered as statistically significant (Chaubey, 1993).

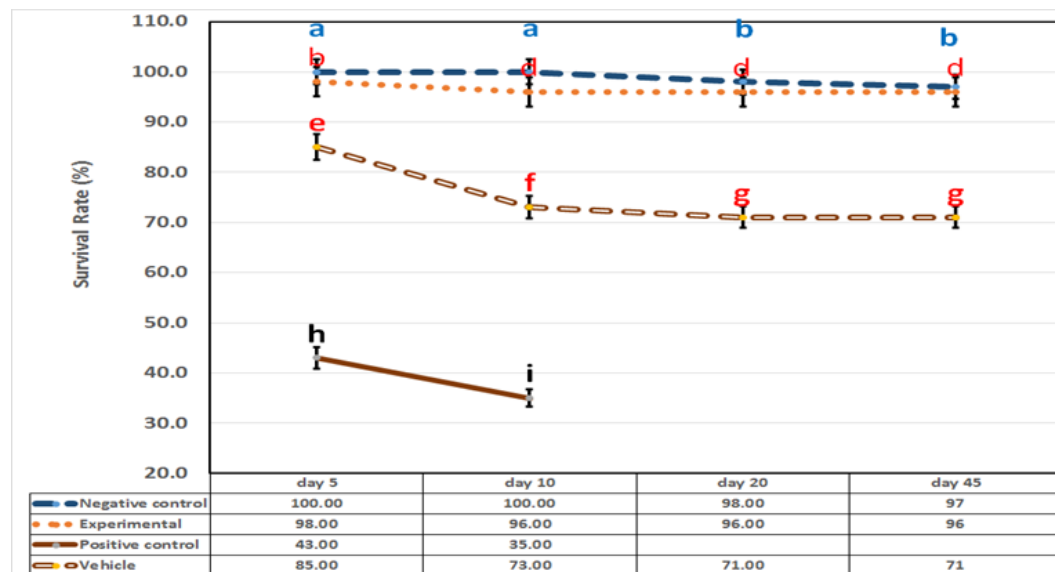
#### Results

Two teleost fish miRNA's are available on GenBank (NCBI) for Zebra fish

*Danio rerio* and Japanese rice fish *Oryzias latipes*. Analysis between the trout and teleost fish genomes showed the most similarity between Zebra fish and rainbow trout miRNA present in teleost fish genomes analyzed (<http://www.ensembl.org/index.html>).

The survival rate of each group was (97, 96, 0, and 71 %) for negative control, vehicle, positive control and experimental groups respectively after 45 days (Fig. 2). Mortality was observed after 5 days for positive control and experimental groups respectively. The experimental group was significantly protected after 45 days compared to the positive control group ( $p < 0.05$ ) and results represented 100% cumulative mortality in the positive control group and 29% in the experimental group. No mortality was detected in the negative control and vehicle group, and no significant difference has been detected in the survival rate of the negative control group and vehicle group in. There was a significant difference between experimental group compared to the negative control and vehicle groups ( $p < 0.05$ ).

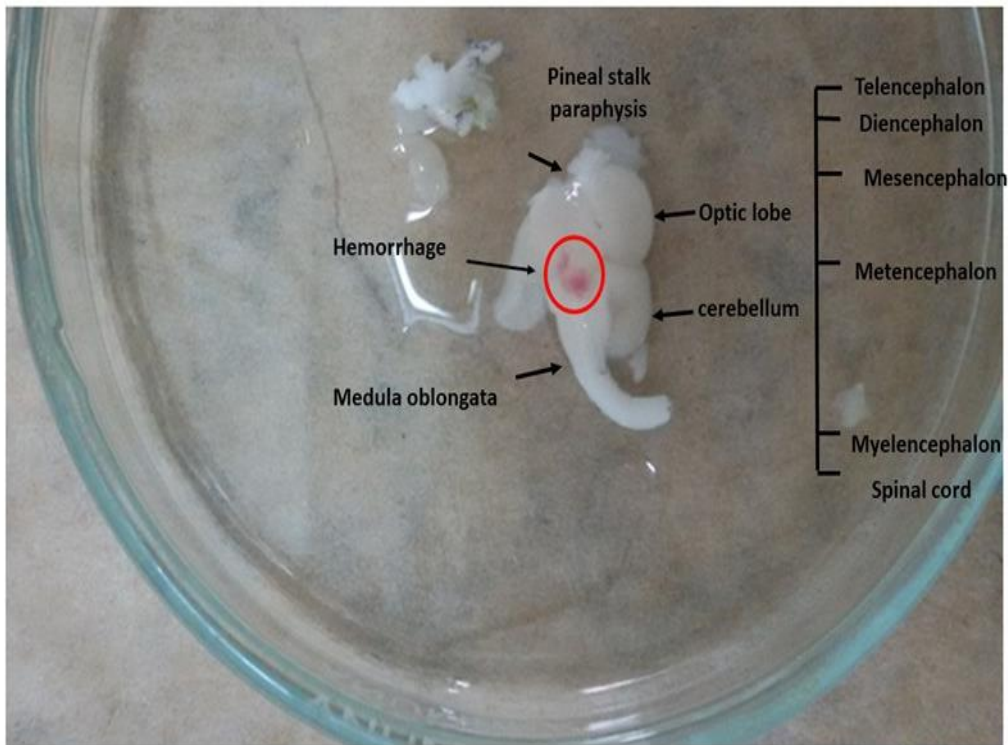




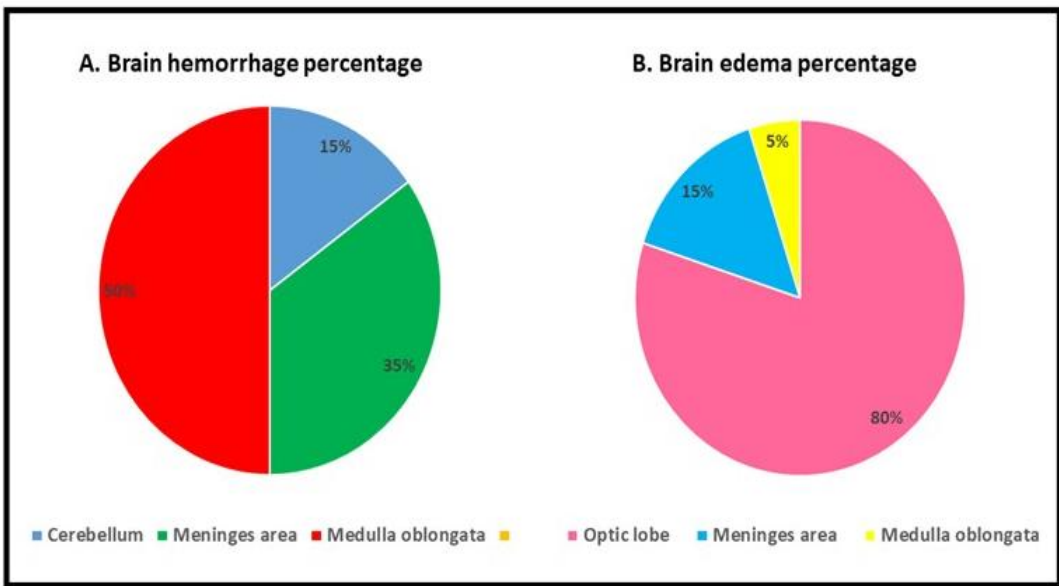
**Figure 2:** *Oncorhynchus mykiss*. The survival rate for the negative control, vehicle, positive control and experimental groups of rainbow trout. There was no significant difference in survival rate between the negative control and vehicle groups after 45 days ( $p>0.05$ ). Significant differences were detected between the negative control group and vehicle group compared to the experimental group during the days 10-45 ( $p<0.05$ ). All of the animals in the positive control group died 10 days after the commencement of the experiment because of the severe VHS infection.

Dissection of the infected brain tissue (positive control group) showed the typical signs as hemorrhage. Red spot placed between Optic lobe and Cerebellum near medulla oblongata showing the site of hemorrhage in the positive control group (Fig. 3). Neurohistopathological assessment of four groups consisted of the negative control, vehicle, positive control, and experimental groups were performed. An average of 5 sections was available per case. The VHS symptoms on positive control group are as followed: severe edema and hemorrhage in cerebral cortex, Vacuolar changes with empty spaces 2 (80%), nuclear debris with infiltration 8 (46.6%), bleeding hematopoietic tissue 8 (53%), necrotic cell mild in the middle of cerebellum 4

(26.6%), hyperplasia 2 (13.3%), neural necrosis 3 (20%), micro gliosis mild 6 (40%), meningitis hemorrhage 7 (46.6%) (Table 1). Of the cases studied, 80% cases positive controls had edema and hemorrhage in the cerebral cortex. Histopathology analysis of the negative control and vehicle groups showed no tissue injury. In the experimental group, low edema was observed 6 (40%). Cerebral hemorrhage and edema analysis in the positive control group (A and B) are shown in (Fig. 4). Brain Hemorrhage was observed in Cerebellum (15%), meninges area (35%) and Medulla oblongata (50%). Brain edema also was observed in the Optic lobe (80%), Meninges area (15%) and Medulla oblongata (5%).



**Figure 3:** Dissection of infected brain tissue of *Oncorhynchus mykiss* from the positive control group with the typical signs of hemorrhage by VHSV. The red circle is placed between Optic lobe and Cerebellum near medulla oblongata and shows the site of hemorrhage in this brain.



**Figure 4:** Cerebral hemorrhage and edema analysis of *Oncorhynchus mykiss* in the positive control group (A and B). Brain hemorrhages were observed in the cerebellum (15%), meninges area (35%) and medulla oblongata (50%). Brain edema was also observed in the optic lobe (80%), meninges area (15%), and medulla oblongata (5%).

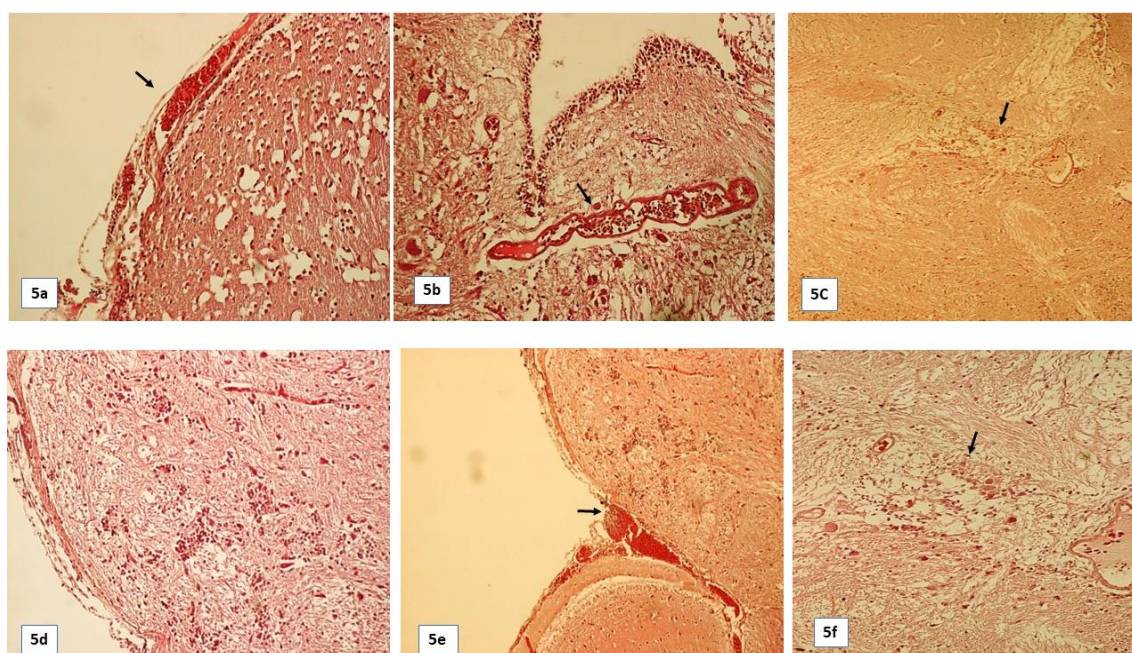
**Table 1: Summary of the histopathology score of the negative control, vehicle, positive control and experimental groups. Positive control and experimental were infected by VHSV. Histopathology scores were determined in brain tissue for sign of VHS disease. The negative control and vehicle groups showed no notable histopathology. An average of 5 sections was available per case. Brain of all 15 animals in the positive control group exhibited cerebral cortex edema and hemorrhage, nuclear debris with infiltration, bleeding, hematopoietic tissue, edema, necrotic cell in the middle of cerebellum, hyperplasia, neural necrosis, micro gliosis, nuclear debris with infiltration, meningitis hemorrhage at different severity levels. Cerebral cortex severe edema and hemorrhage 12 (80%), nuclear debris with infiltration 8 (46.6%), bleeding hematopoietic tissue 8 (53%), necrotic cell mild in the middle of cerebellum 4 (26.6%), hyperplasia 2 (13.3%), neural necrosis 3 (20%), micro gliosis mild 6 (40%), meningitis hemorrhage 7 (46.6%). Of the cases studied, 80% cases positive control was cerebral cortex edema and hemorrhage. Histopathology score of the negative control and vehicle groups showed no tissue injury. In treated group there is some edema was observed 6 (40%).**

Microscopic features Group	hemorrhage	cerebral cortex edema	nuclear debris with infiltration	bleeding hematopoietic tissue	necrotic cell	hyperplasia	neural necrosis	micro gliosis	meningitis hemorrhage
<b>negative control</b>	Absent	Absent	Absent	Absent	Absent	Absent	Absent	Absent	Absent
<b>vehicle</b>	Absent	Absent	Absent	Absent	Absent	Absent	Absent	Absent	Absent
<b>positive control</b>	12	12	8	8	4	2	3	6	7
	severe	severe	mild	moderate	mild	mild	mild	mild	moderate
<b>experimental</b>	Absent	6 mild	Absent	Absent	Absent	Absent	Absent	Absent	Absent

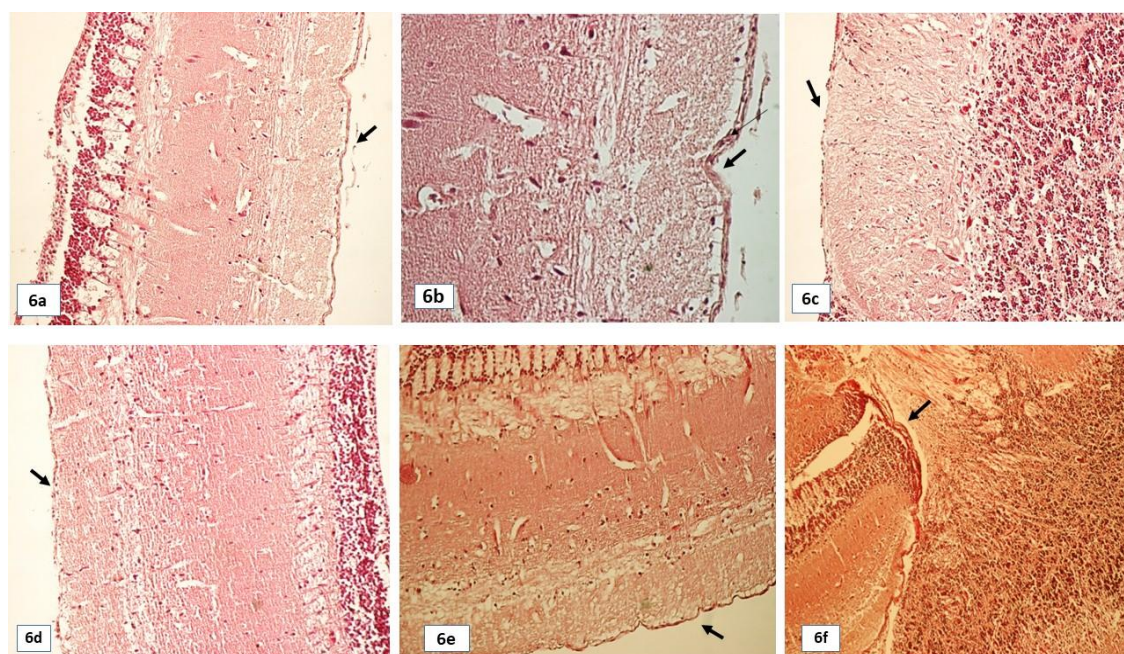
The result of the microscopic evaluation is shown in (Figs. 5a- 5f and 6a-6f) illustrate the distribution of specific signs of VHS in VHSV infected rainbow trout. Positive control group showed edema and hemorrhage in the cerebral cortex. In addition, other changes such as nuclear debris with infiltration, bleeding, meninges edema, necrotic cells in the middle of the cerebellum, dark stained degenerating neurons, hyperplasia, neural necrosis, micro gliosis and nuclear debris with

infiltration and meningitis hemorrhage are also represented (arrow) (Fig. 6a-6f) show the changes in the brain of the treated group. No remarkable histopathologic changes have been reported in the negative control group and vehicle group. As can be seen, no histopathologic changes are detected (Fig. 6d- 6f). Identification of morphological phases was evaluated upon the lesion in the cerebrum and meninges. Presence of erythrocytes represented hemorrhagic signs.





**Figure 5:** Photomicrograph of the brain of *Oncorhynchus mykiss*. The histopathology sections of the brain hematoxylin-eosin staining in trout juveniles' (20 g) show neural injury in the positive control group which indicates the localized hemorrhage in the cerebral cortex. Black arrows show histopathological changes in the brain. Starting from top left, 5a shows: cerebral cortex edema and hemorrhage, nuclear debris with infiltration, bleeding, and vacuolar changes with empty spaces; 5b, shows hematopoietic tissue (black arrow); 5c, illustrates edema, necrotic cell in the middle of the cerebellum, hyperplasia, neural necrosis, and dark stained degenerating neurons; 5d, microgliosis; 5e, microgliosis, edema, hematopoietic tissue, nuclear debris with infiltration, and hemorrhage due to meningitis hemorrhage; and 5f, microgliosis (x100).

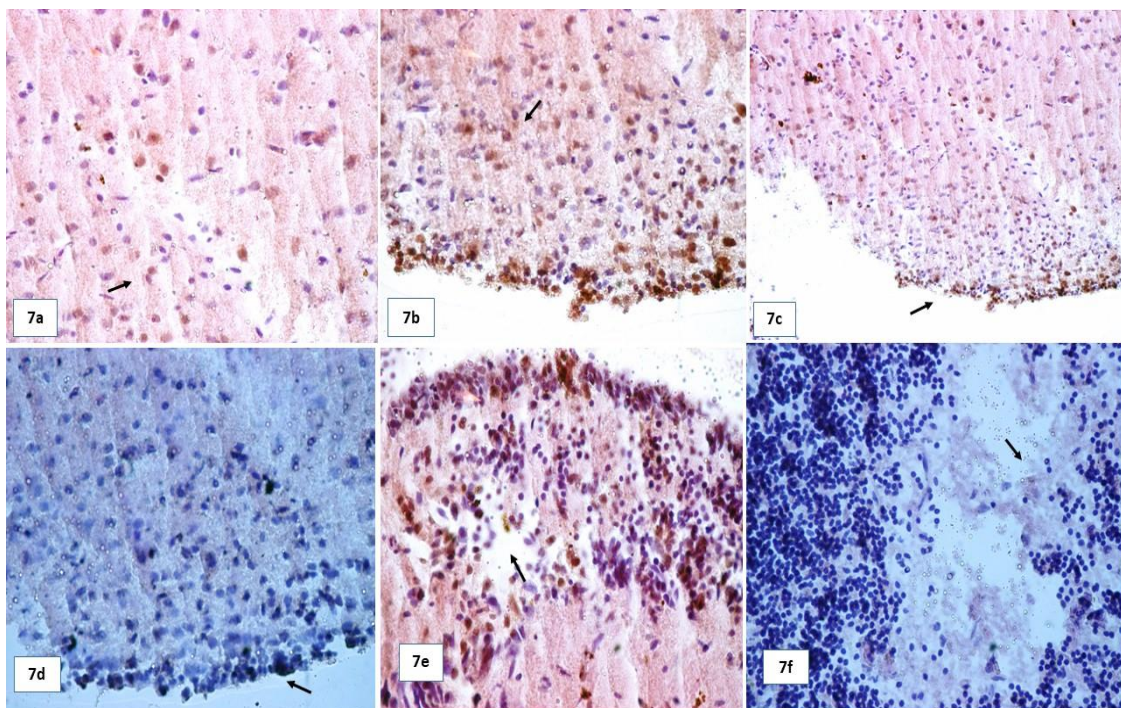


**Figure 6:** Photomicrograph of the brain of *Oncorhynchus mykiss*. The histopathology sections of brain hematoxylin-eosin staining in Juvenile trout (20 g) in the negative control, vehicle, and experimental groups show normal texture. Black arrows show histological regions, starting from top left: 6a, experimental normal brain hemisphere, edema (black arrow); 6b, normal cerebellum; 6c, cerebellum with normal meninges; 6d, negative control; and 6e – 6f, Vehicle group (x100).

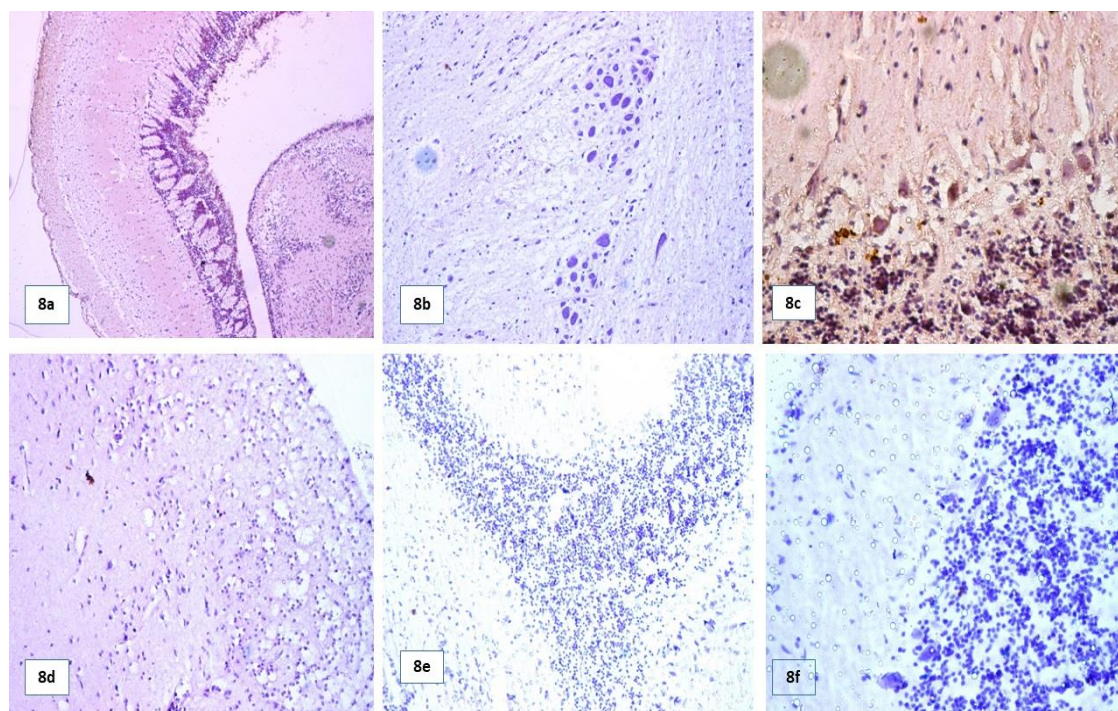


Immunohistochemically evaluation of the brain in four groups of the negative control, vehicle, positive control and experimental groups was done. The VHS symptoms on the positive control group were as the following: Staining illustrates 65% positive virus detection in cortex tissue. Intense staining of meninges cerebral layer revealed fragmentation of pigment melanin granules on tissue, meninges with virus (45%) and cerebellum was more intense staining, there was no virus detected on edema. The result of the microscopic evaluation is shown in (Figs. 7a- 7f and

8a- 8f). Fig. 7a to 7f illustrate the distribution of specific positive signs of VHS in the brain of the positive control group. The positive control group are shown virus infection in meninges and revealed the presence of virus in presence of monoclonal antibody in IHC analysis. Data are shown in (Fig. 7a- 7f). Fig. 8a– 8f revealed that in the brain of the negative control, vehicle and positive control group, no virus has been detected among the positive control group which was shown by immunohistochemistry method.



**Figure 7:** Immunohistochemistry staining of the positive control group of *Oncorhynchus mykiss* is represented in 7a-7f. There is a moderate amount of immunopositive staining in the meninges area, some of which is necrotic. Pre immune rabbit antiserum replaced rabbit anti-VHSV was inset. Black arrows show the following immunopositive staining in brain tissue (clockwise from top to left): 7a, cerebra cortical tissue positive stained virus detection (there is more intense staining in meninges); 7b, cerebral layer revealing fragmentation of pigment granules on tissue; 7c, cerebellum meninges with intense staining; 7d, melanin granules and meninges with virus; 7e, cerebellum with more intense staining; and 7f, no virus detected.



**Figure 8: Immunohistochemistry staining of the negative control, vehicle, and experimental groups are shown. There is no sign of immunopositive staining in the brain. Pre immune rabbit antiserum replaced rabbit anti-VHSV was inset. From top to left 8a-8d are from the experimental group. 8e, negative control, and 8f from the vehicle group.**

In order to investigate the Blood Brain barrier impermeability changes during VHSV infection and probability pretreatment by omy-miR-731 Antagomir, fluorescein Isothiocyanate was injected into four groups of fish. Bars in panels vehicle and experimental represent in the same order without significant differences with each other ( $p>0.05$ ). The results of the negative control represent a significant difference in comparison to the other groups ( $p<0.05$ ). The results of the control express a significant difference compared to the negative control,

vehicle and experimental groups ( $p<0.05$ ). The highest amount of FITC ( $\text{ng ml}^{-1}$ ) was detected in the brain of the positive control group with a significant difference ( $p<0.05$ ). The optical density was regulated at 540 nm (Fig. 9A). Average of FITC concentration was quantitated and normalized to the amount of this present in the brain tissue (Fig. 9B). Animals in the experimental group did not show any significant difference compared to the negative control and vehicle group ( $p>0.05$ ).



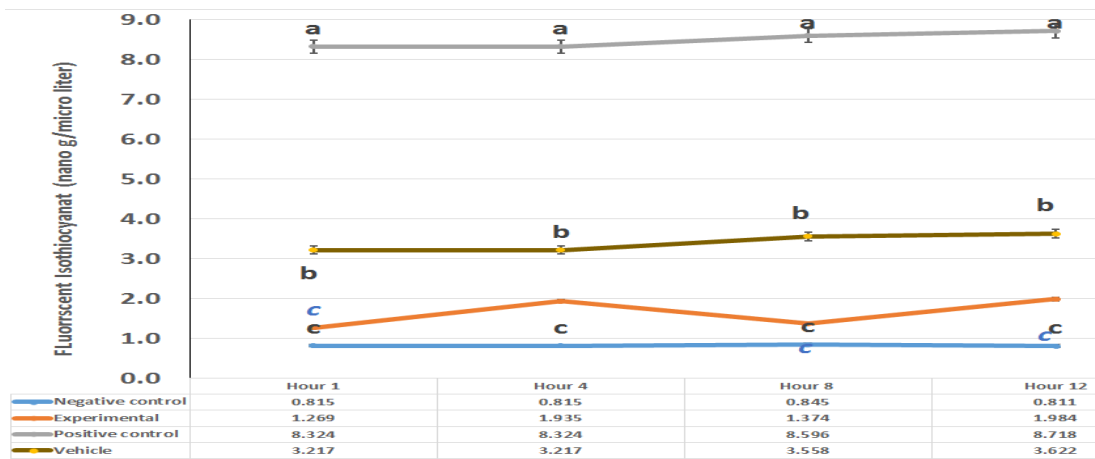


Figure 9: Isothiocyanate concentration [ $\text{ng ml}^{-1}$ ] generated by the BBB assessment for the negative control, vehicle, positive control and experimental groups. Before euthanasia, trout were injected with fluorescein Isothiocyanate in order to investigate the BBB impermeability. Vehicle and experimental groups are represented in the same order and did not show significant differences ( $p>0.05$ ). The Results of the negative control represent a significant difference compared to the other groups ( $p<0.05$ ). Results of the positive control were significantly different from the other groups while the positive control was significantly different from the negative control, vehicle and experimental groups. Error bars indicate the standard deviation for each group. Optical density was 520 nm.

The effect of miRNA injection and viral challenge in trout weighing are represented in (Fig. 10). Our results have demonstrated that there were no significant differences between the weight of trout in the negative control and Vehicle groups compared to the experimental group with total maximum weight gain of 50.24, 48.84 and 47.86 g respectively during 45 days. All fish in the positive control group died after 10 days of the beginning of the experiment with maximum 19.16 g which is the

significant difference between positive control group and other groups ( $p<0.05$ ). Statistical analyses also revealed that, there were no statistically significant differences between the experimental group (as pretreated group), vehicle (as physiology group) compared to the negative control (as control group) ( $p>0.05$ ) but statistically significant difference was identified between positive control group as a pathology group with other groups ( $p<0.05$ ).

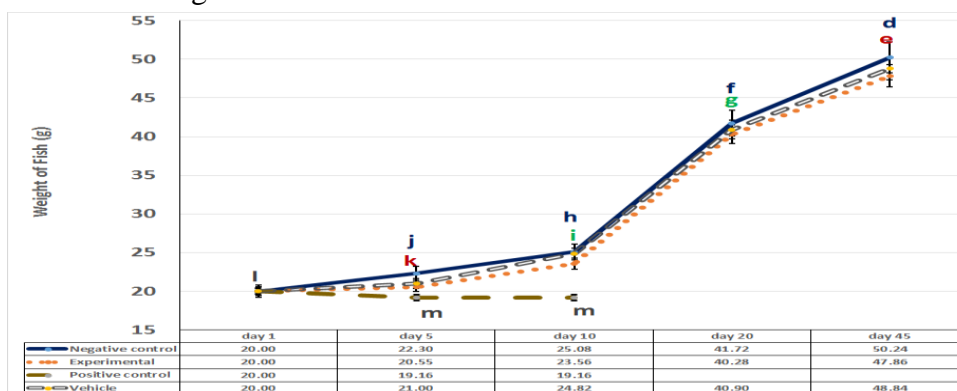


Figure 10: An average trout weight gains during the 45-day of the experiment. There is no significant difference between the average weight of the negative control, vehicle and experimental groups for the most days ( $p>0.05$ ), but there is the significant difference between the positive control compared to the other groups.

## Discussion

The experiment presented here focused on the relationship between omy-miR-731 Antagomir and VHS disease in the brain tissue by studying histopathology, immunohistochemistry, some growth factors and BBB impermeability changes in groups of study. To our knowledge, this is the first report showing that rainbow trout infected by VHSV Strain DK-3592B could be pretreated by omy-miR-731 Antagomir. The investigation setup was based on the previous investigation about miR-731 by Zhang *et al.* (2016) and Bela-Ong (2014).

Here, we indicated that in negative control and vehicle groups the survival rate was significantly protected after 45 days compared to the experimental and positive control group. Also, the experimental group showed a significant difference in protection against VHSV compared to the positive control. These findings are in agreement with the observations of Thoulouze *et al.* (2004) in terms of the cumulative mortality levels in virulence of Nv-vhsv carrying genes derived from the VHSV FR-07-71 strain. Another study has stated that combination of cytomegalovirus (CMV) promotor and the viral hemorrhagic septicemia virus (VHSV) genotype IVb glycoprotein (G) gene insert (designated pVHSivb-G) in DNA plasmid (pcDNA) could induce protection in rainbow trout (Elsayed *et al.*, 2006). They found that a lot of mortalities have been reported in North America because of VHSV, including freshwater and marine fish. Cumulative mortality of 10% in infected wild

Atlantic salmon was reported. By injection, the rate of 78% mortality has been reported (Elsayed *et al.*, 2006). Also experiment about anti-miR-731 and anti-miR,462 in Zebra fish showed that Anti-miRNA intraperitoneal injection by lethal virus challenge did not show a significant difference on the development of VHS and mortality profiles, reaching 90% in 14 days' post-challenge (Bela-Ong, 2014).

A better understanding of the miRNA pretreatment potential in the brain can be achieved by examining the histopathologic investigation. Histopathological aspects have been applied to predict the brain tissue status infected with the virus. Twenty samples in four groups at the present study were histopathologically investigated to have VHS virus infection. The VHSV replicates in brain cells in the positive control group. In the current study, cases of four groups presented with hematoxylin-eosin staining showed structural tissue similarity between the negative control, vehicle and experimental groups with normal brain tissue while the signs of severe edema and hemorrhage according to the most important sign of VHS disease (Bela-Ong, 2014) are observed on the positive control group. The microscopic properties of a cerebral hemorrhage are heterogeneous; however, some lesions with a systemic approach are detected that reflects various histologic features. This study showed that other confirmation of neuronal injury, including cerebral cortex severe edema and hemorrhage, vacuolar changes, nuclear debris with infiltration,



bleeding hematopoietic tissue, necrotic cell in the middle of the cerebellum, dark stained degenerating neurons, microgliosis, meningitis hemorrhage and in a minority of samples an underlying hyperplasia were observed under the microscopic examination of brain samples (Zorriehzahra *et al.*, 2010). Our results have demonstrated that neuro histopathological signs of VHS were decreased by miRNA pretreatment in the experimental group. One of the famous previous studies about VHS by Sharifnia and Kazemi (2008), reviewed histopathology methods in the Iranian rainbow trout farms to define histopathological signs of VHS disease. Also Kim and Faisal (2010) worked on histopathology of VHS disease and modelled the comparative susceptibility of representative Great Lakes fish species to the North American viral hemorrhagic septicemia experiment. Evaluating the signs of the pathogenesis of VHS disease after pretreatment with miRNA to gain more effective knowledge to facilitate and improve possibility of disease prevention is the critical goal of this study. In conclusion, VHSV can alter the brain tissue of juvenile rainbow trout as observed in this study and omy-miR-731 Antagomir pretreatment could prevent the sign of damage in brain tissue of the experimental group. Certainly, further investigations are necessary to evaluate the histopathology effects of miRNA on the trout brain both in the natural environment and in the laboratory.

The immunohistochemistry examinations showed the presence of

VHSV directly in the brain of the positive control group, especially there was more intense staining on meninges, also, cerebral layer revealed fragmentation of pigment melanin granules on tissue, there was no virus detected on edema. Also, there was no virus detection in the negative control, vehicle and experimental group in the IHC test. Results of this study revealed that virus's existence was decreased in groups which received miRNA before VHSV infection. The results of this study are similar to the previous study (Garver *et al.*, 2005). They have also evaluated the existence of VHS virus in rainbow trout by immunohistochemistry method, in addition, the research showed similarity for their ability of the monoclonal antibody to detect VHSV by immunohistochemistry method (Al-Hussinee *et al.*, 2016). In this experiment, there were no signs of the virus in brain tissue during the study. Their finding is in contrast to our experiment. Comparing the use of immunohistochemical method for identification of VHSV with virus cultivation was reported by Elsayed *et al.* (2006).

The miRNAs are non-coding RNAs with ~24 base-pair long which regulate gene expression by binding to a specific target in the cytoplasm of eukaryotic cells and mediating mRNA transcriptional blocking or cleavage. Two specific viral-induced microRNAs are restricted to teleost fish, one of them called miR-731 (Bela-Ong, 2014). There is a strong up regulation in rainbow trout after inoculation with the

viral hemorrhagic septicemia virus. These miRNAs were highly up regulated in the liver and spleen of infected rainbow trout (Bela-Ong, 2014). The gene cluster miR-731 was localized on chromosome 8 in ensemble release. Inhibitory Locked Nucleic Acid (LNA) antagomir (miR-731), was designed to determine the role of the miR-731 in the interaction between the disease and fish (Hu *et al.*, 2017). It seems that these substances have an antiviral role in the experimental group. Mammalian cells could inhibit virus infection throughout viral transcript suppression by their cellular miRNAs or anti miRNAs. Protection ability of the cellular miRNAs against viral infection has been expressed previously (Umbach and Cullen, 2009). The study has proven that miRNAs can inhibit viral replication by binding to a special site which is located inside the viral genome (Huang *et al.*, 2007).

Protective effect of omy-miR-731 Antagomir intra peritoneal injection in rainbow trout *O. mykiss* after infection with viral hemorrhagic septicemia virus was observed by FITC. Lyck and Enzmann (2017) have shown that FITC at discrete intervals could be administered to provide valuable information about BBB permeability. Also, Wunder *et al.* (2012) have shown in vivo permeability of BBB were evaluated with FITC by comparison with the spectrophotometer in the animal disease models (Wunder *et al.*, 2012).

Data revealed that BBB impermeability was changed significantly in the positive control compared with other

groups ( $p < 0.05$ ). The precise mechanism of the effect of omy-miR-731 Antagomir on BBB in viral pathologic conditions is remained unknown. So this research is rated as a high priority for the pathophysiologic process associated with VHSV infection and cerebral hemorrhage. Recently, using miRNA is going to apply more frequent in prevention of disease. According to our finding, BBB permeability was decreased significantly by miRNA injection pretreatment during VHSV infection. There were significant differences between the positive control compared to the other groups ( $p < 0.05$ ), but there were no significant differences in the negative control compared to the vehicle and experimental groups ( $p > 0.05$ ).

Also, this experiment is in accordance with another study, which has examined “High and Low Molecular Weight FITC–Dextran’s to evaluate the BBB Disruption” by Hoffman *et al.*, 2011. Briefly, they worked on the molecular weight FITC–Dextran’s in order to evaluate the BBB Disruption. To evaluate the alteration of BBB impermeability FITC–dextran’s can be useful in the animal study. It has shown hypoxia-inducible factor-1 $\alpha$ , aquaporin-4, and matrix metalloproteinase-9 have a critical role in BBB disruption (Higashida *et al.*, 2011). Measurement of the BBB disruption was done by FITC-dextran extravasation. Changes in BBB permeability is a dominant feature among neurophysiological diseases, so BBB dysfunction as a potential key can

improve diagnosis and prevent a variety of diseases. An infection may cause changes in BBB just as what happened in neurodegenerative diseases (Higashida *et al.*, 2011). Providing structural support and communication control between the parenchyma and endothelial cells is the base of membrane function. One of the important roles of the BBB is their ability to make tight junctions. Their endothelial cells contain lots of mitochondria to provide the energy which is necessary for high-resistance tight junctions (Lockwood *et al.*, 1991). Exposing the homogenate brains with Spectrophotometer showed significant reduction of the FITC after viral infection. Changes of BBB permeability in animals' study can be detected by FITC.

The present research showed that miRNA injection had no significant effects on the weight of trout weighing 47.86 g in the experimental group, 50.24 g and 48.84 g in the negative control and vehicle groups 45 days after the experiment was started ( $p>0.05$ ). However, 10 days after the beginning of the experiment the weight of the positive control group decreased, and all animals died because of the viral infection. This experiment is line with Kim and Faisal at 2010 that have assessed the comparative susceptibility of representative Great Lakes fish species to the North American viral hemorrhagic septicemia virus Sub lineage IVb. Their result has indicated a similar direction like our experiment about the VHS disease and weight gain (Kim and Faisal, 2010). Although extra

researches especially in relation to miRNA pretreatment and immune system in VHS are needed to uncovered the mechanisms of omy-miR-731 Antagomir pretreatment pathway, our present results proved that pretreatment potential of omy-miR-731 Antagomir could protect the brain tissue against signs of VHSV and preferably would be a new approach against VHSV infection in rainbow trout.

### Acknowledgement

Special thanks are extended to Dr. Ole Bendic Dale from Norwegian Veterinary Institute, Norway; for his assistance in Neuro histopathology. The authors are also grateful to Dr. Maryam Dadar, Dr. Morteza Taghizadeh and Dr. Kavooos Nazari for their advice, consultancy and help. Also, the authors would like to thank Shahid Beheshti University, Razi Vaccine and Serum Research Institute, Tehran Agricultural and Natural Resources Research Center and the Iranian Veterinary Organization for their help and support to conduct this research.

### References

- Adel, M., Pourgholam, R., Zorriehzahra, M.J. and Ghiasi, M., 2015. The effect of different levels of *Mentha piperita* on some of the hematological, biochemical and immune parameters of *Oncorhynchus mykiss*. *Iranian Scientific Fisheries Journal*, 24(1), 37-46.
- Al-Hussine, L.P., Pham, S., Russell, L., Tubbs, C., Taffala, N., Bols, N., Dixon, B. and HLumsden, J., 2016.

- Temporary protection of rainbow trout gills epithelial cells from infection with viral hemorrhagic septicemia virus IVb. *Journal of Fish Diseases*, 39, 1099-1112. DOI: 10.1111/jfd.12442
- Bela-Ong, D.B., 2014.** *Rhabdovirus-induced micro ribonucleic acids in rainbow trout (Oncorhynchus mykiss Walbaum)*. PhD Thesis, National Veterinary Institute, Technical University of Denmark, Denmark. Page 136.
- Chaubey, Y.P., 1993.** Resampling-based multiple testing: Examples and methods for *p*-value adjustment. *Technometrics*, 35(4), 450-451
- Chen, X., Liu, Z., Cao, B.B., Qiu, Y.H. and Peng, Y.P., 2017.** TGF- $\beta$ 1 neuroprotection via inhibition of microglial activation in a rat model of Parkinson's disease. *Journal of Neuro Immune Pharmacology*, 12, 433-446. DOI: 10.1007/s11481-017-9732-y
- D'juan, T.F. and Mcmanus, M.T., 2017.** MicroRNAs in ectodermal appendages. *Current Opinion in Genetics and Development*, 43, 61-66. DOI: 10.1016/j.gde.2016.12.006
- De Albuquerque Oliveira, A., Linhares, M.I., Chaves Filho, A.J., Mala, E., Rios, E.R.V., De Carvalho Lima, C.N., Venancio, E.T., De Souza, A.G., De Lima, K.A., De Sousa, F.C., Florenco, E. and Gaspar, D.M., 2016.** Antioxidant properties of antiepileptic drugs levetiracetam and clonazepam in mice brain after in vitro-induced oxidative stress. *African Journal of Pharmacy and Pharmacology*, 10, 278-288. DOI:10.5897/AJPP2015.4358
- Depiereux, S., Liagre, M., Danis, L., De Meulder, B., Depiereux, E., Segner, H. and Kestemont, P., 2014.** Intersex occurrence in rainbow trout (*Oncorhynchus mykiss*) male fry chronically exposed to ethynylestradiol. *PLoS One*, 9, e98531. DOI: 10.1371/.0098531
- Desai, B.S., Monahan, A.J., Carvey, P.M. and Hendey, B., 2007.** Blood-brain barrier pathology in Alzheimer's and Parkinson's disease: Implications for drug therapy. *Cell Transplantation*, 16, 285-299. PMID: 17503739
- Elsayed, E.M., Faisal, M., Thomas, G., Whelan, W., Batts, B. and Winton, J., 2006.** Isolation of viral hemorrhagic septicemia virus from muskellunge, *Esox masquinongy* (Mitchill), in Lake St Clair, Michigan, USA reveals a new sub lineage of the North American genotype. *Journal of Fish Diseases*, 29, 611-619. DOI: 10.1111/j.1365-2761
- Evensen, Ø. and Olesen, N.J., 1997.** Immunohistochemically detection of VHS virus in paraffin-embedded Specimens of rainbow trout (*Oncorhynchus mykiss*): the influence of primary antibody, fixative, and antigen unmasking on method sensitivity. *Veterinary Pathology*, 34, 253-261. DOI: 10.1177/030098589703400316
- Garver, K.A., Conway, C.M., Elliott, D.G. and Kurath, G., 2005.** Analysis of DNA-vaccinated fish reveals viral antigen in muscle,

- kidney and thymus, and transient histopathologic changes. *Marine Biotechnology*, 7, 540-553.
- Goujon, M.H., Mc William, V.F., Li, W., Squizzato, S. and Paern, J., 2010.** A new bioinformatics analysis tools framework at EMBL-EBI. *Nucleic Acids*, 38, W695-9.
- Haghighi Khiabani Asl, A., 2011.** Histopathology and other methods for detection of viral hemorrhagic septicemia (VHS) in some Iranian rainbow trout farms. *Recent Advances in Fish Farms*. InTech.
- Higashida, T., Kreipke, C.W., Rafols, J.A., Peng, C.A., Schafer, S., Ding, J.Y., Dornbos, III., Li, X. and Guthikonda, M., 2011.** The role of hypoxia-inducible factor-1 $\alpha$ , aquaporin-4, and matrix metalloproteinase-9 in Blood-brain barrier disruption and brain edema after traumatic brain injury. *Journal of Neurosurgery*, 114, 92-101. DOI: 10.3171/2010.6. JNS10207
- Hoffmann, A., Bredno, J., Wendland, M., Derugin, N., Ohara, P. and Wintermark, M., 2011.** High and low molecular weight fluorescein Isothiocyanate (FITC)-dextrans to assess Blood-brain barrier disruption: Technical considerations. *Translational Stroke Research*, 2, 106-111. DOI: 10.1007/s12975-010-0049-x
- Hong, S., Tjonahen, E., Morgan, E. L., Lu, Y., Serhan, C.N. and Rowley, A.F., 2005.** Rainbow trout (*Oncorhynchus mykiss*) brain cells biosynthesize novel docosahexaenoic acid-derived resolvins and protectins—mediator lipidomic analysis. *Prostaglandins and Other Lipid Mediators*, 78, 107-116. DOI: 10.1016/j
- Hu, Y.H., Zhang, B.C., Zhou, H.Z., Guan, X.L. and Sun, L., 2017.** *Edwardsiella tarda*-induced miRNAs in a teleost host: Global profile and role in bacterial infection as revealed by integrative miRNA-mRNA analysis. *Virulence*, 8, 1457-1464. DOI: 10.1080/21505594.2017.1356541
- Huang, J.F., Wang, E., Argyris, H., Chen, K., Liang, Z., Tian, H., Huang, W., Squires, K., Verlinghieri, G. and Zhang, H., 2007.** Cellular microRNAs contribute to HIV-1 latency in resting primary CD4+ T lymphocytes. *Nature Medicine*, 13, 1241. DOI: 10.1038/nm1639
- Huppert, J., Closhen, D., Croxford, A., White, A., Kulig, P., Pietrowski, E., Bechmann, I., Becher, B., Luhmann, H.J. and Waisman, A., 2010.** Cellular mechanisms of IL-17-induced Blood-brain barrier disruption. *The FASEB Journal*, 24, 1023-1034. DOI: 10.1096/fj.09-141978
- Ito, T., Kurita, J., Sano, M., Skall, H. F., Lorenzen, N., Einer-Jensen, K. and Olesen, N.J., 2012.** Typing of viral hemorrhagic septicemia virus by monoclonal antibodies. *Journal of General Virology*, 93, 2546-2557. DOI: 1099/vir.0.043091-0
- Johnson, A.C., Hammer, E.S., Sakkaki, S., Tremble, S.M., Holmes, G.L. and Cipolla, M.J., 2018.** Inhibition of Blood-brain

- barrier efflux transporters promote seizure in pregnant rats: Role of circulating factors. *Brain, Behavior, and Immunity*, 67, 13-23. DOI: 10.1016/j.bbi.2017.07.017
- Kim, R. and Faisal, M., 2010.** Comparative susceptibility of representative Great Lakes fish species to the North American viral hemorrhagic septicemia virus sublineage IVb. *Diseases of Aquatic Organisms*, 91, 23-34.
- Kinkel, M.D., Eames, S.C., Philipson, L.H. and Prince, V.E., 2010.** Intraperitoneal injection into adult zebrafish. *Journal of Visualized Experiments: JoVE*. DOI: 10.3791/2126.
- Kishimoto, N., Shimizu, K. and Sawamoto, K., 2012.** Neuronal regeneration in a zebrafish model of adult brain injury. *Disease Models and Mechanisms*, 5, 200-209. DOI: 10.1242/dmm.007336
- Kozomara, A. and Griffiths-Jones, S., 2011.** miRBase: integrating micro RNA annotation and deep-sequencing data. *Nucleic Acids Research*, 39(Database issue), D152-D157. DOI: 10.1093/nar/gkq 1027
- Lochhead, J.J., Ronaldson, R.T. and Davis, T.P., 2017.** Hypoxic stress and inflammatory pain disrupt Blood-brain barrier tight junctions: Implications for drug delivery to the central nervous system. *The AAPS Journal*, 19, 910-920. DOI: 10.1208%2Fs12248-017-0076-6
- Lockwood, A.H., Yap, E.W. and Wong, W.H., 1991.** Cerebral ammonia metabolism in patients with severe liver disease and minimal hepatic encephalopathy. *Journal of Cerebral Blood Flow and Metabolism*, 11, 337-341. DOI: 10.1038/jcbfm
- Lyck, R. and Enzmann, G., 2017.** The blood brain barrier and inflammation. Springer. pp. 45514-3. DOI: 10.1007/978-3-319
- Matthews, M. and Varga, Z.M., 2012.** Anesthesia and euthanasia in zebrafish. *ILAR Journal*, 53, 192-204.
- McDannold, N., Vykhodtseva, N. and Hynynen, K., 2008.** Blood-brain barrier disruption induced by focused ultrasound and circulating preformed microbubbles appears to be characterized by the mechanical index. *Ultrasound in Medicine and Biology*, 34, 834-840. DOI: 10.1016/j.ultrasmedbio
- Munro, E., McIntosh, R., Weir, S., Noguera, P., Sandilands, J., Matejusova, I., Mayes, A. and Smith, R., 2015.** A mortality event in wrasse species (Labridae) associated with the presence of viral hemorrhagic septicemia virus. *Journal of Fish Diseases*, 38, 335-341.
- Nahirney, P.C., Reeson, P. and Brown, C.E., 2016.** Ultrastructural analysis of blood-brain barrier breakdown in the peri-infarct zone in young adult and aged mice. *Journal of Cerebral Blood Flow and Metabolism*, 36, 413-425. DOI: 10.1177/0271678X15608396
- Sarma, J.D., Kenyon, L.C., Hingley, S.T. and Shindler, K.S., 2009.**

- Mechanisms of primary axonal damage in a viral model of multiple sclerosis. *Journal of Neuroscience*, 29, 10272-10280.
- Sharifnia, Z. and Kazemi, B., 2008.** Diagnosis of viral hemorrhagic septicemia (VHS) in Iranian rainbow trout aquaculture by pathology and molecular techniques. *Bulletin of European Association of Fish Pathology*, 28, 170.
- Skall, H.F. et al., 2004.** Experimental infection of rainbow trout *Oncorhynchus mykiss* with viral haemorrhagic septicaemia virus isolates from European marine and farmed fish. *Journal of Disease of Aquatic Organisms*, 58, 99-110.
- Sweeney, M.D., Sagare, A.P. and Zlokovic, B.V., 2018.** Blood-brain barrier breakdown in Alzheimer disease and other neurodegenerative disorders. *Nature Reviews Neurology*, 14(3), 133.
- The Office International des Epizooties (OIE), 2006.** Manual of diagnostic tests for aquatic animals. Fifth Edition, Notifiable Disease Chapter. pp. 141-158.
- Thoulouze, M. I., Bouguyon, E., Carpentier, C. and Bre´mont, M., 2004.** Essential role of the NV protein of Novirhabdovirus for pathogenicity in rainbow trout. *Journal of Virology*, 78, 4098-4107.
- Umbach, J.L. and Cullen, B.R., 2009.** The role of RNAi and microRNAs in animal virus replication and antiviral immunity. *Genes and Development*, 23, 1151-1164. DOI: 10.1101/gad.1793309
- Wunder, A., Schoknecht, K., Stanimirovic, D.B., Prager, O. and Chassidim, Y., 2012.** Imaging blood-brain barrier dysfunction in animal disease models. *Epilepsia*, 53, 14-21.
- Zhang, B.C., Zhou, Z.J. and Sun, L., 2016.** Pol-miR-731, a teleost miRNA upregulated by megalocytivirus, negatively regulates virus-induced type I interferon response, apoptosis, and cell cycle arrest. *Scientific Reports*, 6, 28354. DOI: 10.1038/srep28354
- Zorriehzahra, M.J., Hassan, M.D., Gholizadeh, M. and Saidi, A.A., 2010.** Study of some hematological and biochemical parameters of rainbow trout (*Oncorhynchus mykiss*) fry in western part of Mazandaran province, Iran. *Iranian Journal of Fisheries Sciences*, 9(1), 185-198.