

Toxic effects of diclofenac on gills, liver and kidney of *Cyprinus carpio* (Linnaeus, 1758)

**Mohebbi Derakhsh P.^{1,2}; Mashinchian Moradi A.^{1*}; Sharifpour I.^{2*};
Jamili Sh.²**

Received: April 2017

Accepted: July 2017

Abstract

Diclofenac, the anti-inflammatory drug, is found in natural water bodies all over the world. Toxicological researches of diclofenac report harmful effects on aquatic species even at low concentrations. The aim of present study was to determine whether diclofenac affected on the gills, liver and kidney of common carp (*Cyprinus carpio*). In order to evaluate toxic effects of diclofenac as NASIDs (non-steroidal anti-inflammatory drugs) in fish, common carp was exposed to diclofenac concentrations of 1.25 mg L⁻¹, 2.5 mg L⁻¹ and 5 mg L⁻¹. The effects of diclofenac on the fish were investigated by histopathological observations on a weekly basis over a 21 day experiment period. The histopathological examinations of diclofenac exposed fish revealed alteration of the kidney such as hyaline droplet, increasing of interstitial cells, shrinkage of glomeruli, and the presence of melanomacrophages and necrosis of epithelial cells of tubules. In the gills, the predominant findings consisted of epithelial hyperplasia, telangiectasia, clubbing, lamellar fusion and increasing of mucosal cells. Also observed histopathological alteration in liver, included, presence of melanomacrophages in hepatocytes, degeneration and vacuolation of hepatocytes and necrosis of hepatocytes. The most alteration was comparatively in the gills and liver. However the gills, livers and kidney sections of the two control groups exhibited normal structure. The results of this study showed that diclofenac could be harmful for *C. carpio*.

Keywords: Diclofenac, Toxic effect, Histopathology, Common carp (*Cyprinus carpio*)

1-Department of Natural Resources and Environment, Science and Research Branch, Islamic Azad University, Tehran, Iran

2-Iranian Fisheries Science Research Institute (IFSRI), Agricultural Research, Education and Extension Organization (AREEO), Tehran, Iran

*Corresponding author's Email: isharifpour@yahoo.com, Ali2m@yahoo.com

Introduction

Pharmaceutical pollutions have become a matter of attention as being toxic in aquatic environments, due to the fact that many of these compounds have been shown to reach considerably high concentrations within surface waters and STP (sewage treatment plant) effluents (Stumpf *et al.*, 1996; Heberer and Stan, 1998; Heberer, 2002; Sacher *et al.*, 2001; Ternes, 1998). Nevertheless, low-concentrations and long-term effects of pharmaceuticals in non-target organisms such as fishes have not been investigated carefully (Fent *et al.*, 2006).

The non-steroidal anti-inflammatory drugs (NSAIDs) are among the most commonly found drugs in the aquatic environment (Santos *et al.*, 2010). The new report of the Ministry of Health, treatment and medical education of Iran shows that huge amounts of diclofenac was consumed in Iran in 2015 (<http://www.fda.gov.ir>). There are some reports on the occurrence of pharmaceutical pollution in Iran, and few studies have been done to remove Diclofenac from drinking water (Eslami *et al.*, 2015; Salmani *et al.*, 2017). There was no research about the concentration of pharmaceutical pollution in the Caspian Sea, but it is likely that there are high concentrations of diclofenac in some places close to drug factories and sewage of coastal cities in the south of the Caspian Sea.

The effect of pharmaceuticals upon aquatic organisms are in most cases restricted to short term acute response such as lethality in algae, invertebrates, and fish (Webb, 2001).

Based on these facts 1) pharmaceuticals in general display highly specific effects

and are intended to be used on purpose in vertebrates partly over longer periods of time and 2) Serval studies have been done on the unwanted side effects of diclofenac on non-target animals during ecotoxicological studies (Schwaiger *et al.*, 2004).

Pharmaceuticals reach the aquatic environment continuously leading to chronic exposure of aquatic organisms. Histopathology was applied to detect diclofenac included organ lesions, and parallel to this, electron microscopic investigations were conducted to characterize the cellular and sub cellular reactions on the ultrastructural levels (Triebkorn *et al.*, 2004). In addition residuals of diclofenac in rainbow trout, Tench and Zebra fish were analyzed by histopathological methods (Hoeger *et al.*, 2005; Praskova *et al.*, 2014; Stancova *et al.*, 2014). All mentioned researches, have confirmed that vital organs of exposed fishes have been affected by diclofenac.

This research was carried out to investigate the conceivable effects of diclofenac as NSAIDs, on some vital organs of *Cyprinus carpio*. This is one of the most used drugs in Iran which enters aquatic environments via incomplete treatments of wastewaters in the south coast of the Caspian Sea.

Materials and methods

Fish preparation and adaptation

A 21 day experiment was carried out within July to September 2015 in Iran by using common carp (*C. carpio*) as the test organism. Fish were caught from Syjeval fish hatchery ponds located in Torkman Port at Golestan Province, in the north of Iran and transferred to the laboratory of

Islamic Azad University in Tehran. Two weeks before the experiment, fish with an average body weight of 30 ± 5 g; and average body length of 16.1 ± 1.02 cm were stocked in aquaria (with volume of 140 liters of water) and aeration was provided with an air pump for 24 h. for adaptation. After the adaptation period, fish of similar mean weight were separated and survival test was performed with three replications: 20 fish were used in each replication, at a density of 3.5 g L^{-1} . Aeration was provided at all times and a photo period of 12:12 (L:D) was used. Fish were fed at the rate of 1% body weight and 50% of water was exchanged daily (Guiloski *et al.*, 2015).

Treatment and replication design

Fish were categorized in 5 treatments each with 3 replications. According to 96 h $\text{LC}_{50} = 70.98 \text{ mg L}^{-1}$ of diclofenac in *C. carpio* (Islas-Flores *et al.*, 2013), Fish were exposed to nominal concentration of 1.25, 2.5 and 5 mg L^{-1} of diclofenac. To control for possible side effects of the solvent used, an additional group of fish was exposed to 0.12 dimethylsulfoxid (DMSO) (Saravan *et al.*, 2011). Control fish were maintained without any treatment in natural water. All treatments and control aquaria were regularly checked for chemical and physical parameters (temperature: 25°C ; dissolved oxygen: 5.2 mg L^{-1} ; pH: 7.1; conductivity: $633 \mu\text{S cm}^{-1}$; hardness: $266 \text{ mg CaCO}_3^{-1}$) (APHA, 1998).

The test substance, diclofenac (purity: 99.9%) was purchased from Sobhan Daroo Ind. in Iran. To obtain the final test concentration, diclofenac was diluted in DMSO to obtain a stock solution containing $100 \text{ g diclofenac L}^{-1}$.

At this stage, pharma volume that is necessary for the preparation of treatments was calculated by $C_1V_1 = C_2V_2$ from which the first stock solution was prepared and then used with regard to concentrations (Happ *et al.*, 2008).

Histopathological examinations

Random sampling was done from each treatment and replication on days 7, 14 and 21 after exposing fish to diclofenac. Three fish per group were anaesthetized in clove essence at a dose of 1:1000, and subsequently sacrificed and their liver, gills and kidneys were removed, fixed in buffered formalin (10%) and processed following routine (Praskova *et al.*, 2014). Microscopic sections were taken at $5 \mu\text{m}$ and stained with hematoxylin and eosin (H&E). After a qualitative histopathological assessment of tissue alteration, by observation under microscope (Nikon ECLIPSE90i microscope connected with the digital camera Nikon DS5U1), both the degree and severity of histopathological alterations were evaluated. Briefly, a ranking was used (Sharifpour *et al.*, 2014).

Results

Histopathological findings

Histopathological images by light microscopy are summarized in tables 1-3. The light microscopic examination of the gills, liver and kidney did not reveal any histopathological alterations neither in control fish nor in solvent (DMSO) control fish.

The main alterations of the gills occurred in exposed fish including telangiectasia, epithelial hyperplasia, increasing of mucosal cells, epithelial

lifting, lamellar fusion and clubbing. The predominant findings showed the degree and severity of gill damage increased significantly after exposure to 1.25 mg L⁻¹

and higher diclofenac concentrations compared with the control level.

Table 1: Histopathological finding of *Cyprinus carpio* gills exposed to various sublethal concentrations of diclofenac.

Histopathological finding	Day 7			Day 14			Day 21		
	1.25 mg L ⁻¹	2.5 mg L ⁻¹	5 mg L ⁻¹	1.25 mg L ⁻¹	2.5 mg L ⁻¹	5 mg L ⁻¹	1.25 mg L ⁻¹	2.5 mg L ⁻¹	5 mg L ⁻¹
Epithelial hyperplasia	+	+	++	+	++	++	+	+	+++
Telangiectasis	-	+		++	++	++	++	+++	+++
clubbing	+	+	+	+	++	++	++	++	++
Increasing of mucosal cells	-	+	+	+	+	++	+	++	+++
Lamellar fusion	-	+	++	-	++	++	+	++	+++
Epithelial lifting	-	+	+	-	+	+	-	+	+

+ = mild changes (10 percent changes in X40 objective microscopic view).

++=moderate changes (20 percent changes in X40 objective microscopic view).

+++=severe changes (more than 20 percent changes in X40 objective microscope view).

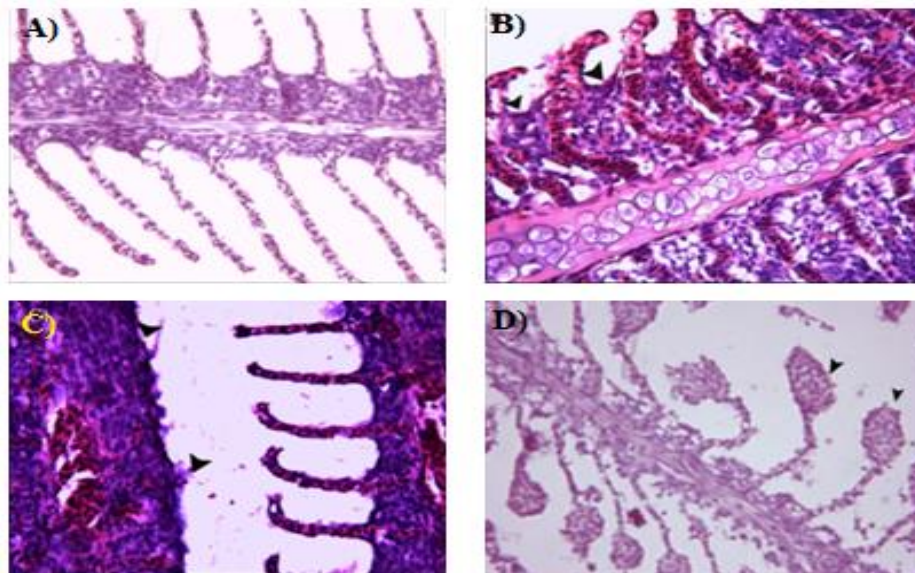


Figure 1: Photomicrograph of the normal gills in control (A) and diclofenac treated (B-D) gills of *Cyprinus carpio* (A) showing the normal appearance of gill filaments and the lamellae (H&E, X40 objective). B) Fusion and congestion of the gill lamella (arrow heads) of *C. carpio* 14 days after exposure to 1.25 mg L⁻¹ diclofenac (H&E, X40 objective). C). Fusion and disappearing of secondary lamellae (arrow heads) of the gill of *C. carpio* after 14 days of exposure to diclofenac 1.25 mg L⁻¹, (H&E, X40 objective) D) Clubbing of the gill of *C. carpio* after exposure to 2.5 mg L⁻¹ diclofenac for 21 days (arrow heads) (H&E, X40 objective).

The kidney of diclofenac–exposed fish showed distinct renal changes. This alteration consisted of a severe hyaline droplet, degeneration of tubular epithelial

cells, shrinkage of glomeruli, increasing of interstitial cells, necrosis of glomeruli and presence of melanomacrophages.

Table 2: Histopathological finding of *Cyprinus carpio* kidney exposed to various sublethal concentrations of diclofenac at 25°C.

Histopathological finding	Day7			Day14			Day21		
	1.25 mg L ⁻¹	2.5 mg L ⁻¹	5 mg L ⁻¹	1.25 mg L ⁻¹	2.5 mg L ⁻¹	5 mg L ⁻¹	1.25 mg L ⁻¹	2.5 mg L ⁻¹	5 mg L ⁻¹
General necrosis of hepatocytes	-	-	-	+	++	+++	++	+++	+++
Presence of melanomacrophages	-	-	-	-	+	+	-	+	+
Hypertrophy of hepatocytes	+	+	+	++	++	++	++	+	+++
Sinus dilation	-	-	+	-	-	-	-	-	+
Vacuolar degeneration of hepatocytes	+	+	+	+	++	+++	++	++	+++
Cloudy swelling of hepatocytes	-	-	-	-	+	++	-	+	+

+ = mild changes (10 percent changes in X40 objective microscopic view).

++ = moderate changes (20 percent changes in X40 objective microscopic view).

+++ = severe changes (more than 20 percent changes in X40 objective microscope view).

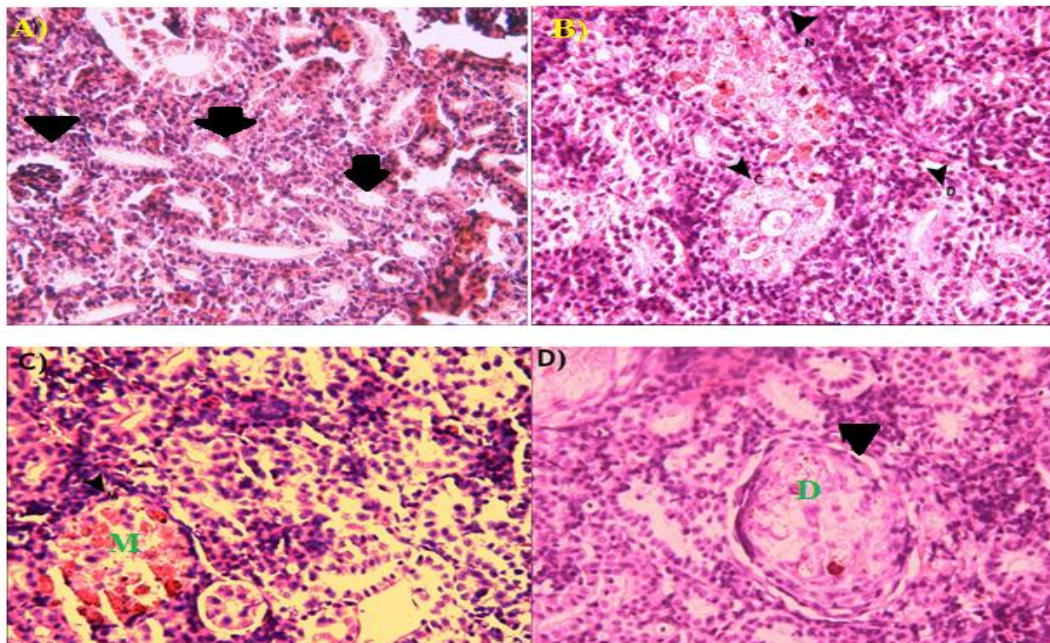


Figure 2: Photomicrograph of the normal kidneys in control (A) and diclofenac treated (B-D) kidneys of *Cyprinus carpio* (A) showing normal appearance of the glomerulus and the Bowman's space (arrow heads), proximal and distal tubules (arrows) (H&E, X40 objective). B) Degeneration of cells of distal tubules (D), and cloudy swelling degeneration and necrosis (N) of the kidney tubules (C) of *C. carpio* after exposure to 1.25mg L⁻¹ diclofenac for 7 days. (H&E, X40 objective). C) Presence of melanomacrophages (M) in the kidney of *C. carpio* after 14 days exposure to 1.25 mg L⁻¹ diclofenac (H&E, X40 objective). D) Degeneration of kidney (D) of *C. carpio* after 21 days exposure to 2.5 mg L⁻¹ diclofenac (H&E, X40 objective).

Alteration of Diclofenac – exposed liver, showed distinct changes. These alterations consisted of degeneration of hepatocyt,

vacuolation of hepatocyt, necrosis, congestion and presence of melanomacrophages.

Table 3: Histopathological findings of *Cyprinus carpio* liver exposed to various sublethal concentrations of diclofenac at 25 °C.

Histopathological findings	Day7			Day14			Day21		
	1.25 mg L ⁻¹	2.5 mg L ⁻¹	5 mg L ⁻¹	1.25 mg L ⁻¹	2.5 mg L ⁻¹	5 mg L ⁻¹	1.25 mg L ⁻¹	2.5 mg L ⁻¹	5 mg L ⁻¹
Hyalin droplet	-	-	-	-	-	+	+	+	+
Degeneration of tubular epithelial cells	+	+	+	+	++	++	+	++	+++
Necrosis of glomerular	+	++	++	+	++	++	++	++	++
Increasing of interstitial cells	+	++	++	+	++	+++	+	++	+++
Shrinkage of glomeruli	-	-	+	+	+	++	+	+	++
Presence of melanomacrophages	+	+	-	+	+	+	+	+	++

+ = mild changes (10 percent changes in 40x objective microscopic view).

++ = moderate changes (20 percent changes in 40x objective microscopic view).

+++ = severe changes (more than 20 percent changes in 40x objective microscope view).

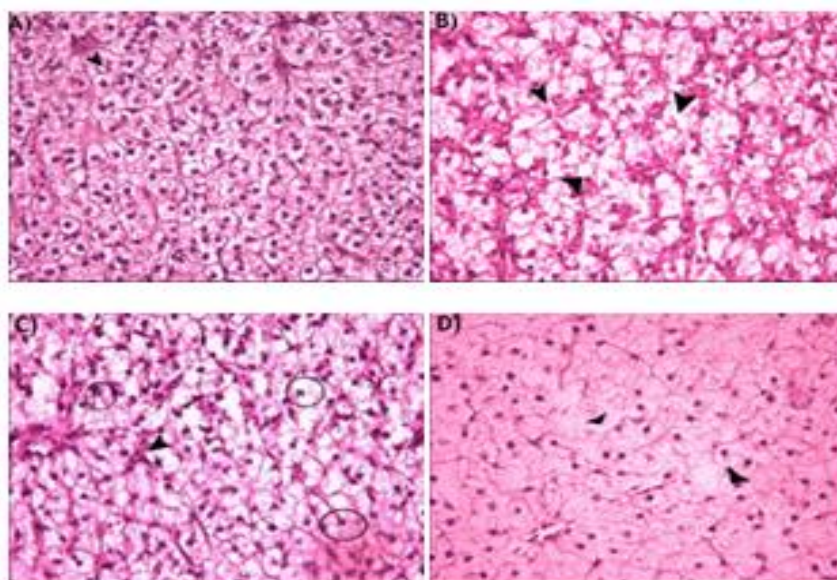


Figure 3: Photomicrograph of the normal liver (A) and diclofenac treated (B-D) of *Cyprinus carpio* (A) showing normal aspect of hepatocytes (arrow head). B) General necrosis of hepatocytes (arrow heads) of the liver of *C. carpio* after 7 days exposure to 1.25 mg L⁻¹ diclofenac. C) Sinus dilation (S) and general necrosis (small circles) of hepatocytes of the liver of *C. carpio* after 7 days exposure to 1.25 mg L⁻¹ diclofenac (H&E, X40 objective). D) General necrosis of hepatocytes (arrow heads) of the liver of *C. carpio* after 7 days of exposure to 1.25 mg L⁻¹ diclofenac (H&E, X40 objective).

The trend of alteration in gills, liver and kidney progressed with increase in concentration and time of exposure, whereas the most alterations were after 21 day exposure to the highest concentration of diclofenac in this study.

Discussion

Diclofenac represents a widely applied antiphlogistic and antirheumatic drug with

an estimated prescription amount all over the world.

The goal of the present study was to detect possible effects of diclofenac on the vital organs of *C. carpio*. Examination of vital organs such as gills, kidney and liver of *C. carpio* exposed to three different concentrations diclofenac for three weeks showed that the severity of tissue damage

depends on the concentration and duration of exposure.

The most contact between fish and polluted water occurred in the gills. Gill tissue damage and changes in the immune response against the toxin and pollution was studied by Reddy and Rawat (2013). The gills separate the blood from the water only by a few micrometers (Wood and Soivio, 1991) which not only facilitates the exchange of gases, but also allows the gill tissue to be exposed to variations in the environment. Consequently, the existence of toxic materials in the environment causes alterations in the vital functions carried out by the gills and changes in the morphologic structure of the gills (Poleksic and Mitrovic –Tutundzic, 1994).

The present study, revealed severe alternation of the gills in diclofenac exposed *C. carpio*. The predominant finding, which occurred after exposure, consisted of epithelial hyperplasia, telangiectasia, clubbing and lamellar fusion. At higher concentrations, hyperplasia and fusion of lamellae were particularly remarkable in 14 and 21 days post exposure.

Epithelial hyperplasia reduces contact between water and gills and consequently in a reduction of the ion and gas exchange. In the present study, diclofenac causes dilation of blood vessels and the accumulation of blood cells. Changes in pillar cells and blood vessels increase blood flow in the lamella (Martinez *et al.*, 2004). Alteration like hyperplasia and hypertrophy of epithelial cells, and fusion of some secondary lamellae are examples of defense mechanisms, which generally result in increasing the distance between the external environment and the blood,

which acts as a barrier preventing the entry of contaminants (Mallatt, 1985; Hinton and Lauren, 1990; Poleksic and Mitrovic-Tutundzic, 1994; Fernandes and Mazon, 2003). According to various studies lifting is always caused by edema of secondary lamella. This phenomenon can be a defense mechanism. Severe epithelial separation plates increase the distance between the pollutant and blood flow (Arellano *et al.*, 1999). Telangiectasia aggregation and accumulation of erythrocytes in the secondary lamella occur due to the destruction of capillary pillar cells (Hadi and Alwan, 2012). Fusion and hyperplasia occurred due to increased mitotic divisions in the epithelial layers of the epithelium of the gill plates (Karlsson *et al.*, 1985). Also suggested hyperplasia and fusion of secondary lamellae was caused by the toxin, which changes the ingredients of glycoproteins in mucosal cells, finally detaching the next lamella (, 1989; Kantham and Richards, 1995). Histopathological alteration like hyperplasia, epithelial lifting and fusion of some secondary lamellae are defense mechanisms of the body that increase the distance between the blood and the environment, preventing pollution to the body of the fish (Fernandes and Mazon, 2003).

It is assumed that gill alternation might interfere with normal respiratory function. Such histopathological alterations have been reported by other workers using diclofenac on other species of fish. In trout exposed to diclofenac, degeneration and necrotic changes of pillar cells as well as dilation of capillary was reported (Schawaiger, *et al.*, 2004). Also brown trout (*Salmo trutta fario*) exposed to

diclofenac resulted in telangiectasia in gills (Hoeger *et al.*, 2005), while no effects of chronic exposure of Zebra fish (*Danio rerio*) to diclofenac was reported (Praskova *et al.*, 2014). In a project, Wolf *et al.* (2014) reviewed histopathologic specimens from three laboratory studies of diclofenac in trout. The results showed that diclofenac exposure included increased thickening of the gill filament tips in fish exposed to diclofenac.

Kidneys, in all fish are one of the first organs that are affected by water pollutants. Due to the importance of all the waste, the aim of the present study was to evaluate the histologic changes induced by diclofenac in *C. carpio*.

In this study, histopathological examination of diclofenac –exposed fish revealed alternation of the kidney such as increase in interstitial tissue, hyaline droplet, and degeneration of the tubular epithelial cells and presence of melanomacrophages. Impairments of the renal function is likely to also occur in fish after chronic exposure. Nephrotoxicity of diclofenac is thought to be mainly due to the inhibition of prostaglandin synthesis and acts by inhibiting one or both isoforms of the cyclooxygenase enzymes COX-1 or COX-2, involved in the synthesis of prostaglandins (Gagné *et al.*, 2006). Diclofenac is thought to be the most toxic member of this group the effect of which is known to occur by damaging renal and gastrointestinal tissue across several vertebrate taxa (Happ *et al.*, 2008). Degeneration of epithelial cells of tubules distinguished cellular hypertrophy in teleost (Happ *et al.*, 2008). The destruction of the kidney glomeruli may also be the result of drugs which disrupt

the structure and function of the glomeruli. Also melanomacrophage may result in destruction of blood cells (Agius and Roberts, 2003). Contaminants in fish habitats can cause non-specific immune system changes. Melanomacrophage can be resized physiologically or the effects of pollutants in the melanomacrophage in kidney and can change spleen size (Kelley-Reay and Weeks-Perkins, 1994).

The kidney lesion in rainbow trout, at least partly seems to be comparable to those found in other diclofenac exposed rainbow trout and brown trout (Hoeger *et al.*, 2005). However, no alternation was observed with the same exposure in Zebra fish (*D. rerio*) (Praskova *et al.*, 2014).

Liver in fish is the place for metabolism, which has an important role in the detoxification of pollutants from the whole body. Expected alteration in hepatocytes of exposed fish to diclofenac, is used as a tool in toxicology researches. Also hepatocytes of fish are considered as a biomarker in polluted water (Altinok *et al.*, 2006). Hepatocellular injury based on the concentration and duration of exposure, and other cases are different (Reddy and Rawat, 2013).

The histopathological alterations observed in liver of diclofenac – exposed carp included congestion of blood vessels and sinus dilation, melanomacrophages aggregates, degeneration of hepatocytes and necrosis. The findings of this study indicated hepatic sinusoidal dilation in fish exposed to concentrations of 5, 2.5 and 1.25mg L⁻¹ of diclofenac.

The severity of these injuries increased with increasing concentrations of diclofenac. In the liver of fish exposed to

diclofenac, vacuolization of hepatocyte necrosis was observed. It seems that the formation of vacuoles in hepatocytes is a defensive action in the face of diclofenac and to prevent the release of the drug. Abnormal accumulation of triglycerides and other fats may lead to the creation of vacuoles in hepatocytes and ultimately necrosis is associated with tissue damage (Kelly and Janz, 2009). Formation of vacuoles in hepatocytes is a defensive mechanism (Mollendorff, 1973) raising material damage and preventing disruption of the biological activity of the organ. (Hadi and Alwan, 2012). Total damage observed in the liver led to inhibition of the release of toxins in the body of other fishes. (Klaassen and Warkins, 1984). High liver enzyme is also a potential for the destruction of toxic compounds. Sinus dilation could be considered as a defense mechanism of fish to dilute the poison in blood and to boost the immune system. However, Braunbeck *et al.* (1990) reported that increase of metabolical activity caused alteration in shape and size of cells to eliminate the injured materials. Sand and his college believed that necrosis of hepatocytes through the inhibition of DNA synthesis is required for the growth and maturation of cell contaminants (Sand *et al.*, 1997).

The presence of melanomacrophages may be due to exposure of fish to diclofenac and inflammation in the body of fish. Melanomacrophages are also naturally present in the fish in the production of blood cells in the spleen and kidney and liver (Agius and Roberts, 2003). Severe damage to the liver in the fish *Cyprinus carpio* increased with increasing concentrations of diclofenac.

The hepatocytes have undergone several stages of degeneration before the complete necrosis. The result of our study showed that hepatocytes were quite sensitive to diclofenac. When the toxin entered the liver via the hepatic portal vein, it is removed by a process known as pre-systemic hepatic elimination. This process prevents or at least minimizes, the distribution of foreign chemicals to other parts of the body (Klaassen and Warkins, 1984). The liver shows a high potential of enzymatic degeneration of toxic compounds, but it may be itself adversely affected by their high concentration (Bruslé and Anadon, 1996). The histopathological changes in vital organs of *Cyprinus carpio* exposed to diclofenac in this study were similar to other reports about this toxin. Liver tissue damage in fish exposed to diclofenac has been reported by several authors (Tribeskorn *et al.*, 2004; Wolf *et al.*, 2014; Praskova *et al.*, 2014). Similar changes in the liver of brown trout and rainbow trout exposed to diclofenac have been reported (Hoeger *et al.* 2005) It was demonstrated that diclofenac was not completely excreted through first pass metabolism in brown trout, but that a significant part of the applied diclofenac entered hepatic circulation and increased monocytes in the liver (Hoeger *et al.*, 2005).

Praskova *et al.*, (2014), demonstrated histopathological alteration in Zebrafish (*D. rerio*) in subchronic exposure of diclofenac, and the range of sublethal concentrations of diclofenac (5, 15, 30 and 60 mg L⁻¹) was for 28 days. Therefore, it seems *C. carpio* is more sensitive than *D. rerio*.

In conclusion, the present study shows that diclofenac can cause serious histopathological alternations in vital organs of *C. carpio*. The histopathologic analysis of fish organs has been used as a tool that is extremely important in the evaluation of the toxic effects of diclofenac on carp. The severity of histopathological changes depend on toxicant dose and time of exposure of fish to diclofenac.

References

- APHA, 1998.** In: Clesceri, L.S., Greenberg, A. E., Eaton, A. D.,(Eds.) Standard methods for the examination of water and waste-water 20th edition . Washington, American Public Health Association. 541 P.
- Agius, C. and Roberts, R., 2003.** Melanomacrophage centers and their role in fish pathology. *Journal of Fish Diseases*, 26, 499–509.
- Altinok, I., Capkin, E., Karahan, S. and Boran, M., 2006.** Effects of water quality and fish size on toxicity of methiocarb, a carbamate pesticide to rainbow trout. *Environmental Toxicology and Pharmacology*, 22, 20-26.
- Arellano, J.M., Storch, V. and Sarasquete, C., 1999.** Histological changes and copper accumulation in liver and gills of the *Senegales sole*, *Solea senegalensis*. *Ecotoxicology and Environmental Safety*, 44, 62-72.
- Braunbeck, T. Storch, V. and Bresch, H., 1990.** Species –specific reaction of liver ultrastructure in zebra fish, *Brachydanio rerio* and trout *Salmo gairdneri* after prolonged exposure to 4-chloroaniline. *Archive of Environmental Contamination and Toxicology*, 19, 405-418.
- Bruslé, J. and Anadon, G.G., 1996.** The structure and function of fish liver. In: *Fish Morphology*. Science Publishers, pp. 77-93.
- Eslami, A., Amini, M.M., Yazdanbakhsh, A.R., Rastkari, N., Mohseni-Bandpei, A. Naseri, S. and Piroti Asadi, A., 2015.** Occurrence of non-steroidal anti-inflammatory drugs in Tehran source water, municipal and hospital wastewater and their ecotoxicological risk assessment. *Environmental Monitoring and Assessment*, 187(12), 734. DOI: 10.1007/s10661-015-4952-1.
- Fent, K., Watson, A.A. and Camminada, D., 2006.** Ecotoxicology of human pharmaceuticals. *Aquatic Toxicology*, 76, 122-159.
- Fergosen, H.W., 1989.** Systemic pathology of fish, Iowa State University Press, Ames. 263 P.
- Fernandes, M.N. and Mazon, A.F., 2003.** Environmental pollution and fish gill morphology. In Val, A.L. & B. Gkapoor (Eds.). *Fish adaptations*. Enfield, Science Publishers. pp. 203-231.
- Gagné, F., Blaise, C. and André, C., 2006.** Occurrence of pharmaceutical products in a municipal effluent and toxicity to rainbow trout (*Oncorhynchus mykiss*) hepatocytes. *Ecotoxicology and Environmental Safety*, 64, 329–336.
- Guiloski, I.C., Ribas, J.C., Pereira, L.S., Perbiche Neves, A.P. and Silvade Assis, H.C., 2015.** Effects of trophic exposure to dexamethasone and diclofenac in freshwater fish.

- Ecotoxicology and Environmental Safety*, 114, 204-211.
- Hadi, A.A. and Alwan, S.F., 2012.** Histopathological changes in gills, livers and kidneys of fresh water fish, *Tilapia zillii*, exposed to aluminium. *International Journal of Pharmacy and Life Sciences*, 3(11), 2071-2081.
- Happ, T., Triebkorn, R. and Kohler, H.R., 2008.** Acute effects of diclofenac and DMSO to *Daphnia magna*: immobilization and hsp70-induction. *Chemosphere*, 73, 353-359.
- Heberer, T. and Stan, H.J., 1998.** Determination of clofibric acid and N-(phenylsulfonyl) sarcosine in sewage, river and drinking water. *International Journal of Environmental Analytical Chemistry*, 67(1-4), 113-123.
- Hinton, D.E. and D.J., Lauren, 1990.** Liver structural alterations accompanying chronic toxicity in fishes: Potential biomarkers of exposure. In: Mc Carthy, J. F. & L. R. Shugart (Eds). Biomarkers of environmental contamination. Boca Raton, Lewis Publishers. pp. 51-65.
- Hoeger, B., Kollner, B., Dietrich, D.R. and Hitzfeld, B., 2005.** Water-born diclofenac affects kidney and gill integrity and selected immune parameters in brown trout (*Salmo trutta fario*). *Aquatic Toxicology*, 75, 53-64.
- Islas-Flores, H., Gomez-Olivan, M., Galar-Martinez, M., Colin-Cruz, A., Neri-Cruz, N. and Garcia-Medina, S., 2013.** Diclofenac- induced oxidative stress in brain, liver, gill, and blood of common carp (*Cyprinus carpio*). *Ecotoxicology and Environment Safety*, 92, 32-38.
- Karlsson—Norrger, L., Runn, P., Haux, C. and Forlin, L., 1985.** Cadmium-induced changes in gill morphology of Zebrafish, *Brachydanio rerio* (Hamilton-Buchanan), and rainbow trout, *Salmo gairdneri* Richardson. *Journal of Fish Biology*, 27, 81-95.
- Kantham, K.P. and Richards, R.H., 1995.** Effect of buffers on the gill structure of common carp, *Cyprinus carpio* and rainbow trout, *Oncorhynchus mykiss*. *Journal of Fish Diseases*, 18, 411-423.
- Kelley-Reay, K. and Weeks-Perkins, B.A., 1994.** Determination of the macrophage chemiluminescent response in *Fundulus heteroclitis* as a function of pollution stress. *Fish and Shellfish Immunology*, 4, 95–105.
- Kelly, J.M. and Janz, D.M., 2009.** Assessment of oxidative stress and histopathology in juvenile northern pike (*Esox lucius*) inhabiting lakes downstream of uranium mill. *Aquatic Toxicology*, 92, 240-249.
- Klaassen, C.D. and Warkins, J.B., 1984.** Mechanisms of bile formation, hepatic uptake, and biliary excretion. *Pharmacological Reviews*, 36(1), 1-67.
- Mallatt, J., 1985.** Fish gill structural changes induced by toxicants and other irritants: a statistical review. *Canadian Journal of Fish and Aquatic Sciences*, 42, 630-648.
- Mollendorf, A., 1973.** Cytology cell physiology, (3rd edn), Academic Press New York. pp.1-10.
- Poleksic, V. and Mitrovic-Tutundzic., 1994.** Fish gills as a monitor of sub lethal and chronic effects of pollution. In: Muller, R. & R. Lloyd (Eds.). Sub lethal and chronic effects of pollutants

- on fresh water fish. Oxford, Fishing News Books. pp. 339-352.
- Praskova, E., Plhalova, Chromcova, L., Stainslava, S., Bedanova, I., Blahova, Hostovsky, M., Skoric, M., Marsalek, Voslarova, p. and Svobodova, Z., 2014.** Effects of subchronic exposure of diclofenac on growth, histopathological changes, and oxidative stress in zebrafish (*Danio rerio*), *The Scientific World Journal*, 2014, 645737.5 pages. DOI: 10.1155/2014/645737.
- Reddy, P.B. and Rawat, S.S., 2013.** Assessment of aquatic pollution using histopathology in fish as a protocol. *International Research Journal of Environment Sciences*, 2(8), 79-82.
- Sacher, F., Lange, F.T., Brauch, H.J. and Blankenhorn, I., 2001.** Pharmaceuticals in groundwaters: analytical methods and results of a monitoring program in Baden-Wuttemberg, Germany. *Journal of Chromatography*, A938(1/2), 199-210.
- Salmani, M.H., Mokhtari, M.R., Raeisi, Z., Ehrampoush, M.H. and Sadeghian, H.A., 2017.** Evaluation of removal efficiency of residual diclofenac in aqueous solution by nanocomposit tungsten-carbon using design of experiment. *Water Science and Technology*, 76(1),1466-1473. DOI:10.2166/wst.2017.318
- Sand, S.M., El-Nahass, E.M., Abdel-Gawad, A.M. and Aldeeb, M., 1997.** Histochemichal studies on the liver of mice following chronic administration of sodium barbitone. *Journal of German Society Zoology*, 22, 127-165.
- Santose, L.H.M.L.M., Araujo, A.N., Fachini, A., Pena, A., Delerue- Matos, C. and Montenegro, M.C.B.S.M., 2010.** Ecotoxicological aspects related to the presence of pharmaceuticals in the aquatic environment. *Journal of Hazardous Materials*, 175, 45-95.
- Saravan, M., Karthika S., Malarvizhi, A. and Ramesh M., 2011.** Ecotoxicological impacts of clofibrac acid and diclofenac in common carp (*Cyprinus carpio*) fingerlings: Hemological, biochemical, ionoregulatory and enzymological responses. *Journal of Hazardous Materials*, 195, 188-194.
- Schawaiger, J., Ferling, H., Malliw, U., Wintermayr, H. and Negele, R.D., 2004.** Toxic effects of the non-steroidal anti – inflammatory drugdiclofenac. Part I: histopathological alteration and bioaccumulation in rainbow trout. *Aquatic Toxicology*, 68, 141-150.
- Sharifpour, I., Koshbavar-Rostami, H.A. and Mokarami-Rostami, A., 2014.** Sublethal toxicity of organophosphate, diazinon on some organs of great sturgeon (*Huso huso*). *Iranian Journal of Aquatic Health*, 1, 27-35.
- Stavonca, V., Plhalova, L., Bartoskova, M., Zinva, D., Prokes, M., Marsalek, P., Blahova, J., Skoric, M. and Svobodova, Z., 2014.** Effects of Mixture of Pharmaceuticals on Early Life Stage of Tench (*Tinca tinca*). *BioMed Research International*, 2014, Article ID 253468, 10 P
- Stumpf, M., Terners, T., Herbere, K., Sell, P. and Baumann, W., 1996.** Nachweis von Arzneimittelruckstanden in klananlagen und Fliessgewassern. *Vom Wasser*, 86, 291-303.

- Ternes, T.A., 1998.** Occurrence of drugs in German sewage treatment plants and rivers. *Water Research*, 32, 3245-3260.
- Triebkorn, R., Casper,H., Heyd,A., Eikemper, R., Kohler, H-R. and Schwaiger, J., 2004.** Toxic effects of the non-steroidal anti-inflammatory drug diclofenac. Part II. Cytological effects in liver, kidney, gills and intestine of rainbow trout (*Oncorhynchus mykiss*). *Aquatic Toxicology*, 68, 151-166.
- Webb, S.F., 2001.** A data based perspective on the environmental risk assessment of human pharmaceuticals II –aquatic risk characterisation. In: Kümmerer, K. (Ed.), *Pharmaceuticals in the environment. Sources, fate, effects and risks.* Springer-Verlag Berlin, Heidelberg, New York. pp. 203–219.
- Wolf, J.C., Ruehler-Fehlert, C., Senger, E.H., Weber, K. and Hardisty, J.F., 2014.** Pathology working group review of histopathologic specimens from three laboratory studies of diclofenac in trout. *Aquatic Toxicology*, 146, 127-136.
- Wood, Ch.M. and Soivio, A., 1991.** Environmental effects on gill function: an introduction. *Physiological Zoology*, 64(1), 1-3.