

## Isolation and phylogenic analysis of emerging new antibiotic resistant bacteria, *Acinetobacter lwoffii*, associated with mortality in farmed rainbow trout

Dadar M.<sup>1</sup>; Adel M.<sup>2\*</sup>; Zorriehzahra M.J.<sup>2</sup>

Received: May 2016

Accepted: September 2016

### Abstract

Whereas it is well documented that the genus *Acinetobacter* is associated with antibiotic resistant bacteria and human clinical infections, there are very few studies to date that report it as an emerging new pathogen for fish. In the present study, *Acinetobacter lwoffii* was isolated from diseased rainbow trout (*Oncorhynchus mykiss*) from Iranian farms, in the Khuzestan Province by both biochemical tests and polymerase chain reaction (PCR)-based methods and further confirmed as the causative agent by infectivity experiment. Uni or bilateral exophthalmia, blackening of the skin, abdominal distension, hemorrhages around the mouth cavity and eyes, basal fine, skin, gills and in internal organs were the main clinical signs in the affected fish. Phylogenetic analysis of the *16S rRNA* sequence of MD77 revealed a 99% homology with that of *A. lwoffii* (GenBank accession no.KR856323.1) form Iran. Histopathological changes of challenged rainbow trout including focal necrosis of liver cells (hepatocyte), pyknotic nucleus and karyolysis of hepatocyte, hyperemia, fatty acid composition change of liver, infiltration of inflammatory cells, sinusoidal dilatation and congestion. The drug resistance of isolates and minimal inhibitory concentration (MIC) was examined and showed that *A. lwoffii* was multiresistant to 8 of the antimicrobial agents tested.

**Keywords:** *Acinetobacter lwoffii*, Phylogenic analysis, Pathogenic effects, Drug resistance, *Oncorhynchus mykiss*, Iran

---

1-Razi Vaccine and Serum Research Institute, Agricultural Research, Education and Extension Organization (AREEO), Karaj, Iran.

2-Department of Aquatic Animal Health & Disease, Iranian Fisheries Science Research Institute (IFSRI), Agricultural Research Education and Extension Organization (AREEO), P.O.Box: 13185-116, Tehran, Iran.

\*Corresponding author's email: miladadel65@gmail.com; miladadel85@yahoo.com

## Introduction

*Acinetobacter*, belonging to family Moraxellaceae, class  $\gamma$ -Proteobacteria and order Pseudomonadales, is a genus of gram-negative, non-motile, non-fermentative rods, oxidase-negative, aerobic bacteria which are widely distributed in the different environment including water, soil, human, plant, aquatic organisms, the polar region, hydrocarbon-contaminated sites and sediments (Baumann, 1968; Berlau *et al.*, 1999; Joly-Guillou, 2005; Yonar *et al.*, 2010; Kostka *et al.*, 2011; Naviner *et al.*, 2011; Jung and Park, 2015). The genus comprises both nonpathogenic and pathogenic species (de Berardinis *et al.*, 2009). Most strains of these organisms grow at a wide range of temperatures (El-Sayyad *et al.*, 2010; Doughari *et al.*, 2011). Within the *Acinetobacter* genus, *Acinetobacter lwoffii*, a pathogen resistant to a range of antibiotics, is the causative agent of a nosocomial infections, including bacteraemia, secondary meningitis, urinary tract infection, surgical sites infection, gastritis and pneumonia, especially in intensive care unit (ICU) patients (Zavros *et al.*, 2002). While this pathogen is well documented to be associated with multi-drug resistant bacteria and human clinical infections, to the best of our knowledge, to date there was only one report that described it as a pathogen for fish. *A. lwoffii* was for the first time isolated by Kozińska *et al.* (2014) from common carp in Poland and identified in terms of its biochemical and molecular

characteristics. Other species of *Acinetobacter* were isolated from Mandarin fish, *Siniperca chuatsi* (Gu *et al.*, 1996) and channel catfish (*Ictalurus punctatus*) in China (Xia *et al.*, 2008). During the last decade, antibiotic resistant bacteria became an important environmental contamination issue, and there is a growing concern about the persistence and epidemic spread of these organisms in the environment (Harnisz *et al.*, 2011; Maravić *et al.*, 2015). The genes of resistance to antibiotics can be transferred between bacteria in the environment through plasmids, integrons and transposons (Dijkshoorn *et al.*, 2007). Infections caused by resistant strains of *Acinetobacter* spp. are costly to treat in fish and humans. These infections prolong the pathological situations and if they are not treated with the right antibiotics they can increase mortality, morbidity and risk of antibiotic-associated adverse events (Peleg *et al.*, 2008).

The main aim of our research was the identification, as well as the determination of genotype relations and clinical features of *Acinetobacter* sp. resistant to antibiotic treatment in rainbow trout farms.

## Material and methods

### *Fish sampling*

During the incidence of antibiotic resistant bacteria in 2015, *Acinetobacter* sp. was isolated from rainbow trout of Iranian farms. A total of 100 moribund rainbow trout

weighing  $70\pm 30$  g (mean $\pm$ SD), originating from two farms, in Khuzestan Province, (Southwest of Iran) were investigated during May and September 2015. Clinical signs of diseased fish included exophthalmia, blackening of the skin, as well as hemorrhages around the eyes, base of dorsal and caudal fins, skin, gills and internal organs. The farms were run on a flow-through system of fresh water at a temperature of  $17\pm 3^\circ\text{C}$ . The moribund fish were selected and transferred to the Central Veterinary Laboratory, Ahvaz, Iran. Mortality rate among the fish was 28-30% especially in the trout population on warm days. The disease was noted in different seasons, but was most common in May and September.

#### *Isolation of bacteria*

The body surface and gills were carefully swabbed using 70% ethyl alcohol to remove normal external bacterial flora. After opening the body cavity, the brain, eyes, liver, kidney, and spleen were aseptically removed. Bacterial subculturing was done under the conditions described in Kozińska *et al.* (2014). Briefly, the samples were diluted (1:1) in PBS and homogenized. Then they were inoculated onto tripticase soya agar (TSA, Sigma, USA) and nutrient agar (Sigma, USA) and supplemented with 5% horse blood (BA). After incubating at  $28^\circ\text{C}$  for 24 h, bacteria isolated from rainbow trout were subcultured onto TSA to check the purity of the isolation. The isolated bacterial strain was named as MD77.

Pure cultures of isolate were stored at  $4\pm 1^\circ\text{C}$  for further examination.

#### *Phenotypic characterisation of the isolate*

Morphology of colonies was investigated and recorded. Then, pure culture of MD77 isolate was characterized with Gram-staining and biochemically tested as described previously (Gu *et al.*, 1996; Kozińska *et al.*, 2014).

#### *PCR and sequencing*

Molecular identification of isolates was conducted by sequencing of 16S rDNA gene fragment as described in different works elsewhere (Marchesi *et al.*, 1998). Briefly, genomic DNA was extracted from a pure culture using the genomic DNA purification kit (GeneAll) according to the manufactures' instructions. The extracted DNA was amplified using a polymerase chain reaction (PCR) kit in accordance with the manufacturer's protocol (Qiagen, Germany). Nearly full length 16S rDNA genes were amplified using the 1492r primer (5'-GGTTACCTTGTTACGACTT--3') and one of the following three 27f primer formulations: twofold-degenerate primer 27f (5'-AGAGTTTGATCMTGGCTCAG-3', where M is A or C). The thermal PCR steps were 1 cycle  $95^\circ\text{C}$  for 2 min, followed by 35 cycles of denaturation at  $95^\circ\text{C}$  for 30 sec, annealing temperature at  $50^\circ\text{C}$  for 30 sec and extension at  $72^\circ\text{C}$  for 1 min. This was followed by a final extension of 10 min at  $72^\circ\text{C}$ . The PCR

products were separated by agarose gel electrophoresis, purified with gel extraction kit (Qiagen, Germany), and subjected to nucleotide sequence analysis by dideoxy chain termination method. The 16S rDNA gene sequence of four isolates and the representatives of the other species from GenBank database were analyzed using MEGA 6 software. Similarity between the sequences of the tested isolates and sequences available at GenBank was defined by the use of MEGA 6 software. The amplified fragments were sequenced and deposited in the NCBI database with the accession number KU695542.

#### *Phylogenetic analysis*

The sequence data were analyzed using Blast (NCBI), Mega 6 software. Finally, the results were compared with other existing sequences in the data bank and a phylogenetic tree was produced by the maximum-likelihood analysis with bootstrap values corresponding to 1000 replications, using the Molecular Evolutionary Genetics Analysis (MEGA) 6 software.

#### *Antibiotic susceptibility test*

Testing of the antimicrobial susceptibility of obtained *Acinetobacter* was performed by disc diffusion method according to the recommendation of confirmed methods (Jones *et al.*, 2007; Reller *et al.*, 2009). All antimicrobial agents (sulfamethoxazole/trimetoprim (25µg/m), Oxytetracycline (30µg/mL),

Enrofloxacin (5 µg/mL), flumequine (30µg/mL), ampicillin (10 µg/mL), gentamicin (10µg/mL), chlorotetracycline (20µg/mL) and oxolinic acid (10µg/mL) were purchased from Sigma-Aldrich France. After 24 h incubation at 30 °C, isolates were defined as resistant using inhibition zones around the discs, breakpoint tables for interpretation of Minimum inhibitory concentrations (MICs) and zone diameters established by European Committee on Antimicrobial Susceptibility Testing (EUCAST) (2006) was used. *Pseudomonase aeruginosa* ATCC 27853 was used as quality control strain.

#### *Ethics statement*

For the protection of animals used for scientific purposes the experiments described comply with the Guidelines of the European Union Council [http://ec.europa.eu/environment/chemicals/lab\\_animals/legislation\\_en.htm](http://ec.europa.eu/environment/chemicals/lab_animals/legislation_en.htm) (Directive 2010/63/EU).]

#### *Experimental infection*

This study was conducted at Aquaculture Laboratory of Sari University. Rainbow trout fish with the average weight of 80±20 g were obtained from the Teleost Fish Propagation & Cultivation Centre, Mazandaran Province, Iran. The specimens were acclimatized for two weeks prior to the experiment. During the acclimatization period, fish were fed twice a day with a commercial feed (Mazand, Iran). Thereafter, the

specimens were randomly stocked into 6 fibreglass tanks (300 L) at a density of 15 fish per tank. During the rearing trial (28 days), fish were hand-fed twice a day (09:00 and 15:00) at the rate of 3% of body weight as described elsewhere. Water was recirculated through the filter at an average temperature of  $20 \pm 2$  °C. These fish had no history of disease or abnormality and were acclimated for 7 days before the challenge. The suspension of MD77 was grown in TSB for 24h at  $27 \pm 1$  °C with gentle rotation and was diluted in sterile PBS to achieve the concentration of  $1.0 \times 10^7$  CFU mL<sup>-1</sup> of *A. lwoffii*. In order to test Koch's postulate of *A. lwoffii*, 75 fish were injected intraperitoneally (IP) with 0.1 mL of the MD77 suspension and included as treatment group. Another group of 15 fish was injected with 0.1 mL sterile PBS as the control group. Each group of fish was placed in a separated tank and symptoms of disease were reported for 28 days. Freshly dead fish and survivals were investigated for further study.

#### *Histopathological study*

Ten days post challenge in  $1.0 \times 10^7$  CFU/mL of *A. lwoffii*, the liver and kidney of infected fish were removed by dissection of the abdominal cavity. The tissue samples were fixed in 10% buffered formaldehyde solution followed by alcohol dehydration and embedding in paraffin (Sharifpour *et al.*, 2014). Six-micrometer thick sections were stained with haematoxylin-eosin to study the histomorphometrical properties of tissues of rainbow trout and were interpreted under a light microscope.

#### **Results**

##### *Biochemical characteristics*

Colonies of Gram-negative bacteria were generally non-pigmented, pale yellow or grayish-white with a diameter of 1-2 mm and isolated from internal organs of fish on TSA and BA. The bacteria were strictly aerobic, catalase positive and oxidase negative as shown in Table 1, and most of the phenotype characteristics of MD77 are in accordance with the published results of Austin and Austin (2007).

**Table 1: Biochemical characteristics of *Acinetobacter lwoffii* isolated from infected fish.**

Characteristics	<i>A. lwoffii</i> (our study)	<i>A. lwoffii</i> Austin and Austin (2007)
Gram	-	-
Ornithine decarboxylase	+	+
Production of Indol	-	-
Production of H <sub>2</sub> S	-	-
Oxidase	-	-
Catalase	+	+
Ornithine decarboxylase	-	-
Reduction of nitrates	-	-
Production of acid from Maltose	-	+
Production of acid from Sucrose	-	-

**Table 1 continued:**

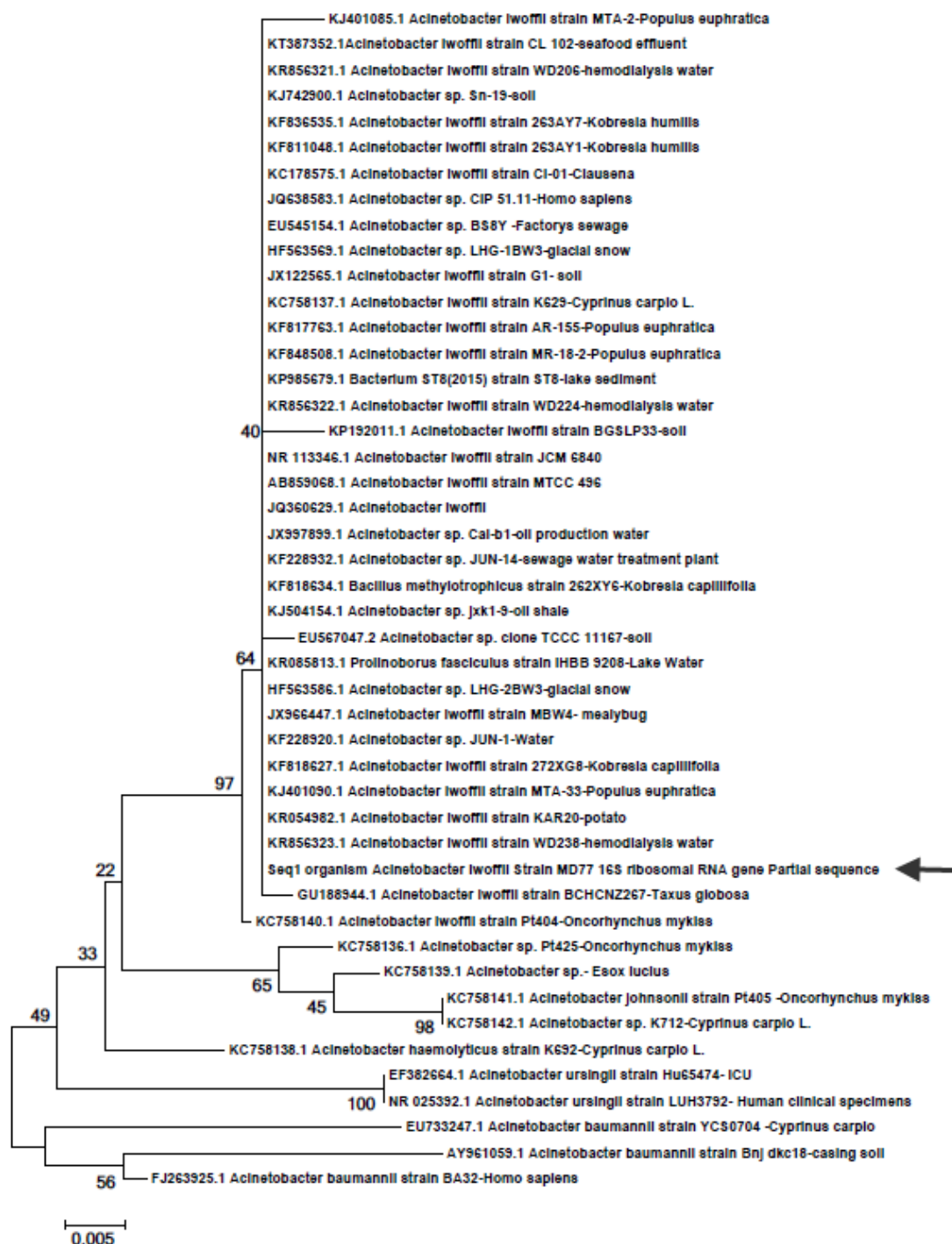
Production of acid from Rhamnose	-	-
Production of acid from Inositol	-	-
Production of acid from Mannitol	+	+
Production of acid from Glucose	+	+
Production of acid from Sorbitol	-	-
Urease	-	-
Growth in: 10-37 °C	+	+

+: Positive; -: Negative reactions

#### *Molecular identification*

A 1498 bp of cDNA fragment, coding the 16S rRNA, was amplified from the DNA extracted from the pure culture of MD77. After comparison with the sequences of 16S rRNA available in GenBank and phylogenetic analysis, the 16S rRNA sequence of MD77 revealed a 99% homology with that of *A. lwoffii*

(GenBank accession no.KR856323.1) (Fig. 1). There were only 5 base differences between the two sequences. Thus, bacteria isolated from the diseased rainbow trout were characterized as *A. lwoffii* by biochemical and phylogenetic analyses.



**Figure 1:** Phylogenetic relationship of Iranian *Acinetobacter* isolate and other reference strains using the maximum-likelihood method as implemented in mega 6 software. A Phylogenetic tree based on 16srDNA. A scale bar shows 0.005 substitutions per sequence position. Black arrow show the position Iranian Isolate in tree.

#### *Antibiogram test*

The results of the antibiogram test showed that the isolate bacteria were resistant to sulfamethoxazole/

trimetoprim (25µg/m), oxolinic acid (10µg/mL), enrofloxacin (5 µg/mL), but not to ampicillin (20 µg/mL), gentamicin (10µg/mL),

chlorotetracycline (20µg/mL), flumequine (30µg/mL) and oxytetracycline (30µg/mL).

#### *MIC tests*

The MIC values of sulfamethoxazole/trimetoprim(25µg/m), oxytetracycline (30µg/mL), enrofloxacin (5µg/mL), flumequine (30µg/mL), ampicillin (20µg/mL), gentamicin (10µg/mL), chlorotetracycline (20µg/mL) and oxolinic acid (10µg/mL) were 0.625 µg mL<sup>-1</sup>, 0.391 µg mL<sup>-1</sup>, 0.192 µg mL<sup>-1</sup>, 0.625 µg mL<sup>-1</sup>, 1.42 µg mL<sup>-1</sup>, 0.728 µg mL<sup>-1</sup> and 1.56 µg mL<sup>-1</sup>, respectively.

#### *Clinical signs*

The first clinical signs of disease were observed in challenged fish after 7 days and the first mortality was 9 days after IP injection. The main clinical signs observed post challenge included: uni or bilateral exophthalmia (Fig. 2), blackening of the skin, abdominal distension, hemorrhages around the mouth cavity and eyes, basal fins (Fig. 2), skin, gills and in internal organs such as kidney, liver and spleen. Also,

no mortality or clinical signs were observed in the control group. The cumulative mortality of affected fish in the treatment group was 30%. Experimentally infected trout had the same external and internal appearance as the diseased fish from Khuzestan province. The bacteria isolated from the internal organs of dead fish and surviving fish in the treatment group were identified as *A. lwoffii*.

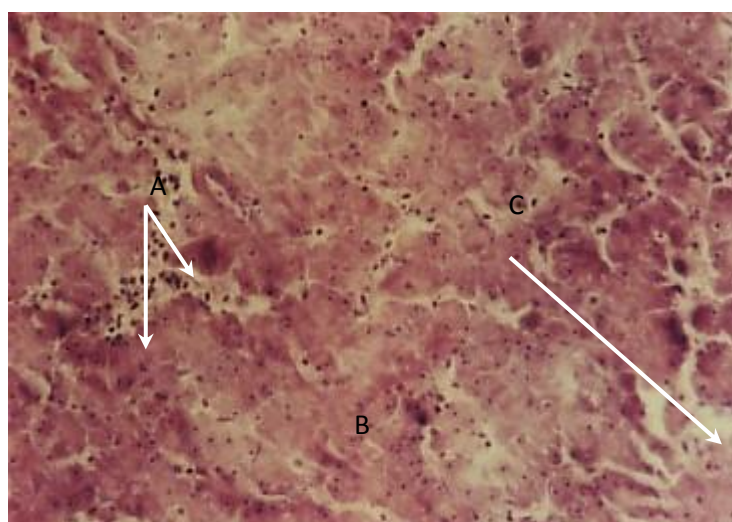
#### *Histological examination of tissues*

The histopathological damages were observed in several organs of challenged fish such as liver and kidney. Histopathological changes of liver in challenged rainbow trout included focal necrosis of liver cells (hepatocyte), pyknotic nucleus and karyolysis of hepatocyte, hyperemia, fatty change of liver, inflammatory cells infiltration, sinusoidal dilatation and congestion (Fig. 3). The damages to the kidney included glomerular vacuolation, increasing the space between glomerulus and bowman's capsule, and pyknotic nucleus of kidney cells (Fig. 4).

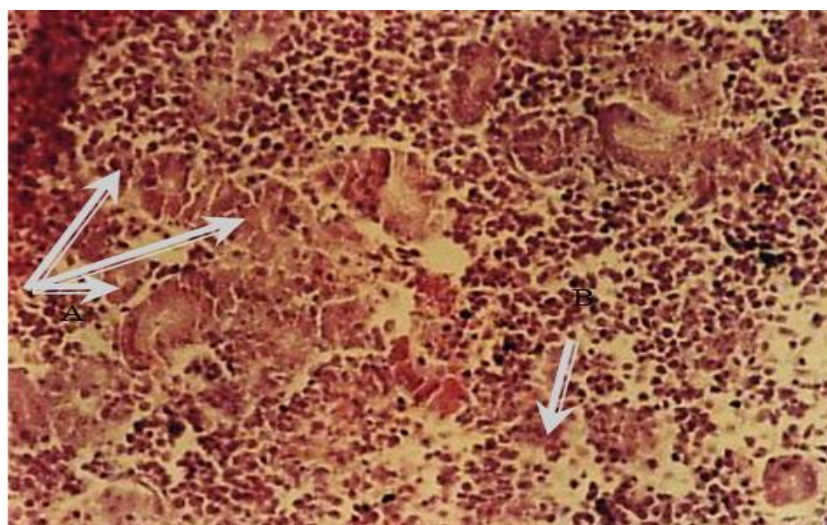




**Figure 2:** Bilateral exophthalmia and hemorrhages around the eyes and fin of infected rainbow trout challenge with  $1 \times 10^7$  cfu/mL of *Acinetobacter lwoffii* 10 days post challenge.



**Figure 3:** Inflammatory cells infiltration (A), focal necrosis (B) and liver sinusoids dilatation (C) (H&E, x100) in infected rainbow trout challenge with  $1 \times 10^7$  cfu/mL of *Acinetobacter lwoffii* 10 days post challenge.



**Figure 4:** Kidney tissues showing tubular necrosis (A) and haematopoietic (B) (H&E, x100).

## Discussion

The rainbow trout (*O. mykiss* Walbaum 1792) is undisputedly the most widely introduced and cultured salmonid fish across the globe, besides being extremely popular as a sport fish and an experimental fish. According to the results from studied farms with clinical signs of bacterial disease, all diseased fish were found to be *Acinetobacter*-positive by biochemical tests and PCR (100%). Farms that tested positive for *Acinetobacter* isolation were in the provinces of Khuzestan, with 30% mortality in plate size rainbow trout, and all fish showed external signs typical of bacterial disease. Previously reported *A. lwoffii* in common carp and MD77 isolates from rainbow trout in the present study have many phenotypic characteristics and clinical signs in common. Moreover, their 16S rDNA sequences are almost the same except for the difference of a 5-base. Therefore, it is safe to conclude that MD77 is *A. lwoffii*. A Bayesian phylogenetic tree of the 16s rDNA gene sequences was generated as shown in Fig. 2. In this tree different hosts of *Acinetobacter* are resolved as expected to determine the origin of bacteria in the infected farm. This phylogenetic topology strongly suggested a monophyletic origin of MD77 isolates from rainbow trout farms with Iranian isolates of *A.lwoffii* which were detected from hemodialysis water (GenBank accession no.KR856323.1).

Bacteria from the genus *Acinetobacter* are usually recognized as

normal saprophytic microorganisms. However, the role of *A. baumannii* for channel catfish, and snakehead as the fish pathogen has been well documented in the last years (Xia *et al.*, 2008; Rauta *et al.*, 2011; Kozińska *et al.*, 2014). In another study *A. lwoffii* was isolated from the altered skin and gills of sharptooth catfish, *Clarias gariepinus*, living in the Nile River in Egypt (El-Sayyad *et al.*, 2010). Also, various *Acinetobacter sp.* were isolated from diseased fish cultured in Poland including *A. johnsonii* from rainbow trout and *A. lwoffii* from common carp. Therefore, *Acinetobacter sp.* was regarded as the emerging opportunistic bacteria for aquaculture in various species in different parts of the world. This may be associated with environmental conditions.

In this study, tentative identification of particular isolates as *A. lwoffii* was confirmed by sequencing of the 16S rDNA gene fragment. Also, Kozińska *et al.* (2014) identified *A. lwoffii* from common carp by biochemical and molecular tests. In the present study, the pure culture of *A. lwoffii* was confirmed not only by biochemical tests but also by sequencing the bacterial 16S rDNA gene. The 16S rDNA sequence of isolate MD77 showed a high homology with that sequence of *A. lwoffii* strain WD238 which separated from hemodialysis water in Iran (GenBank accession no.KR856323.1). The pathogenicity of *A. lwoffii* (strain MD77) was confirmed by Infectivity study of rainbow trout. Infected fish

showed high mortality (30%), by which we proposed *A. lwoffii* as a virulent pathogen and new threat for the culture of rainbow trout in high temperatures. External and internal characteristics of disease were similar to those observed in naturally infected fish. It is interesting that some of these signs, especially exophthalmia and hemorrhages or ulceration on the body surface were similar to those described in fish infected with *A. baumannii* (Xia *et al.*, 2008; Rauta *et al.*, 2011) and *A. lwoffii* (Koziańska *et al.*, 2014).

The histopathological results obtained in this study suggested that the pathological findings observed in several organs of challenged fish such as liver and kidney are in agreement with the study by Xia *et al.* (2008). They concluded that most pathological findings that could be used to identify channel catfish and snakehead infected with *A. baumannii* and *A. lwoffii* were vacuolar degeneration in the liver. However, no visible histopathological changes were observed in the gills, kidney, and spleen. Gu *et al.* (1996) reported the vascular changes in the liver, kidney and gills, including hyperemia and hemorrhages in *Siniperca chuatsi* experimentally infected with the bacterium, *A. baumannii* (Gu *et al.*, 1996).

Our results demonstrated that various *Acinetobacter* sp. have probably some common virulence factors. This point was confirmed in previous studies by other researchers who isolated *Acinetobacter* sp. from fish. It should be noted that significant numbers of *A.*

*lwoffii* were also recovered from human specimens often associated with bacteraemia and gastritis (Zavros *et al.*, 2002). This fact emphasizes that fish may transmit this pathogen to humans (Bergogne-Berezin and Towner, 1996). The results of the drug resistance of the strains and frequent concerns about persistence of aquatic bacterial infection caused by the selection of multiresistant *A. lwoffii* have been described worldwide (Levin, 2002; Zhang *et al.*, 2009; Naviner *et al.*, 2011). *A. lwoffii* are resistant to a wide range of antibiotics, including broad-spectrum  $\beta$ -lactams, carbapenems, aminoglycosides, and fluoroquinolones (Guardabassi *et al.*, 2000; Ahmadi *et al.*, 2009). MCT tests of five antibiotic agents also demonstrated the multiresistance of *A. lwoffii* to them. It is therefore advisable that instead of using antibiotics to cure the disease caused by *A. lwoffii*, fish farmers should establish a good preventive management to improve immune system and prevent *A. lwoffii* infection. *A. lwoffii* has a significant capacity for long-term survival in the environment and can survive in various environments with low nutritious components and show a low sensitivity to adverse physical conditions and chemical compounds (Levin, 2002), thus favoring transmission among farms, either via human reservoirs or via materials (Bergogne-Berezin *et al.*, 1996; Wellington *et al.*, 2013). The presence of *A. lwoffii* in farmed rainbow trout would increase the possibility of coinfection between fish

and human via handling or food. Further research is needed to investigate the virulence of *A. lwoffii* isolated from farmed rainbow trout to mammals and to screen other cultured farms for *Acinetobacter* sp.

### Acknowledgements

The authors sincerely thank the Shahid Chamran University for supporting this research. We would also like to thank the Department of Aquatic Animal Health and Diseases of Iranian Fisheries Research Center for their assistance.

### References

- Ahmadi, H., Boroumand, M.A., Anvari, M.S., Karimi, A. and Moshtaghi, N., 2009.** Left-sided endocarditis associated with multi-drug resistance *Acinetobacter lwoffii*. *Journal of Tehran University Heart Center*, 4, 189-192.
- Austin, B. and Austin, D.A., 2007.** Bacterial fish pathogens-diseases of farmed and wild fish. 4th Edn. Springer Verlag. pp. 188-226.
- Baumann, P., 1968.** Isolation of *Acinetobacter* from soil and water. *Journal of Bacteriology*, 96, 39-42.
- Bergogne-Berezin, E. and Towner, K., 1996.** *Acinetobacter* spp. as nosocomial pathogens: microbiological, clinical, and epidemiological features. *Clinical Microbiology Reviews*, 9, 148-156.
- Berlau, J., Aucken, H., Houang, E. and Pitt, T., 1999.** Isolation of *Acinetobacter* spp including *A. baumannii* from vegetables: implications for hospital-acquired infections. *Journal of Hospital Infection*, 42, 201-204.
- de Berardinis, V., Durot, M., Weissenbach, J. and Salanoubat, M., 2009.** *Acinetobacter baylyi* ADP1 as a model for metabolic system biology. *Current Opinion Microbiology*, 12, 568-576.
- Dijkshoorn, L., Nemec, A. and Seifert, H., 2007.** An increasing threat in hospitals: multidrug-resistant *Acinetobacter baumannii*. *Nature Reviews Microbiology*, 12, 939-951.
- Doughari, H.J., Ndakidemi, P.A., Human, I.S. and Benade, S., 2011.** The ecology, biology and pathogenesis of *Acinetobacter* spp : an overview. *Environmental Microbiology*, 26, 101-112.
- El-Sayyad, H.I., Zaki, V.H., El-Shebly, A.M. and El-Badry, D.A., 2010.** Studies on the effects of bacterial diseases on skin and gill structure of *Clarias gariepinus* in Dakahlia Provincence, Egypt. *Annals of Biological Research*, 15, 1-12.
- Gu, T., Lu, C. and Chen, H., 1996.** *Acinetobacter baumannii* a novel pathogen of acute epidemic in mandarin fish (*Siniperca chuatsi*). *Wei ShengWu Xue Tong Bao*, 24, 104-106.
- Guardabassi, L., Dijkshoorn, L., Collard, J.M., Olsen, J. and Dalsgaard, A., 2000.** Distribution

- and in-vitro transfer of tetracycline resistance determinants in clinical and aquatic *Acinetobacter* strains. *Journal of Medical Microbiology*, 49, 929-936.
- Harnisz, M., Golaś, I. and Pietruk, M., 2011.** Tetracycline-resistant bacteria as indicators of antimicrobial resistance in protected waters -The example of the Drwęca River Nature Reserve (Poland). *Ecological indicators*, 11, 663-668.
- Jones, R.N., Ferraro, M.J., Reller, L.B., Schreckenberger, P.C., Swenson, J.M. and Sader, H.S., 2007.** Multicenter studies of tigecycline disk diffusion susceptibility results for *Acinetobacter* spp. *Journal of Clinical Microbiology*, 45, 227-230.
- Joly-Guillou, M.L., 2005.** Clinical impact and pathogenicity of *Acinetobacter*. *Clinical Microbiology Infection*, 11, 868-873.
- Jung, J. and Park, W., 2015.** *Acinetobacter* species as model microorganisms in environmental microbiology: current state and perspectives. *Applied Microbiology and Biotechnology*, 99, 2533-2548.
- Kostka, J.E., Prakash, O., Overholt, W.A., Green, S.J., Freyer, G., Canion, A., Delgardio, J., Norton, N., Hazen, T.C. and Huettel, M., 2011.** Hydrocarbon-degrading bacteria and the bacterial community response in Gulf of Mexico beach sands impacted by the Deepwater Horizon oil spill. *Applied Environmental Microbiology*, 77, 7962-7974.
- Kozińska, A., Paździor, E., Pękala, A. and Niemczuk, W., 2014.** *Acinetobacter johnsonii* and *Acinetobacter lwoffii*-the emerging fish pathogens. *Bulletin of the Veterinary Institute in Pulawy*, 58, 193-199.
- Levin, A., 2002.** Multiresistant *Acinetobacter* infections: a role for sulbactam combinations in overcoming an emerging worldwide problem. *Clinical Microbiology Infection*, 8, 144-153.
- Maravić, A., Skočibušić, M., Fredotović, Ž., Šamanić, I., Cvjetan, S., Knezović, M. and Puizina, J., 2015.** Urban riverine environment is a source of multidrug-resistant and ESBL-producing clinically important *Acinetobacter* spp. *Environmental Science and Pollution Research*, 3, 12-24.
- Marchesi, J.R., Sato, T., Weightman, A.J., Martin, T.A., Fry, J.C., Hiom, S.J. and Wade, W.G., 1998.** Design and evaluation of useful bacterium-specific PCR primers that amplify genes coding for bacterial 16S rRNA. *Applied Environmental Microbiology*, 64, 795-799.
- Naviner, M., Gordon, L., Giraud, E., Denis, M., Mangion, C., Le, H. and Ganière, J.P., 2011.** Antimicrobial resistance of *Aeromonas* spp. isolated from the

- growth pond to the commercial product in a rainbow trout farm following a flumequine treatment. *Aquaculture*, 315, 236-241.
- Peleg, A.Y., Seifert, H. and Paterson, D.L., 2008.** *Acinetobacter baumannii*: emergence of a successful pathogen. *Clinical Microbiology Reviews*, 21, 538-582.
- Rauta, P., Kumar, K. and Sahoo, P., 2011.** Emerging new multi-drug resistant bacterial pathogen, *Acinetobacter baumannii* associated with snakehead *Channa striatus* eye infection. *Current Sciences*, 13, 101-108.
- Reller, L.B., Weinstein, M., Jorgensen, J.H. and Ferraro, M.J., 2009.** Antimicrobial susceptibility testing: a review of general principles and contemporary practices. *Clinical Infection Diseases*, 49, 1749-1755.
- Sharifpour, I., Khosbavar Rostami, H.A. and Mokarami-Rostam, A., 2014.** Sublethal toxicity of organophosphate, diazinon on some organs of great sturgeon (*Huso huso*). *Iranian Journal of Aquatic Animal Health*, 1, 27-35.
- Standards, N.C.F.C.L., 2006.** Performance standards for antimicrobial disk susceptibility tests: Approved standards. National Committee for Clinical Laboratory Standards. pp.96-98.
- Testing Ecoas., 2014.** Breakpoint tables for interpretation of MICs and zone diameters. Version 3.1 EUCAS.
- Wellington, E.M., Boxall, A.B., Cross, P., Feil, E.J., Gaze, W.H., Hawkey, P.M., Johnson-Rollings, A.S., Jones, D.L., Lee, N.M. and Otten, W., 2013.** The role of the natural environment in the emergence of antibiotic resistance in Gram-negative bacteria. *Lancet Infection Diseases*, 13, 155-165.
- Xia, L., Xiong, D., Gu, Z., Xu, Z., Chen, C., Xie, J. and Xu, P., 2008.** Recovery of *Acinetobacter baumannii* from diseased channel catfish (*Ictalurus punctatus*) in China. *Aquaculture*, 284, 285-288.
- Yonar, M., Karahan, M., Kan, N., Yonar, S., Saglam, N. and Torul, O.A., 2010.** Study of *Acinetobacter* sp. infection in some cultured rainbow trout (*Oncorhynchus mykiss*) in Kahramanmaraş. *Istanbul University Fisheries Faculty*, 4, 287-293.
- Zavros, Y., Rieder, G., Ferguson, A. and Merchant, J., 2002.** Gastritis and hypergastrinemia due to *Acinetobacter lwoffii* in mice. *Infection Immunology*, 70, 2630-2639.
- Zhang, Y., Marrs, C.F., Simon, C. and Xi, C., 2009.** Wastewater treatment contributes to selective increase of antibiotic resistance among *Acinetobacter* spp. *Science of the Total Environment*, 12, 3702-3706.